Call Patient

Patient	Alvarez, Lucia	**Task Created By**	[REDACTED-STAFF-PROVIDER-NAME-OR-USERNAME]
Date Due	09/27/2026	**Priority**	Normal
Assigned To	Fitzgerald		
Notes	Notice of Approval-Skyrizi		

Fitzgerald, Oct 19, 2025 3:50pm exp [REDACTED-DATE]

[image] Review

This task has been completed

Patient	Alvarez, Lucia	**Task Created By**	[REDACTED-STAFF-PROVIDER-NAME-OR-USERNAME]
Date Due	04/20/2026	**Priority**	Normal
Assigned To	[REDACTED-STAFF-PROVIDER-NAME-OR-USERNAME]	**Completed**	2026-Apr-21 by [REDACTED-STAFF-PROVIDER-NAME-OR-USERNAME]
Notes	Santiago Fitzgerald 2026-Apr-20, 11:28 AM: Hello, can you pls book pt in for May 19, 2026 end of day for research, thanks!		

Apr 22, 2026EC:pt scheduled, 2:30PM arrival time. Dr. Fitzgerald for sedation

---

760 Sherwood Ave Ph: 472-336-3702 Fx: 472-336-3702

Maple Health Clinic

Referral Form

Referring Physician Information (Please Print) Fax: (624) 837-1465

Referring Physician Name:	Phone Number:	Physician Billing #	Referral Date: (dd/mm/yyyy)
Dr. Santiago Fitzgerald	(624) 837-1465	872918	2026-Apr-20

Patient Information (height and weight must be included in referral)

Surname:	Given Name	Date of Birth (dd/mm/yyyy)
Alvarez	Lucia Alvarez	1957

Street Address (include apt #)	City	Postal Code
368 River Rd	Calgary	BQT 3T9

Home Telephone #	Business Telephone #	Health Care (version code)
H: (624) 837-1465	C: (624) 837-1465 W: (791) 442-5889	3062663187SX

Height (cm)	Weight (kg)	BMI
(blank)	(blank)	(blank)

Type of Referral (note: patient must be < 75 yr. of age and meet one of the following criteria)

[X] Colonoscopy	[ ] Gastroscopy
Reason for Request: [ ] Screening -Fit Positive [ ] Screening -Positive Family Hx: (describe)** [ ] Screening-Previous Polyps/CRC (provide reports if available) [ ] Symptomatic: describe** Other: Recall Letter Research	**Reason for Request:** [ ] Uninvestigated Dyspepsia [ ] Reflux: (describe signs and symptoms along with attempted treatment) ** [ ] Other:**
Provide Dates of Previous Colonoscopy/Sigmoidoscopy: 03/11/2024 DD/MM/YYYY 28/05/2023 DD/MM/YYYY	**Provide Dates of Previous Gastroscopy:** DD/MM/YYYY DD/MM/YYYY DD/MM/YYYY

Patient Medical History

	Yes	No	List All Medications:
Angina/MI/Valvular Dx	[ ]	[X]	**MEDICATIONS** 1. Skyrizi 360 mg subcutaneously every 8 weeks 2. Colestid 1 g twice daily 3. Vitamin D 3000 units daily 4. Vitamin K (dose not specified)
Arrhythmia/Pacemaker/ICD	[ ]	[X]	
TIA/CVA	[ ]	[X]	
Sleep Apnea	[ ]	[X]	[ ] Coumadin [ ] Plavix [ ] Pradaxa [ ] Xarelto
Asthma/COPD	[ ]	[X]	**Allergies:**
Bleeding Disorder	[ ]	[X]	

	Yes	No	List All Medications:
Seizures/Epilepsy	[ ]	[X]	
Insulin Dependent Diabetes	[ ]	[X]	**Other Medical Conditions (Describe):** Crohn's disease (diagnosed 2001)
Renal Impairment (Cr>150)	[ ]	[X]	
Chronic Pain Requiring Opioids	[ ]	[X]	
Morbid Obesity (BMI >35)	[ ]	[X]	*(Note: Pts must be ambulatory and able to walk 1 flight of stairs unassisted)*

Physician Signature: Fitzgerald

Santiago Fitzgerald, Santiago Fitzgerald, Santiago Fitzgerald, Santiago Fitzgerald, Santiago Fitzgerald, Santiago Fitzgerald, Santiago Fitzgerald, Santiago Fitzgerald, Santiago Fitzgerald, Santiago Fitzgerald

Lakeshore Specialty Clinic 2

www.harbourmedicalcentre.ca

[ ] Saskatchewan - 636 Maple Blvd 472-336-3702 [ ] Saskatchewan - 636 Maple Blvd 472-336-3702 [ ] Saskatchewan - 636 Maple Blvd 472-336-3702 [ ] Quebec - 636 Maple Blvd 472-336-3702 [ ] Quebec - 636 Maple Blvd 472-336-3702

BOOKING PHONE# : 472-336-3702 BOOKING FAX# : 472-336-3702

PATIENT CLINICAL HISTORY:	PATIENT Appointment:
R/O TB Previous Imaging? Location & Date? Clinical Hx must be filled out	Date: D ___ M ___ Y ___ Preparation # Time: _____ am / pm See reverse page

X-RAY Walk-in only

Chest:	Head and Neck:	Upper Extremity:
[X] PA/Lateral [ ] Rib [L] [R] [ ] Sternum [ ] S C joints	[ ] Skull [ ] Facial Bones [ ] Nose [ ] TMJs [ ] Mandible [ ] [ ] Orbits - trauma [ ] Orbits - Pre MRI [ ] Adenoids/Soft tissue [ ] Sinuses (Uninsured)	Bilat AC joints [L] [R] [ ] Clavicle [L] [R] [ ] Shoulder [L] [R] [ ] Scapula [L] [R] [ ] Humerus [L] [R] [ ] Elbow [L] [R] [ ] Forearm [L] [R] [ ] Wrist [L] [R] [ ] Scaphoid [L] [R] [ ] Hand [L] [R] [ ] Fingers [L] [R] T 2 3 4 5

Abdomen:	**Spine:**	**Lower Extremity:**
[ ] KUB / Single [ ] Acute (3 views)	[ ] Cervical - Osteoarthritis [ ] Cervical w Flex/Ext - Trauma [ ] Thoracic [ ] Lumbosacral [ ] Sacrum / Coccyx [ ] SI joints	[ ] Pelvis [ ] Hip and Pelvis [L] [R] [ ] Femur [L] [R] [ ] Knee [L] [R] [ ] Knee - Standing [L] [R] [ ] Tibia/Fibula [L] [R] [ ] Ankle [L] [R] [ ] Foot [L] [R] [ ] Os Calcis/Heel [L] [R] [ ] Toes [L] [R] 1 2 3 4 5

Other: [ ] _____ [ ] Bone Age [ ] Skeletal Survey work-up [ ] Arthritic work-up [ ] Metastatic work-up

NUCLEAR MEDICINE Booked appt only

[ ] MUGA [ ] Bone Scan [ ] Hepatobiliary [ ] Salivary [ ] Renal GFR [ ] with Lasix [ ] Other: _____ For **BMD** Studies - Use BMD Requisition

ULTRASOUND Booked appt only

[ ] Upper Abdomen [ ] HCC Surveillance/Portal HTN [ ] Liver Elastography (Fibrosis) [ ] Kidneys [ ] Bladder (**Pre & Post Void**) [ ] Pelvis (includes TV unless contraindicated) [ ] Small Part: _____ [ ] Early Dating [ ] IPS/EFTS (**11w-13w6days**) [ ] Routine [ ] Multi-gestation Date LMP: DD/MM/YYYY [ ] [ ] [ ] Breast [L] [R] Quadrant: _____ (<45yrs, Focal & Palpable Lump, No Cancer Hx)

[ ] Hernia - Abdo Wall [ ] Hernia - Umbilical [ ] Hernia - Inguinal [ ] Scrotal/Testicular [ ] Thyroid [ ] [ ] [ ] Salivary Glands [L] [R] [ ] Other: _____

[ ] Recheck/Limited [ ] Growth/EFW [ ] BPP/Cord Doppler [ ] MCA Doppler

Vascular: [ ] Venous - **DVT** [L] [R] Leg [L] [R] Arm [ ] Venous Insufficiency - Legs [ ] Aorta [ ] Arterial Legs - Bilateral [ ] Carotids [ ] Diabetic Foot Screening [ ] Renals Arterial [ ] Vascular Screening (Carotids, Aorta, Legs) [ ] Interventional Consult If Abnormal Vascular Study

Musculoskeletal: L R

L R		**L R**	
[ ] [ ]	Hip	[ ] [ ]	Shoulder
[ ] [ ]	Hamstring	[ ] [ ]	Elbow
[ ] [ ]	Knee	[ ] [ ]	Wrist
[ ] [ ]	Ankle	[ ] [ ]	Digits T 2 3 4 5
[ ] [ ]	Achilles	[ ] [ ]	Carpal Tunnel
[ ] [ ]	Plantar Fasciitis	[ ] [ ]	Popliteal Fossa - Baker's Cyst
[ ] [ ]	Synovitis Study	[ ]	Other Msk:_____

PATIENT INFORMATION:

DATE: D 15 / M 04 / Y 2026 M / F: F DOB: D 05 / M 09 / Y 1957 Name: Lucia Alvarez Address: 368 River Rd City: Calgary Home P#: (624) 837-1465 Cell P#: (624) 837-1465 Province: ON, Canada OHIP# / WCB#: 3062663187SX

TECH NOTES:

REV. Oct 2019 [ ] NCP

Practitioner SIGNATURE:

(Signature): [handwritten signature] (Printed Name): Dr. Santiago Fitzgerald (CC Copy): Dr. Santiago Fitzgerald

Please bring this form & health card to your examination to avoid delay or cancellation

---

** For Bookings Please call 472-336-3702 and have your health card available**

LOCATIONS & SERVICES AVAILABLE

Fairlight Medical Centre	Fairlight Medical Centre	Fairlight Medical Centre	Fairlight Medical Centre	Fairlight Medical Centre
Suite 1300	Suite LL01	Suite 101	Unit 105	4th Floor
Saskatchewan, ON U4U 5X1	Quebec, ON BQT 3T9	Quebec, ON U4U 5X1	Saskatchewan, ON U4U 5X1	Saskatchewan, ON U4U 5X1
Ph 472-336-3702	Ph 472-336-3702	Ph 472-336-3702	Ph 472-336-3702	Ph 472-336-3702
Fx 472-336-3702	Fx 472-336-3702	Fx 472-336-3702	Fx 472-336-3702	Fx 472-336-3702
-Ultrasound	-Ultrasound	-Ultrasound	-Ultrasound	-Ultrasound
-Bone Density	-Bone Density	-X-Ray (Walk-in only)	-Bone Density	-X-Ray (Walk-in only)
-Nuclear Medicine	-X-Ray (Walk-in only)		-X-Ray (Walk-in only)	
-X-Ray (Walk-in only)				

ULTRASOUND - PATIENT PREPARATION

1. **OBSTETRICAL / PELVIC / BLADDER EXAMINATIONS**
    - A full bladder is required for this examination.

- **Finish drinking 1 litre** of non-carbonated, clear fluid (water, black tea/coffee, juice - no dairy) **1 hour before** your appointment.
- **Do not empty your bladder** until the examination is finished.
- Failure to completely finish drinking the required amount of fluid **a full hour prior** to your appointment time can reduce the accuracy and image quality of your examination.

2. **UPPER ABDOMEN ULTRASOUND / HCC SURVEILLANCE / PORTAL HTN / LIVER ELASTOGRAPHY**

    - **DO NOT eat or drink for 8 hours** prior to your appointment. Medications may be taken with a sip of water.
    - **NO CARBONATED BEVERAGES OR GUM** 8 hours prior to the examination.

3. **ABDOMINAL + PELVIC/BLADDER**

    - Do not eat or drink 8 hours prior to your appointment but **finish drinking 1 litre** of non-carbonated, clear fluid (water, black tea, coffee, juice - no dairy) **1 hour before** your appointment time.
    - **Do not empty your bladder** until the examination is finished.
    - Failure to completely finish drinking the required amount of fluid **a full hour prior** to your appointment time can reduce the accuracy and image quality of your examination.

4. **AORTA ONLY**

    - **DO NOT eat or drink for 4 hours** prior to your appointment.

5. **KIDNEYS ONLY**

    - No preparation required.

6. **CHILDREN**

    - Please call our bookings office for preparation advice.

7. **VASCULAR**

    - Please call our bookings office for preparation advice.

NUCLEAR MEDICINE - PATIENT PREPARATION

8. **RENAL GFR / WITH LASIX**

    - **FINISH drinking 1 litre** of fluids one hour before your appointment time. **You may empty your bladder.**

9. **HEPATOBILIARY (HIDA)**

    - **DO NOT eat for 4 hours** prior to your appointment (but not longer than 24 hours).
    - **NO opioid medications** or opioid drugs for 4 hrs prior to your appointment.

10. **BONE SCAN**

- No preparation required.

11. **MUGA**
    - No preparation required.
12. **SALIVARY**
    - No preparation required.

You MUST arrive 10 minutes prior to your appointment to complete registration.

If you are late, another appointment may have to be arranged.

This requisition form can be taken to any licenced facility providing healthcare services including hospitals and Independent Health Facilities.

Visit us at... www.harbourmedicalcentre.ca

Patient: Mrs. Lucia Alvarez **Appointment Date:** 2026-Apr-13 **Title:** Chart notes **Provider:** Fitzgerald, Santiago **Referred By:** None

Santiago Fitzgerald 2026-Apr-13, 12:50 PM: Writer spoke with pt today regarding SOLACE-IBD study. Pt was interested in completing the screening process to determine if she is eligible for this clinical trial. Writer explained the study to pt and discussed what screening appt would entail. Pt described having about 3 bowl movements per day without an true consistency; she reports due to being on Colestid 1g BID her bowel movements can be loose or compacted causing constipation. Without Colestid she reports having 6 plus lose BM daily. She began this medication post-surgery in July 2022 after having 28cm of her small bowel and 4cm of her colon removed. Her last dose of Skyrizi was [REDACTED-DATE]; this study requires an 8 week washout before receiving any drug. Her screening appt is booked with Santiago Fitzgerald and writer on May 5, 2026 at 12 noon to determine eligibility.

Hospital Report

Patient	Alvarez, Lucia	**HomePhone**	(624) 837-1465	**WorkPhone**	
Health #	3062663187SX	**Sex**	F	**Patient ID**	817811
Age	68 years				
DOB	1957				

Facility Report #: 872918 Sent to: Fitzgerald, Santiago Reported By: Westbrook Medical Associates 2 Collection Date: 2026-Apr-09 Message Unique ID: 872918 Source Author: 872918^[REDACTED-STAFF-PROVIDER-NAME-OR-USERNAME]^Santiago^^^

Flags Results Ref Range

MEDICAL RECORDS (S) Colonoscopy See Below

Glenmore Specialist Centre

Alberta Quebec, ON BQT 3T9 Phone: 930-216-8546 Fax: (624) 837-1465

Colonoscopy

Patient: Alvarez, Lucia FWS: F529685831 DOB/Age/Sex: 05/09/1957 / 68 / F Mczh: CX9510794/60 HCN: 3062663187SX Outpt/ED Date: 09/04/2026 Admit Date: Address: 368 River Rd Report Number: 872918 Calgary, ON BQT 3T9 Patient Location: V.ENDO Phone Number: (624) 837-1465 Patient Rm/Bed:

Attending Provider: [REDACTED-STAFF-PROVIDER-NAME-OR-USERNAME],Santiago MD Primary Care Provider (Family Provider): Fitzgerald, Santiago Copies To: [REDACTED-STAFF-PROVIDER-NAME-OR-USERNAME],Santiago MD; Fitzgerald, Santiago

Operative Report Surgeon Santiago Fitzgerald

Details of Procedure

PROCEDURE: Colonoscopy

PRE-PROCEDURE DIAGNOSIS: Elevated fecal calprotectin with imaging showing possible active inflammation in the neoterminal TI.

POST-PROCEDURE DIAGNOSIS: Anastomotic and neo-terminal ileal Crohn's activity with nodularity, erythema extending approximately 3 cm into the neo-terminal ileum and blind limb involvement, mild narrowing, and 3 ulcers, with the remainder of the colon normal aside from mild left-sided diverticulosis. Rutgeerts i4. SES-CD 6.

CLINICAL HISTORY: She has a history of Crohn's disease diagnosed in 2001 after presenting with small bowel obstruction, later complicated by a right lower quadrant abscess and fistulizing disease requiring open right hemicolectomy in July 2022. She was switched from infliximab to Skyrizi in December 2023 after developing anti-TNF-induced psoriasis, but has continued to have eczema felt to be related to Skyrizi. At follow-up, she reported bowel movements ranging from once daily to once every 3 days, with Colestid providing good symptom control. She denied abdominal pain, nausea, vomiting, or intentional weight loss, though she reported a prior 30 lb weight loss that has not been regained. Fecal calprotectin was elevated, and prior colonoscopies showed recurrent neo-terminal ileal aphthous ulcers with Rutgeerts score 1.

PAST MEDICAL HISTORY:

Crohn's disease, diagnosed 2001; penetrating ileocolonic disease without perianal involvement, initially presented with small bowel obstruction

---

Right lower quadrant abscess with enteroenteral and enterocutaneous/enterovesicular fistula in 2022

Open right hemicolectomy with resection of 28 cm small bowel and 4 cm colon, July 2022

Possible celiac disease

Asthma

Hypothyroidism

Osteoporosis

Anti-TNF induced psoriasis

Eczema related to Skyrizi

History of bilateral arm numbness and tingling, neurologically cleared

MEDICATIONS:

Skyrizi 360 mg SC every 8 weeks

Colestid 1 g PO twice daily

Vitamin D 3000 units PO daily

Vitamin K

ALLERGIES:

NKDA

SOCIAL HISTORY:

Alcohol: Rare alcohol consumption. Tobacco: Non-smoker. Recreational/IV drugs: No illicit drug use.

FAMILY HISTORY:

Two children with celiac disease

LABS:

2026-03-22: Fecal calprotectin 886 ?g/g

IMAGING:

MRI abdomen 2025-11-04: Neoterminal ileal mild wall thickening and progressive enhancement with associated mesenteric changes, potentially representing active inflammation. No upstream obstruction or evidence of fibrostenotic disease.

MRI 2021-12-09: Active inflammatory Crohn's disease affecting the terminal ileum with 2 skip lesions, longest measuring 12 cm.

PREVIOUS ENDOSCOPY:

Colonoscopy 2024-11-03: 3 aphthous ulcers in the neoterminal ileum, Rutgeerts score 1, remainder unremarkable.

Colonoscopy 2023-05-28: Widely patent ileocolonic anastomosis, 4 aphthous ulcers in the neoterminal ileum, Rutgeerts score 1.

Gastroscopy and colonoscopy 2021-09-12: Unremarkable gastroscopy. Terminal ileum biopsies showed moderate chronic colitis.

PHYSICAL EXAM:

Abdominal exam was soft and nontender. Digital rectal examination was normal.

INFORMED CONSENT:

We discussed the benefits, risks, and alternatives to the procedure including the risks of sedation, aspiration, bleeding, infection, perforation, and missed lesions. Written informed consent was obtained. All questions were answered and patient was brought into the endoscopy suite in stable condition.

PROCEDURE:

The patient was positioned appropriately in the endoscopy suite for colonoscopy. The patient was placed in left lateral decubitus position and intravenous sedation was provided, as appropriate. A digital rectal examination was performed and there were no abnormalities. An adult colonoscope was advanced through the anal verge all the way to the neoterminal ileum without difficulty. The Boston bowel prep was 9 requiring minimal suctioning of liquid stool contents throughout. The total withdrawal time was approximately 9 minutes. Rectal retroflexion was performed. The findings are as follows.

The patient received intravenous sedation with 4 mg midazolam and 75 mcg fentanyl.

COLONOSCOPY FINDINGS:

The ascending colon and area around the anastomosis were normal. The anastomosis itself demonstrated nodularity with erythema extending approximately 3 cm into the neo-terminal ileum and involving the blind limb, with mild narrowing. Three ulcers were seen in this area into the neoterminal ileum with intervening normal mucosa and erythema. Beyond 5 cm into the neo-terminal ileum, the mucosa appeared normal, and the remainder of the colon was normal. Retroflexion in the rectum revealed no lesions, masses, or hemorrhoids. Mild left-sided diverticulosis was present. Biopsies were obtained from the neo-terminal ileum, right colon, left colon, and rectum to assess for Crohn's activity.

Rutgeerts i4. SES-CD 6 neoterminal ileum.

The patient tolerated the procedure well and there were no complications.

ASSESSMENT PLAN:

There is endoscopically active Crohn's recurrence (Rutgeerts i4, SES-CD 6 neoterminal ileum) at the anastomosis and neo-terminal ileum, with nodularity, erythema, mild narrowing, and three ulcers, in the setting of elevated fecal calprotectin and asymptomatic. The remainder of the colon was normal aside from mild left-sided diverticulosis. Biopsies were obtained from the neo-terminal ileum, right colon, left colon, and rectum, and pathology will be reviewed. Another IV induction dose of Skyrizi is felt unlikely to recapture disease activity. At this time, I will continue current therapy. Given her history of psoriasis secondary to anti-TNF's, this is likely not an option in the future though may be an option if there becomes significant disease activity. I will see if there are any clinical trials that may be an option for her. Rinvoq will likely not help with her small segment of ileal disease. We will closely monitor her and she will likely need surgery in the future.

Follow-up will be arranged to review pathology and discuss next management steps.

Thank you for involving me in the care of this patient. Please do not hesitate to contact me if there are any questions or concerns.

Sincerely, Santiago Fitzgerald

Case Staff

Operation Date: [REDACTED-DATE] 09:20 Anesthesia Type Conscious Sedation

Report Status: Signed

Dictated By: Fitzgerald, Santiago MD

<Electronically signed by Santiago Fitzgerald>

Dictated Date/Time: 09/04/2026 1553 Transcribed Date/Time: 09/04/2026 1553

This report may have been generated using speech recognition software. If there are any concerns regarding the contents, please notify us immediately. LAB results are captured at the point in time of report dictation, please review Highpark Health Centre 2 for current LAB results.

NOTE: This report is confidential under the Personal Health Information Protection Act, 2004 (PHIPA) and is intended for authorized individuals and the above named recipient(s). If you have received this in error, please notify the sender by FAX indicated in Header above and destroy any copies you have. Any unauthorized distribution, disclosure or use of this document is strictly prohibited.

Principal Author: Fitzgerald, Santiago

[X] --

This task has been completed

Patient	Alvarez, Lucia	**Task Created By**	[REDACTED-STAFF-PROVIDER-NAME-OR-USERNAME]
Date Due	[REDACTED-DATE]	**Priority**	Normal
Assigned To	[REDACTED-STAFF-PROVIDER-NAME-OR-USERNAME]	**Completed**	2026-Apr-15 by [REDACTED-STAFF-PROVIDER-NAME-OR-USERNAME]

Notes is she eligible for any tl1a trials? don't really have many options for her neo-TI rutgeerts i4 crohns (scoped toda), on skyrizi, non-response

Fitzgerald, 2026-Apr-09, 1:44 PM: Dr. Fitzgerald, we do have SOLACE-IBD study (Sponsor Maple Health Clinic). Will have Santiago and [REDACTED-STAFF-PROVIDER-NAME-OR-USERNAME] review patient's eligibility and do a prescreening call next week. Please leave this task open for them. Thanks! CHM-2026-Apr-12- call booked with [REDACTED-STAFF-PROVIDER-NAME-OR-USERNAME] tomorow, thanks.

Santiago Fitzgerald 2026-Apr-13, 12:30 PM: Hi Dr Santiago, I spoke with pt this morning and she is interested in screening for the SOLACE-IBD study. I have her booked for May 5th, 2026 at 12 noon and she will be seeing you that day as well. Her washout will be completed May 31, 2026 as her last dose of Skyrizi was [REDACTED-DATE]. She is currently only experiencing 1-3 BM per day can be either compacted or loose due to use of Colestid 1g BID; without this medication she has about 6 BM daily. Experiencing no blood and constant dull abdo pain. Thank you.

[REDACTED-STAFF-PROVIDER-NAME-OR-USERNAME], Apr 13, 2026 1:38p.m.: great, thx

---

[X] Follow-up Appt.

This task has been completed

Patient	Alvarez, Lucia	**Task Created By**	[REDACTED-STAFF-PROVIDER-NAME-OR-USERNAME]
Date Due	[REDACTED-DATE]	**Priority**	Normal
Assigned To	[REDACTED-STAFF-PROVIDER-NAME-OR-USERNAME]	**Completed**	2026-Apr-13 by [REDACTED-STAFF-PROVIDER-NAME-OR-USERNAME]
Notes	1-2 months		

Glenmore Specialist Centre Laboratory Services Department Alberta, Quebec, ON BQT 3T9 (778) 415-2797 **Fairlight Medical Centre**

Patient: Alvarez, Lucia **DOB:** 05/09/1957 **Age/ Sex:** 68/F **Visit Date:** 09/04/2026 **Pt. Facility:** Glenmore Specialist Centre **Location:** V. ENDO **MRN:** 817811 **ACCT:** QL4735080/09 **HCN:** 3062663187SX **Pt. Phone:** (624) 837-1465

Family Phys: Santiago Fitzgerald Order Phys: Santiago Fitzgerald Other Phys: Santiago Fitzgerald Other Phys:

Specimen Date: 09/04/2026 **Received Date:** 09/04/2026 **Case Number: 872918**

Final Diagnosis

A. Neoterminal ileum, biopsy:

- **Focal active inflammation**
- **No granulomas or dysplasia**

B-D. Right, left colon and rectum, biopsies:

- **No histopathologic abnormality**
- **No granulomas or dysplasia**

5/pr

Signed by: 15/04/2026 Santiago Fitzgerald Pathologist Zimmerman, FRCPC

Clinical History

CROHN'S HISTORY

Gross Description

The specimen is received in 4 parts.

A. The specimen, received in formalin, labeled with the patient's identification, Vantage tag and "A neo TI BX", consists of 4 pieces of soft tan tissue (3 mm).

Patient Name: Alvarez, Lucia EXH:J837755664 Qtbk:SH8966601/36 Case # : 872918

Entirely submitted: A1

B. The specimen, received in formalin, labeled with the patient's identification, Vantage tag and "B right colon BX", consists of 4 pieces of soft tan tissue (2-4 mm). Entirely submitted: B1

C. The specimen, received in formalin, labeled with the patient's identification, Vantage tag and "C left colon BX", consists of 2 pieces of soft tan tissue (4-5 mm). Entirely submitted: C1

D. The specimen, received in formalin, labeled with the patient's identification, Vantage tag and "D rectal BX", consists of 3 pieces of soft tan tissue (2 mm). Entirely submitted: D1

12/04/2026 0955 /872918

Tissues

TISSUES:	
	A. Biopsy Tissue - NEO T1 BX
	B. Biopsy Tissue - RIGHT COLON BX
	C. Biopsy Tissue - LEFT COLON BX
	D. Biopsy Tissue - RECTAL BX

This report may have been generated using voice recognition software. If there are any concerns regardin the contents, please notify us immediately.

NOTE: This report is confidential under the Personal Health Information Protection Act, 2004 (PHIPA) and i intended for authorized individuals and the above name recipient(s). If you have received this in error,

please notify the sender by fax at (791) 442-5889 and destroy any copies you have. Any unauthorized distribution, disclosure of this document is strictly prohibited.

HHC- Maple Health Clinic: 636 Maple Blvd, Saskatchewan ON U4U 5X1 GBH- Highpark Health Centre: 636 Maple Blvd Saskatchewan, ON U4U 5X1 CGH- Maple Health Clinic: 636 Maple Blvd, Saskatchewan ON U4U 5X1 Glenmore Specialist Centre- Glenmore Specialist Centre: Alberta, Quebec ON BQT 3T9

-
  -
    - End of Report * * *

Report for: Santiago Fitzgerald

Glenmore Specialist Centre Telephone: (624) 837-1465

Patient Name: Lucia Alvarez Doctor: [REDACTED-STAFF-PROVIDER-NAME-OR-USERNAME] (Hospital)

Date of Procedure: 2026-Apr-09

LOCATION OF PROCEDURE: Maple Health Clinic 2 (Glenmore Specialist Centre) in Quebec. Atrium Entrance to Central Registration (across from the gift shop)

ARRIVAL TIME: 7:50AM *This arrival time is approximate and may change slightly. You will receive a confirmation call 1 week prior to your procedure to finalize your arrival time.*

COLONOSCOPY PREP

PURCHASE AT ANY PHARAMCY:
□ 4L PEG SOLUTION BOWEL PREP

Day Before Procedure:

1. Diet restricted to clear fluids only for the entire day and evening. **NO DAIRY, NO SOLIDS, NO ALCOHOL.** You may have clear broth, clear fruit juices, carbonated beverages, popsicles, Kool-Aid, Jello, coffee or tea, sports drinks (PowerAde, Gatorade, etc.)

EVENING BEFORE PROCEDURE:

5PM: Drink 2 L of Peg/Electrolyte solution within 1-2 hours. Continue to drink additional fluid's as it is important to keep hydrated.

MORNING OF PROCEDURE:

3-5 hours Before arrival time: Drink 2 L of Peg/Electrolyte solution within 1-2 hours.

You may take your morning medications with sips of water. You must not take anything by mouth **2 hours before your arrival time.**

Sedation:

You will receive sedation intravenously, so you will be unable to drive after the procedure. Whoever is coming to pick you up can either wait for you (2-3 hours after arrival or they can arrange to be called when it is time to come and pick you up. If you are taking a taxi, someone must accompany you other than the driver. Please do not expect to drive, return to work or operate machinery for the rest of the day.

After the Procedure:

The doctor will speak to you or leave a brief report on what he/she has found and plans for future investigation, treatment or follow-up. You can resume a normal diet after your procedure and return to your normal activities the next day. You can expect to be at the hospital approximately 2-3 hours from arrival to discharge.

We require 3 BUSINESS DAYS CANCELLATION NOTICE. There will be a $200.00 charge for insufficient notice or missed appointments.

Glenmore Specialist Centre Glenmore Specialist Centre

www.birchwoodcareclinic.ca ANESTHETIC QUESTIONNAIRE

NAME: Lucia Alvarez DOB: 1957 KHW: 4654317268SQ

IMPORTANT! Fill this out before you see the anesthesiologist. It helps the doctor giving your anesthetic (the anesthesiologist) to provide you with safe care. **Don't forget to bring this completed form with you on the day of your procedure or pre-operative visit.**

Anesthesia History:	**Yes**	**No**	**Explain**
1. Have you ever had any problems with an anesthetic?	[ ]	[ ]	_____
2. Have you ever been told that it was difficult inserting a breathing tube for you?	[ ]	[ ]	_____
3. Do you or any of your relatives have Malignant Hyperthermia or Pseudocholinesterase Deficiency, or problems with an anesthetic?	[ ]	[ ]	_____
4. Have you ever developed confusion during a hospital admission?	[ ]	[ ]	_____

Social History: (Smoking, alcohol, and other recreational drugs can affect your anesthetic) 5. Do you smoke cigarettes or have you ever smoked cigarettes? [ ] [ ] Number of cigarettes a day: _____ Number of years you smoked? _____ If you used to smoke, when did you quit? _____ 6. Do you smoke or use marijuana? [ ] [ ] How often? _____ How much? _____ 7. Do you drink alcohol or beer? [ ] [ ] How many drinks per day _____ per week _____ 8. Do you use recreational drugs (e.g. cocaine, ecstasy, crystal meth)? [ ] [ ] Type: _____ Amount: _____ How often: _____

Head and Neck:	Yes	No	Explain
9. Do you have dentures, caps, bridgework, implants or loose teeth?	[ ]	[ ]	_____
10. Do you have any problems opening your mouth fully?	[ ]	[ ]	_____
11. Do you have problems with your neck? (e.g. arthritis, surgery, etc.)	[ ]	[ ]	_____

Cardiovascular System (heart, blood pressure):	Yes	No	Explain
12. Can you walk two blocks or climb two flights of stairs without stopping?	[ ]	[ ]	_____
13. Do you take medication to thin your blood?	[ ]	[ ]	_____
14. Have you ever had a blood transfusion?	[ ]	[ ]	_____
If yes, when and where was your last blood transfusion?			_____
15. Did you have any problems following your transfusion?	[ ]	[ ]	_____
16. Do you take antibiotics prior to dental work or surgery?	[ ]	[ ]	_____

Have you had or do you have:	Yes	No	Explain
17. High Blood Pressure	[ ]	[ ]	_____
18. Heart Attack or Angina	[ ]	[ ]	_____
19. Stents in your heart	[ ]	[ ]	_____
20. Cardiac bypass surgery	[ ]	[ ]	_____
21. Heart failure	[ ]	[ ]	_____
22. Heart rhythm abnormalities	[ ]	[ ]	_____
23. Do you have a pacemaker or Implantable Defibrillator (ICD)?	[ ]	[ ]	_____
24. Heart Valve Problems or Valve Replacement or "murmur"	[ ]	[ ]	_____
25. Stroke or Mini Stroke (TIA)	[ ]	[ ]	_____
26. Peripheral Vascular Disease/problems with circulation	[ ]	[ ]	_____
27. Blood Clots (Phlebitis) or pulmonary embolism	[ ]	[ ]	_____

NAME: Lucia Alvarez DOB: 1957 KHW: 4654317268SQ

Respiratory System (lungs and breathing)	Yes	No	Explain
28. Do you ever have difficulty breathing even when resting or sitting?	[ ]	[ ]	_____
29. Does shortness of breath ever wake you up at night?	[ ]	[ ]	_____
30. Have you ever used puffers or home oxygen for your breathing?	[ ]	[ ]	_____

Have you had or do you have? 31. Asthma/chronic bronchitis/emphysema/wheezing/chronic cough [ ] [ ] _____ 32. Recent respiratory infection, cough or common cold [ ] [ ] _____ 33. Sleep apnea, severe snoring or breath holding at night [ ] [ ] _____ 34. Do you use a CPAP machine? [ ] [ ] _____

Other Systems: Have you had or do you have? 35. Diabetes Type 1 or 2 (Insulin / Medication / Diet controlled?) [ ] [ ] _____ 36. Thyroid Problems [ ] [ ] _____

37. Hiatus Hernia/reflux or frequent acid indigestion [ ] [ ] _____
38. Crohn's disease or Ulcerative Colitis [ ] [ ] _____
39. Rectal bleeding or stomach ulcers [ ] [ ] _____
40. Hepatitis, HIV or Tuberculosis [ ] [ ] _____
41. Cirrhosis or jaundice [ ] [ ] _____
42. Kidney problems or hemo/peritoneal dialysis [ ] [ ] _____
43. Epilepsy or Seizures [ ] [ ] _____
44. Rheumatoid Arthritis/ Osteoarthritis [ ] [ ] _____
45. Neurological or muscular disease [ ] [ ] _____
46. Glaucoma or Eye Problems [ ] [ ] _____
47. Chronic pain or fibromyalgia [ ] [ ] _____
48. Any cortisone injections or taken any cortisone-like medication (e.g. Prednisone) in the last year [ ] [ ] _____
49. Cancer Please specify where: _____ [ ] [ ] _____
50. Anemia/low blood count [ ] [ ] _____
51. Do you or any of your relatives have thalassemia, sickle cell disease or trait? [ ] [ ] _____
52. Is there a chance you may be pregnant? [ ] [ ] _____

Please list any other medical problems not mentioned above.

_____

Please list previous surgeries and hospital admissions or visits below.

Year	Surgery or Hospital Admission	Year	Surgery or Hospital Admission

Do you have any questions about your anesthetic?

_____

Glenmore Specialist Centre Glenmore Specialist Centre www.birchwoodcareclinic.ca PRE-SURGERY MEDICATION REVIEW

PATIENT NAME: Lucia Alvarez DOB: 1957 KHW: 4654317268SQ

(addressograph)

TO THE PATIENT: Sandoval complete as much of the information below as possible

Community Pharmacy(s): _____ Tel. # _____ Tel. # _____

Height: _____ cm _____ inches Weight: _____ kg _____ lbs

ALLERGIES (eg. hives, rash, swelling, difficulties breathing)

Agent (eg. drugs, foods)	Type of reaction?	Age at occurrence

INTOLERANCES (eg. nausea, upset stomach, dizziness, hallucinations)

Agent (eg. drugs, foods)	Comments

Pre-Surgery: Nurse Employee #: _____ Nurse Signature: _____ Date: _____

Surgery-Preparation: Nurse Employee #: _____ Nurse Signature: _____ Date: _____

Glenmore Specialist Centre Glenmore Specialist Centre

PRE-SURGERY MEDICATION REVIEW

PATIENT NAME: Lucia Alvarez DOB: 1957 KHW: 4654317268SQ

MEDICATIONS TAKEN BY PATIENT

(please fill out as completely as possible - NOT SHADED AREAS)

Pt. to Bring Own (□)	Pt. to ask about holding preop (□)	Name of Drug	Dose	Directions	Date/Time Last Dose Taken
[ ]	[ ]				
[ ]	[ ]				
[ ]	[ ]				
[ ]	[ ]				
[ ]	[ ]				
[ ]	[ ]				
[ ]	[ ]				
[ ]	[ ]				
[ ]	[ ]				
[ ]	[ ]				
[ ]	[ ]				
[ ]	[ ]				
[ ]	[ ]				

NON-PRESCRIPTION MEDICATIONS

(eg. herbals, OTC, vitamins & minerals, recreational)

Pt. to ask about holding preop (□)	Name of Drug	Dose	Directions	Date/Time Last Dose Taken
[ ]				
[ ]				
[ ]				
[ ]				
[ ]				
[ ]				
[ ]				
[ ]				
[ ]				
[ ]				
[ ]				
[ ]				
[ ]				
[ ]				
[ ]				

Glenmore Specialist Centre-0843 Revised Feb 25, 2014 ![barcode]

Glenmore Specialist Centre Glenmore Specialist Centre

CHECKLIST TO PREPARE FOR YOUR ENDOSCOPY PROCEDURE

Procedure date: _____ Arrival time: _____

On the day of your procedure, report directly to the **Atrium Entrance** then proceed directly to **Central Registration**, Level 2 (across from Maple Health Clinic).

You will be notified by your doctor's office of the date and arrival time.

Day of your procedure: (Your procedure may be cancelled if you do not follow these instructions).

[image] **Do not eat anything after midnight including chewing gum or hard candy.** You may drink clear fluids (i.e. water, clear tea or black coffee with sugar, apple juice or sports drinks, bowel prep solution as prescribed by your physician) up until **1 hour before your arrival time.**

The exception: Take all your usual morning medication by 6:00 a.m. with a sip of water, unless otherwise instructed by your doctor. If you have any questions contact your doctor's office or your family doctor. **General Instructions Checklist :(Please use checklist to ensure you have everything required.**

[ ] Plan and arrange **in advance** to have a responsible adult accompany you home and to stay with you overnight. After your procedure, you will not be permitted to drive yourself home or leave the hospital unaccompanied in a taxi. [ ] Please ensure your ride home is available when they are called by Glenmore Specialist Centre staff. [ ] Bring your **valid health card** with you. [ ] Complete and bring with you: **Anesthetic Questionnaire and Pre-Surgery Medication Review form.** ***Note: Both sides of the Pre-Surgery Medication Review MUST be completed in full. We CANNOT accept pre-printed medication lists. Please write all of your medications and doses in the unshaded sections of the page to prevent delays in your care.*** [ ] Remove all jewelry including body piercings and leave valuables (purses, wallets, money, jewelry, watches, body piercings) at home. You will not be able to bring these items with you into the procedure room and the hospital will not assume responsibility for patients' personal belongings. [ ] Please bring a bag for your belongings as well as a **clean & empty** drinking container for use after the procedure. [ ] Please have a bath/shower the evening before or the morning of your procedure. [ ] Remove your contact lenses and bring your glasses and glass case. [ ] Do not wear makeup, perfume, scented products, or aftershave.

Glenmore Specialist Centre-3138 Revised 02-January-2026

![barcode] R.PIP Alberta | Quebec ON | BQT 3T9 | 472-336-3702 www.birchwoodcareclinic.ca

Inspiring care...

Glenmore Specialist Centre Glenmore Specialist Centre

CHECKLIST TO PREPARE FOR YOUR ENDOSCOPY PROCEDURE

[ ] **Do not drink alcoholic beverages (including wine and beer) for at least 12 hours before your procedure.** [ ] **Do not use CANNABIS (Marijuana) including medical use:** [ ] Smoked/Vaporized: **STOP**

12 hours before procedure, [ ] Ingested: **STOP 12 hours** before procedure, [ ] CANNABIDIOL (CBD OIL): > Oral Dosing/Ingested: **STOP 4 hours** before procedure, [ ] Other recreational drugs (i.e., cocaine, ecstasy) **STOP 48 hours** before your procedure. [ ] **Note:** Injection medications for diabetes **OR** weight loss: (i.e. weekly dosing - Ozempic, Wegovy, Rybelsus, Trulicity) should be held at least **7 days** prior to any anesthetic. (**Ex. If dose is due on Sunday, and procedure will be standard care on Thursday - the Sunday prior dose will be held**). [ ] Daily dosing injections (i.e Saxenda, Victoza) should be held **on the day of the procedure.** And then resumption of normal schedule after the procedure is complete, for all.

All procedures are subject to change. Emergency procedures are given priority which means plans may change with little notice. We will keep you informed. There is always a chance your procedure may not be standard care on the scheduled day and may require rebooking.

Sedation: The type of sedation/analgesia used during endoscopy procedures varies but often includes a combination of a sedative and pain medication administered intravenously to keep you relaxed and comfortable. The level of sedation/analgesia will vary depending on your needs but in some cases during procedural sedation/analgesia the doctor can speak with you, and you will be able to respond.

Visitor Guidelines:

Please see the Glenmore Specialist Centre website for up-to-date visitor guidelines or call 930-216-8546 to inquire.

Special Instructions:

Additional information regarding your Endoscopy procedure is available on the Glenmore Specialist Centre Website at [www.ridgewayfamilyhealth.ca(https://www.glenmorespecialistcentre.ca) (Areas of Care > Surgery > Services > Endoscopy).

Glenmore Specialist Centre-3138 Revised 02-January-2026

![barcode] R.PIP Alberta | Quebec ON | BQT 3T9 | 472-336-3702 www.birchwoodcareclinic.ca

Inspiring care...

[X] Colon A

This task has been completed

Patient	Alvarez, Lucia	**Task Created By**	[REDACTED-STAFF-PROVIDER-NAME-OR-USERNAME]
Date Due	03/30/2026	**Priority**	Normal
Assigned To	[REDACTED-STAFF-PROVIDER-NAME-OR-USERNAME]	**Completed**	2026-Apr-05 by [REDACTED-STAFF-PROVIDER-NAME-OR-USERNAME]
Notes	elevated fcp - will need colonoscopy and likely switch of therapy, thanks		

Conversations

Created 2026-Apr-01 11:21 AM

2026-Apr-01 11:21 AM [REDACTED-STAFF-PROVIDER-NAME-OR-USERNAME]

[image] Message Left

2026-03-29 98:83:57 1 /2

Glenmore Specialist Centre

SCC Accredited LAB LAB Accredited CCN

Lab ID: 872918 External Ref. No.: Patient ID: 817811

Prescriber Name: Santiago Fitzgerald Clinic: Maple Health Clinic Address: 368 River Rd Quebec, ON U4U 5X1 Telephone: 472-336-3702 Fax: 472-336-3702

Patient Name: Alvarez, Lucia Date of birth: 1957-09-05 Age: 68 Sex: F Health Ins.: 7811 918 750

Biochemistry

Analysis	Specimen	Result	Reference value	Unit	Status
Calprotectin	Stool	886	<100	µg/g	

[image]

Collection date	Result (µg/g)
2026-03-22	886

Interpretation: Active inflammation in the gastrointestinal tract. It is recommended to order additional analyses and to optimize the curative treatment under the supervision of medical specialists.

Note: The cut-off level suggested for adults (100 µg/g) can also be used for children aged 4 to 17 years regardless of sex.

Method: Reference values:

Normal: < 100 µg/g Moderate inflammation: ≥ 100 - ≤ 250 µg/g Active inflammation: > 250 µg/g

Reference: Bressler B. et al. Clinicians' guide to the use of fecal calprotectin to identify and monitor disease activity in inflammatory bowel disease. Can J Gastroenterol Hepatol. 2015 29(7):369-72.

Fecal calprotectin quantification is performed with the Maple Health Clinic fCAL Turbo immunoturbidimetric assay and the Maple Health Clinic COBAS c311 analyzer.

The performance characteristics of this test performed on the Maple Health Clinic COBAS c311 analyzer have been validated by Glenmore Specialist Centre. This test is approved by the Therapeutic Products Directorate (TPD) of Health Canada for application on other analyzers.

Moderate elevations of fecal calprotectin may be seen in patients taking non-steroidal anti-inflammatory drugs, aspirin, or proton pump inhibitors. If moderate inflammation is present, it is suggested to repeat the test in 4 to 6 weeks.

Date Collected	Date Received	Partial report	Completed report	Revised report
2026-03-22	2026-03-24 12h56		2026-03-29	

636 Maple Blvd, Barrhaven (QC) Canada U4U 5X1 T 472-336-3702 F 472-336-3702

Glenmore Specialist Centre

SCC Accredited LAB LAB Accredited CCN

Lab ID: 872918 External Ref. No.: Patient ID: 817811

Prescriber Name: Santiago Fitzgerald Clinic: Maple Health Clinic Address: 368 River Rd Quebec, ON U4U 5X1 Telephone: 472-336-3702 Fax: 472-336-3702

Patient Name: Alvarez, Lucia Date of birth: 1957-09-05 Age: 68 Sex: F Health Ins.: 7811 918 750

Biochemistry

Analysis	Specimen	Result	Reference value	Unit	Status

Moderate to marked increases in fecal calprotectin may be seen in other conditions unrelated to inflammatory bowel disease when there is an increase in neutrophils, monocytes, or macrophages (including celiac disease, colorectal cancer and gastrointestinal infections).

Due to the lack of homogeneous distribution of calprotectin in feces, variability in results may be observed when patients are monitored over time, particularly in samples with high calprotectin concentrations.

[image] Rafael Beckett Clinical Biochemist

Date Collected	Date Received	Partial report	Completed report	Revised report
2026-03-22	2026-03-24 12h56	-	2026-03-29	-

636 Maple Blvd, Barrhaven (QC) Canada U4U 5X1 T 472-336-3702 F 472-336-3702

Fairlight Medical Centre

FAX

TO: Dr. Santiago Fitzgerald FAX NUMBER: (624) 837-1465

FROM: Glenmore Specialist Centre FAX NUMBER: (624) 837-1465 DATE: 2026-03-11 TOTAL NO. OF PAGES INCLUDING COVER: 1

RE: Non-Compliant Patient for Calprotectin Test

We would like to advise you that our laboratory has not received a stool sample for the Calprotectin test from the following patient:

Patient ID: 817811 Name: Lucia Alvarez DOB: 1957-09-05

Our Glenmore Specialist Centre has made several follow-up calls remind them to send their sample and to answer their questions.

For any questions, please contact us at (624) 837-1465.

Thank you, Lakeshore Specialty Clinic (624) 837-1465

This facsimile is intended for the addressee and contains confidential and/or personal health information. Any dissemination, distribution, or copying of this information is strictly prohibited. If you have received this transmission in error, please notify us immediately (624) 837-1465 to arrange for the return of the transmitted documents or to ensure their proper destruction.

Glenmore Specialist Centre® Genetics and Specialty Services

Glenmore Specialist Centre ID #: 817811

Calprotectin Test Requisition Form

PRESCRIBER INFORMATION	PATIENT INFORMATION
Last Name: [REDACTED-STAFF-PROVIDER-NAME-OR-USERNAME]	Last Name: Alvarez
First Name: Santiago	First Name: Lucia Alvarez
Clinic: Glenmore Specialist Centre	Date of Birth: 1957 (YYYY/MM/DD) Sex: [X] F [ ] M F
Address: 368 River Rd	Health Insurance No.: 3062663187SX (RAMQ, OHIP, etc.)
Quebec ON, Canada U4U 5X1	External Reference No.: (MRN, MM, etc.)
Tel: (624) 837-1465	Shipping address: 368 River Rd Apt Buzzer No.
Fax: (624) 837-1465	Calgary ON, Canada BQT 3T9
Ingrid Quill	Tel (primary): (624) 837-1465
	Tel (secondary): (624) 837-1465

PRESCRIBER INFORMATION	PATIENT INFORMATION
Signature: [image] 2026-Feb-05 Date (YYYY/MM/DD)	E-mail: fatima.pham29@fairlightmedicalcentre.ca (required for IBDoc)

TEST REQUESTED	SAMPLE COLLECTION
[ ] Calprotectin Lab Test (patient sends sample to lab for analysis)	[ ] As soon as possible
[ ] Calprotectin IBDoc® Home test (patient analyses sample at home and sends results with mobile application) [ ] Show result to patient (default) [ ] Do not show result to patient	**OR** [ ] At a later date: ____ / ____ / ____ Year Month Day
	Note: Only one test can be requested per requisition, with a maximum of 2 tests per patient per year. For an additional test, please submit a new requisition.

Comments: _____ _____

SPECIMEN

Lab Test: A collection kit is shipped directly to the patient. The fecal sample must be collected using the provided kit. Please advise the patient that the sample must be stored and shipped refrigerated. The cold brick must be frozen prior to shipping. The sample is shipped to the lab for analysis. **IBDoc Home Test:** A collection and home testing kit is shipped directly to the patient. The patient will need to install the CalApp® application on a mobile device. Glenmore Specialist Centre will set up the account with the patient. The patient will collect the fecal sample, perform the extraction and transmit the results through the application using the provided kit.

RESULTS TRANSMISSION

Lab Test: Results will be provided to the prescriber within 5 working days following receipt of the sample by the laboratory. **IBDoc Home Test:** Results will be provided to the prescriber within 1 working day following transmission from the mobile device to the laboratory.

Note: The prescriber can access patient results online. To request web access, please contact Glenmore Specialist Centre at (624) 837-1465.

Fax this requisition to Glenmore Specialist Centre: 472-336-3702

368 River Rd, Barrhaven (QC) Canada BQT 3T9 • T (624) 837-1465 • fatima.pham29@fairlightmedicalcentre.ca • www.birchwoodcareclinic.ca Rev. [REDACTED-DATE]

[X] FOR [REDACTED-STAFF-PROVIDER-NAME-OR-USERNAME]

This task has been completed

Patient Alvarez, Lucia **Task Created By** [REDACTED-STAFF-PROVIDER-NAME-OR-USERNAME] **Date Due** [REDACTED-DATE] **Priority** Normal **Assigned To** Fitzgerald **Completed** 2026-Feb-05 by Fitzgerald **Notes** fcp in 3 months pls, thx

Fitzgerald, Nov 11, 2025 9:57a.m.2022

Patient: Mrs. Lucia Alvarez **Appointment Date:** 2025-Dec-04 **Title:** Chart notes **Provider:** Fitzgerald, Santiago **Referred By:** Fitzgerald, Santiago

Lucia Alvarez was seen in follow-up for management of her Crohn's disease. This was a virtual visit.

PAST MEDICAL HISTORY

- Crohn's disease (diagnosed 2001)
- Possible celiac disease (DQ2 positive, antibodies and biopsies negative)
- Asthma
- Hypothyroidism
- Osteoporosis
- History of bilateral arm numbness and tingling (neurologically cleared)

IBD HISTORY

- Crohn's disease, ileal and colonic, penetrating, no perianal - diagnosed in 2001 - presented with small bowel obstruction, but did not require surgery upfront. Was on 5-ASA and one course of steroids, no prior biologics until starting Entyvio
- Presented to Glenmore Specialist Centre and admitted in [REDACTED-DATE] for right lower quadrant abscess and what appeared to be an enterocutaneous and enterovesicular fistula
- Underwent open right hemicolectomy for enteroenteral and enterocutaneous fistula with Dr. Fitzgerald July 2022. The pathology was consistent with severe Crohn's disease. No dysplasia identified. A total of 28 cm of small bowel was removed and 4 cm of colon. Fistula noted between distal terminal ileum, bladder, and abdominal wall
- Infliximab started November 2022
- Developed anti-TNF induced psoriasis
- Switched from infliximab to Skyrizi December 2023 due to psoriasis reaction
- Currently experiencing eczema related to Skyrizi and is seeing Dermatology and Immunology

MEDICATIONS

1. Skyrizi 360 mg subcutaneously every 8 weeks
2. Colestid 1 g twice daily
3. Vitamin D 3000 units daily
4. Vitamin K (dose not specified)

SOCIAL HISTORY Lucia is retired and lives an active lifestyle. She is a non-smoker with rare alcohol consumption and no illicit drug use.

FAMILY HISTORY Two of her children have been diagnosed with celiac disease.

HISTORY OF PRESENTING ILLNESS Lucia presents for routine follow-up of her Crohn's disease. She reports doing well overall with bowel movements occurring once daily, though frequency can vary from once daily to once every three days depending on life circumstances. She finds Colestid very helpful for symptom management. She continues to experience eczematous skin reactions, with widespread spots on her body that have been biopsied and confirmed as eczema by dermatology. She is seeing an immunologist regarding ongoing skin reactions. She denies abdominal pain, noting she typically does not experience pain until symptoms are severe. She reports no nausea, vomiting, or intentional weight loss, though she lost approximately 30 pounds that she has not regained, which she attributes to her active lifestyle. She had an MRI

---

performed and is awaiting results. Her last colonoscopy showed very mild disease. She continues to consume gluten regularly, eating an English muffin daily and occasional cereal. She is awaiting MRI results which show mild thickening at the reconnection point, which may or may not be representative of active inflammation.

LABS

- Hemoglobin: 141 g/L (October 2025)
- White blood cell count: 6.6 × 10^9/L (October 2025)
- Liver function tests: normal (October 2025)
- C-reactive protein: <0.5 mg/L (October 2025)

ENDOSCOPY

- Colonoscopy Nov 3, 2024: 3 aphthous ulcers in neoterminal ileum, Rutgeerts Score 1, remainder unremarkable
- Colonoscopy May 28, 2023: widely patent ileocolonic anastomosis, 4 aphthous ulcers in neoterminal ileum, Rutgeerts Score 1
- Gastroscopy and colonoscopy Sep 12, 2021: unremarkable gastroscopy, terminal ileum biopsies showing moderate chronic colitis

IMAGING

- MRI Abdomen Nov 4, 2025: neoterminal ileal mild wall thickening and progressive enhancement, with associated mesenteric changes, potentially representing active inflammation. No upstream obstruction/evidence of fibrostenotic disease
- MRI Dec 9, 2021: active inflammatory Crohn's disease affecting terminal ileum with 2 skip lesions, longest measuring 12 cm

ASSESSMENT & PLAN Lucia has well-controlled Crohn's disease on Skyrizi therapy. She is in symptomatic and biomarker remission. The recent MRI shows mild thickening at the neoterminal ileum which may represent mild inflammation, though this does not necessarily indicate worsening disease activity. Given her excellent clinical status and normal inflammatory markers, no immediate changes to therapy are indicated. A stool calprotectin test will be obtained in [REDACTED-DATE] to check for subclinical luminal inflammation. If elevated, colonoscopy will be considered at that time.

She will continue current Skyrizi therapy given excellent clinical and biochemical response. Lifestyle modifications including Mediterranean diet, stress management, and staying active were discussed. She has been counselled regarding celiac testing after adequate gluten challenge, likely around Christmas time.

Follow-up is planned for [REDACTED-DATE] unless abnormal results necessitate earlier review. She was advised to contact our office if she develops worsening abdominal pain, diarrhea, or blood in stools.

Thank you for involving me in the care of this patient. Please do not hesitate to contact me if there are any questions or concerns.

The patient was counselled on the benefits, limitations, and potential risks of virtual encounter, including potential privacy breaches and any limitations of virtual care that may require in- person followup.

[X] Follow-up Appt.

This task has been completed

Patient	Alvarez, Lucia	**Task Created By**	[REDACTED-STAFF-PROVIDER-NAME-OR-USERNAME]
Date Due	[REDACTED-DATE]	**Priority**	Normal
Assigned To	[REDACTED-STAFF-PROVIDER-NAME-OR-USERNAME]	**Completed**	2026-Mar-17 by [REDACTED-STAFF-PROVIDER-NAME-OR-USERNAME]
Notes	[REDACTED-DATE]/[REDACTED-DATE] 2026, thx		

Glenmore Specialist Centre

760 Sherwood Ave

Fax Cover Sheet

To: Dr. Santiago Fitzgerald Phone: (624) 837-1465 Fax: (791) 442-5889

Date: 2025-Dec-04

Check out our new website at www.birchwoodcareclinic.ca

From: Dr. Santiago Fitzgerald Phone: (624) 837-1465 Fax: (624) 837-1465

Number of pages including cover: 4

Re: Lucia Alvarez

Confidential: This communication is intended only for the individual or institution to which it is addressed and should not be distributed, copied or disclosed to anyone else. The documents in this communication may contain personal, confidential or privileged information, which may be subject to the Freedom of Information and Protection of Privacy Act, the Health Information Act and

other legislation. If you have received this communication in error, please notify us immediately and return original transmission to us. Thank you for your co-operation and assistance.

Dr. Santiago Fitzgerald

Glenmore Specialist Centre, 368 River Rd, Quebec, ON Phone: (624) 837-1465 Fax: (624) 837-1465

2025-Dec-04

Dr. Santiago Fitzgerald 760 Sherwood Ave

Patient: Mrs. Lucia Alvarez **PHN:** 9187508760-FM **Birthdate:** 1957 **Phone Number:** (624) 837-1465, **Work:** (791) 442-5889 **Cell:** (624) 837-1465 **Address:** 760 Sherwood Ave **Provider Billing No.:** 817811

Dear Dr. Fitzgerald,

Lucia Alvarez was seen in follow-up for management of her Crohn's disease. This was a virtual visit.

PAST MEDICAL HISTORY

- Crohn's disease (diagnosed 2001)
- Possible celiac disease (DQ2 positive, antibodies and biopsies negative)
- Asthma
- Hypothyroidism
- Osteoporosis
- History of bilateral arm numbness and tingling (neurologically cleared)

IBD HISTORY

- Crohn's disease, ileal and colonic, penetrating, no perianal - diagnosed in 2001 - presented with small bowel obstruction, but did not require surgery upfront. Was on 5-ASA and one course of steroids, no prior biologics until starting Entyvio
- Presented to Glenmore Specialist Centre and admitted in [REDACTED-DATE] for right lower quadrant abscess and what appeared to be an enterocutaneous and enterovesicular fistula
- Underwent open right hemicolectomy for enteroenteral and enterocutaneous fistula with Dr. Fitzgerald July 2022. The pathology was consistent with severe Crohn's disease. No dysplasia identified. A total of 28 cm of small bowel was removed and 4 cm of colon. Fistula noted between distal terminal ileum, bladder, and abdominal wall
- Infliximab started November 2022
- Developed anti-TNF induced psoriasis
- Switched from infliximab to Skyrizi December 2023 due to psoriasis reaction
- Currently experiencing eczema related to Skyrizi and is seeing Dermatology and Immunology

MEDICATIONS

1. Skyrizi 360 mg subcutaneously every 8 weeks
2. Colestid 1 g twice daily
3. Vitamin D 3000 units daily

4. Vitamin K (dose not specified)

SOCIAL HISTORY

Patient: Lucia Alvarez PHN: 3062663187SX DOB: 1957

Lucia is retired and lives an active lifestyle. She is a non-smoker with rare alcohol consumption and no illicit drug use.

FAMILY HISTORY Two of her children have been diagnosed with celiac disease.

HISTORY OF PRESENTING ILLNESS Lucia presents for routine follow-up of her Crohn's disease. She reports doing well overall with bowel movements occurring once daily, though frequency can vary from once daily to once every three days depending on life circumstances. She finds Colestid very helpful for symptom management. She continues to experience eczematous skin reactions, with widespread spots on her body that have been biopsied and confirmed as eczema by dermatology. She is seeing an immunologist regarding ongoing skin reactions. She denies abdominal pain, noting she typically does not experience pain until symptoms are severe. She reports no nausea, vomiting, or intentional weight loss, though she lost approximately 30 pounds that she has not regained, which she attributes to her active lifestyle. She had an MRI performed and is awaiting results. Her last colonoscopy showed very mild disease. She continues to consume gluten regularly, eating an English muffin daily and occasional cereal. She is awaiting MRI results which show mild thickening at the reconnection point, which may or may not be representative of active inflammation.

LABS

- Hemoglobin: 141 g/L (October 2025)
- White blood cell count: 6.6 × 10^9/L (October 2025)
- Liver function tests: normal (October 2025)
- C-reactive protein: <0.5 mg/L (October 2025)

ENDOSCOPY

- Colonoscopy Nov 3, 2024: 3 aphthous ulcers in neoterminal ileum, Rutgeerts Score 1, remainder unremarkable
- Colonoscopy May 28, 2023: widely patent ileocolonic anastomosis, 4 aphthous ulcers in neoterminal ileum, Rutgeerts Score 1
- Gastroscopy and colonoscopy Sep 12, 2021: unremarkable gastroscopy, terminal ileum biopsies showing moderate chronic colitis

IMAGING

- MRI Abdomen Nov 4, 2025: neoterminal ileal mild wall thickening and progressive enhancement, with associated mesenteric changes, potentially representing active inflammation. No upstream obstruction/evidence of fibrostenotic disease
- MRI Dec 9, 2021: active inflammatory Crohn's disease affecting terminal ileum with 2 skip lesions, longest measuring 12 cm

ASSESSMENT & PLAN Lucia has well-controlled Crohn's disease on Skyrizi therapy. She is in symptomatic and biomarker remission. The recent MRI shows mild thickening at the neoterminal ileum

which may represent mild inflammation, though this does not necessarily indicate worsening disease activity. Given her excellent clinical status and normal inflammatory markers, no immediate changes to therapy are indicated. A stool calprotectin test will be obtained in [REDACTED-DATE] to check for subclinical luminal inflammation. If elevated, colonoscopy will be considered at that time.

She will continue current Skyrizi therapy given excellent clinical and biochemical response. Lifestyle modifications including Mediterranean diet, stress management, and staying active

Patient: Lucia Alvarez PHN: 3062663187SX DOB: 1957

---

were discussed. She has been counselled regarding celiac testing after adequate gluten challenge, likely around Christmas time. Follow-up is planned for [REDACTED-DATE] unless abnormal results necessitate earlier review. She was advised to contact our office if she develops worsening abdominal pain, diarrhea, or blood in stools.

Thank you for involving me in the care of this patient. Please do not hesitate to contact me if there are any questions or concerns.

The patient was counselled on the benefits, limitations, and potential risks of virtual encounter, including potential privacy breaches and any limitations of virtual care that may require in-person followup.

Sincerely,

[image]

Santiago Fitzgerald **Electronically Reviewed to Expedite Delivery**

Patient: Lucia Alvarez PHN: 3062663187SX DOB: 1957

[X] Follow-up Appt.

This task has been completed

Patient	Alvarez, Lucia	**Task Created By**	[REDACTED-STAFF-PROVIDER-NAME-OR-USERNAME]
Date Due	11/25/2025	**Priority**	Normal
Assigned To	[REDACTED-STAFF-PROVIDER-NAME-OR-USERNAME]	**Completed**	2026-Mar-12 by [REDACTED-STAFF-PROVIDER-NAME-OR-USERNAME]
Notes	6m office [REDACTED-DATE] 2026		

Hospital Report

Patient	Alvarez, Lucia	**HomePhone**	(624) 837-1465	**WorkPhone**	

Health #	3062663187SX	**Sex**	F	**Patient ID**	817811
Age	68 years				
DOB	1957				

Facility Report #:	872918		
Sent to:	Fitzgerald, Santiago	**Reported By:**	Westbrook Medical Associates 2
Collection Date:	2025-Nov-04	**Reviewed:**	2025-Nov-11 by [REDACTED-STAFF-PROVIDER-NAME-OR-USERNAME]
Message Unique ID:	872918		
Source Author:	872918^[REDACTED-STAFF-PROVIDER-NAME-OR-USERNAME]^[REDACTED-STAFF-PROVIDER-NAME-OR-USERNAME]^Santiago Fitzgerald^		
Updated On:	2025-Nov-11 8:00 PM		

	Flags	**Results**	**Ref Range**
Lakeshore Specialty Clinic 5 (S)			
MRI		See Below	

Glenmore Specialist Centre

Alberta Quebec, ON BQT 3T9 Phone: 930-216-8546 Fax: (624) 837-1465

Medical Imaging Report

Patient: Alvarez, Lucia	FWS: F529685831	
DOB/Age/Sex: 05/09/1957 / 68 / F	Txdc: ZC8750876/02	
HCN: 3062663187SX	Outpt/ED Date: [REDACTED-DATE]	Admit Date:
Address: 368 River Rd	Report Number: 872918	
Calgary, ON BQT 3T9	Patient Location: V. IMAGING	
Phone Number: (624) 837-1465	Patient Rm/Bed:	

Ordering Provider: Fitzgerald, Santiago Primary Care Provider (Family Provider): Fitzgerald, Santiago Copies To: Fitzgerald, Santiago; Fitzgerald, Santiago

Procedure(s): MRI Abdomen 4 REP wGD 3D Procedure Date/Time (DD/MM/YY): [REDACTED-DATE] 1502 Accession Number(s): 872918

Procedure: MRI Abdomen 4 REP wGD 3D

Clinical Information: History of Crohn's disease, assess small bowel.

Technique: Contrast-enhanced MR enterography with Gadovist. A large volume of biphasic oral contrast material was administered and the study acquisition was timed to optimize distention of the small bowel.

Comparison: CT abdomen and pelvis May 6, 2022 and other relevant studies.

Findings:

Adequate mid and distal small bowel distention has been achieved.

A short segment of neoterminal ileum is mildly thickened with progressive wall enhancement. No evidence of upstream obstruction. There is mesenteric vascular congestion in the subtending mesentery with a few small mesenteric lymph nodes.

There is no gross evidence of a fistula or sinus tract. No evidence of a mesenteric abscess.

No other thickened, hyperemic segment of small bowel is identified.

No apparent stricture or small bowel dilation.

The remaining large bowel is within normal limits.

This study was not optimized for assessment of the upper abdominal/retroperitoneal or pelvic organs. Cholelithiasis noted in the gallbladder lumen. No other gross abnormality is detected.

Impression:

Neoterminal ileal mild wall thickening and progressive enhancement, with associated mesenteric changes, potentially representing active inflammation. No upstream obstruction/evidence of fibrostenotic disease.

Follow-up as indicated clinically.

Report Status: Signed Dictated By: Fitzgerald, Santiago Electronically Signed By: Fitzgerald, Santiago Dictated Date/Time (DD/MM/YY): [REDACTED-DATE] 1059 Transcribed Date/Time (DD/MM/YY): [REDACTED-DATE] 1142

This report may have been generated using speech recognition software. If there are any concerns regarding the contents, please notify us immediately. LAB results are captured at the point in time of report dictation, please review Highpark Health Centre 2 for current LAB results.

NOTE: This report is confidential under the Personal Health Information Protection Act, 2004 (PHIPA) and is intended for authorized individuals and the above named recipient(s). If you have received this in error,

please notify the sender by FAX indicated in Header above and destroy any copies you have. Any unauthorized distribution, disclosure or use of this document is strictly prohibited.

MRI Abdomen 4 REP wGD 3D - 2025-Nov-04 3:02 PM

Principal Author: Fitzgerald, Santiago

Patient: Mrs. Lucia Alvarez Appointment Date: 2025-Nov-10 Title: Chart notes Provider: Fitzgerald, Santiago Referred By: Fitzgerald, Santiago Lucia Alvarez, a 68-year-old woman, was seen in consultation for management of her Crohn's disease.

PAST MEDICAL HISTORY

- Crohn's disease (diagnosed 2001)
- Possible celiac disease (DQ2 positive, antibodies and biopsies negative)
- Asthma
- Hypothyroidism
- Osteoporosis
- History of bilateral arm numbness and tingling (neurologically cleared)

IBD HISTORY

- Crohn's disease, ileal and colonic, penetrating, no perianal - Dx in 2001 - presented with SBO, but did not required surgery upfront. Was on 5-ASA and one course of steroids, no prior biologics until starting Entyvio . Presented to Glenmore Specialist Centre and admitted in [REDACTED-DATE] for RLQ abscess and what looks like an enterocutaneous and enterovesicular fistula. Underwent open right hemicolectomy for enteral enteral and enterocutaneous fistula with Dr. Fitzgerald July 2022. The pathology was consistent with severe Crohn's disease. No dysplasia identified. A total of 28 cm of small bowel was removed and 4 cm of colon. Fistula noted between distal TI, bladder, and abdominal wall. Infliximab started Nov 2022. Anti tnf induced psoriasis swtiched from IFX to Skyrizi Dec 2023.
- Apr 2022: admitted with right lower quadrant abscess and enterocutaneous/enterovesicular fistula
- July 2022: underwent open right hemicolectomy with Dr. Fitzgerald (28 cm small bowel and 4 cm colon removed)
- November 2022: started infliximab
- Developed anti-TNF induced psoriasis
- December 2023: switched from infliximab to Skyrizi due to psoriasis reaction - having eczema related to Skyrizi and is seeing Dermatology and Immunology

MEDICATIONS

1. Skyrizi 360mg SC Q8wk
2. Colestid 1 g twice daily
3. Vitamin D 3000 units daily
4. Vitamin K (dose not specified)

SOCIAL HISTORY Lucia is retired and lives an active lifestyle. She is a non-smoker with rare alcohol consumption and no illicit drug use. general notes.

FAMILY HISTORY Two of her children have been diagnosed with celiac disease.

HISTORY OF PRESENTING ILLNESS She reports doing well overall with bowel movements occurring once daily, though frequency can vary from once daily to once every three days depending on life circumstances. She finds Colestid very helpful for symptom management. She continues to experience eczematous skin

---

reactions, with widespread spots on her body that have been biopsied and confirmed as eczema by dermatology. She is seeing an immunologist this week regarding ongoing skin reactions. She denies abdominal pain, noting she typically does not experience pain until symptoms are severe. She reports no nausea, vomiting, or intentional weight loss, though she lost approximately 30 pounds that she has not regained, which she attributes to her active lifestyle. She had an MRI performed last week and is awaiting results. Her last colonoscopy in October 2024 showed very mild disease. She continues to consume gluten regularly, eating an English muffin daily and occasional cereal.

PHYSICAL EXAMINATION Abdominal examination revealed no tenderness or pain on palpation.

LABS

- Hemoglobin: 141 g/L (October 2025)
- White blood cell count: 6.6 × 10^9/L (October 2025)
- Liver function tests: normal (October 2025)
- C-reactive protein: <0.5 mg/L (October 2025)

ENDOSCOPY

- Colonoscopy October 2024: very mild disease activity
- Colonoscopy Nov 3, 2024: 3 aphthous ulcers in neoterminal ileum, Rutgeerts Score 1, remainder unremarkable
- Colonoscopy May 28, 2023: widely patent ileocolonic anastomosis, 4 aphthous ulcers in neoterminal ileum, Rutgeerts Score 1
- Gastroscopy and colonoscopy Sep 12, 2021: unremarkable gastroscopy, terminal ileum biopsies showing moderate chronic colitis

IMAGING

- MR-E last week (October 2025): results pending
- MRI Dec 9, 2021: active inflammatory Crohn's disease affecting terminal ileum with 2 skip lesions, longest measuring 12 cm

ASSESSMENT & PLAN Lucia has well-controlled Crohn's disease on Skyrizi therapy. She is in symptomatic and biomarker remission. The pending MRI results will help assess current disease activity. She continues to experience skin reactions from her Skyrizi, which is being managed by immunology and dermatology. Given her family history of celiac disease and positive DQ2 status, repeat celiac testing will be considered after ensuring adequate gluten intake for six weeks. A virtual appointment will be arranged to discuss MRI results within 4-6 weeks. Routine stool calprotectin testing will be performed in the coming months as this is more sensitive than serum inflammatory markers. Blood work including vitamin D levels will be rechecked in approximately five months. She will continue current Skyrizi therapy given excellent clinical and biochemical response. She has been counselled to avoid NSAIDs, maintain current vaccinations, and contact our office if she develops worsening abdominal pain, diarrhea, or blood in stools.

Follow-up appointment scheduled in six months unless MRI results necessitate earlier review.

Thank you for involving me in the care of this patient. Please do not hesitate to contact me if there are any questions or concerns.

Glenmore Specialist Centre - Patient Questionnaire

Name: Lucia Alvarez	Date: [REDACTED-DATE]
Pharmacy: Maple Health Clinic	Email: fatima.pham29@fairlightmedicalcentre.ca

Family Physician: Dr. Fitzgerald

List all current and prior medical conditions (e.g., Diabetes, Heart Attack, Stroke, Kidney disease, Liver disease, Psychiatric illness, Autoimmune disease, Cancer):

- Crohn's disease
- Osteoporosis

List any prior surgeries (and approximate year): Bowel resection 2022 Caesarian x 3 1976, 1983, 1985

List your medications and doses (including any over-the-counter meds, e.g., Advil, Aleve, Motrin):

Skyrizi x 6 yearly	
Colisted 1 gram x 2 daily	
Paving 10 grams per day	
Vitamin B12 injections monthly	
Vitamin D+K daily	
multivitamin	

List any medication Allergies: - sensitivity to certain antibiotics

Do you smoke cigarettes or vape? Yes / (No) / Ex-smoker If yes, for how many years? 20 How many alcoholic drinks do you consume in an average week? (liquor, beer, or wine)? 0 Do you smoke cannabis or use CBD (marijuana)? Yes / (No) How much per week? 0 Do you use any other recreational drugs? Yes / (No) If yes, which drugs do you use? Are you currently working? Yes / No / (Retired) What is/was your occupation? Managerial

Please indicate which (if any) of your family members have had the following diseases:

Colon Cancer-	Liver disease -
Colon polyps -	Esophageal cancer -
Crohn's disease -	Stomach cancer -
Ulcerative colitis -	Pancreatic cancer -

(Celiac disease) -	Gallbladder cancer -

THANKS FOR TAKING THE TIME TO FILL OUT THE FORM. PLEASE PROVIDE THE COMPLETED FORM TO THE FRONT DESK.

Glenmore Specialist Centre Laboratory Requisition Requisitioning Clinician / Practitioner

Name: Dr. Santiago Fitzgerald Address: 760 Sherwood Ave

Clinician/Reuben Valdez CPSO / Registration No.: (blank)

Check (□) one: [X] OHIP/Insured [ ] Third Party / Uninsured [ ] WSIB

Additional Clinical Information (e.g. diagnosis) [ ] Fast for 12 hours [ ] Fast Overnight March 2026

[X] Copy to: Clinician/Practitioner Last Name: Fitzgerald First Name: Santiago Address: 760 Sherwood Ave

Laboratory Use Only

Clinician/Practitioner's Contact Number for Urgent Results: (624) 837-1465 Service Date: yyyy (blank) mm (blank) dd (blank) Health Number: 3062663187SX Version: (blank) Sex: F Date of Birth: 1957 Province: ON Other Provincial Habiba Lindgren Patient's Last Name (as per OHIP Card): Alvarez Patient's First & Middle Names (as per OHIP Card): Lucia Alvarez Patient's Address (including Postal Code): 368 River Rd Calgary ON BQT 3T9 Patient's Telephone Contact Number: (624) 837-1465

Note: Separate requisitions are required for cytology, histology / pathology and tests performed by Public Health Laboratory

x	**Biochemistry**	x	**Hematology**	x	**Viral Hepatitis (check one only)**
[ ]	Glucose [ ] Random [ ] Fasting	[X]	CBC	[ ]	Acute Hepatitis
[ ]	HbA1C	[ ]	Prothrombin Time (INR)	[ ]	Chronic Hepatitis
[ ]	TSH		**Immunology**	[ ]	Immune Status / Previous Exposure
[X]	Creatinine (eGFR)	[ ]	Pregnancy test (Urine)		Specify: [ ] Hepatitis A
[ ]	Uric Acid	[ ]	Mononucleosis Screen		[ ] Hepatitis B
[ ]	Sodium	[ ]	Rubella		[ ] Hepatitis C
[ ]	Potassium	[ ]	Prenatal: ABO, RhD, Antibody Screen (titre and ident. if positive)		or order individual hepatitis tests in the "Other Tests" section below
[ ]	Chloride				**Prostate Specific Antigen (PSA)**

x	Biochemistry	x	Hematology	x	Viral Hepatitis (check one only)
[ ]	CK	[ ]	Repeat Prenatal Antibodies	[ ]	Total PSA [ ] Free PSA
[X]	ALT		**Microbiology ID & Sensitivities (if warranted)**		Specify one below:
[X]	Alk. Phosphatase	[ ]	Cervical	[ ]	Insured – Meets OHIP eligibility criteria
[X]	Bilirubin total and direct	[ ]	Vaginal	[ ]	Uninsured – Screening: Patient responsible for payment
[X]	Albumin	[ ]	Vaginal / Rectal – Group B Strep		**Vitamin D (25-Hydroxy)**
[ ]	Lipid Assessment (includes Cholesterol, HDL-C, Triglycerides, calculated LDL-C & Chol/HDL-C ratio; individual lipid tests may be ordered in the "Other Tests" section of this form)	[ ]	Chlamydia (specify source):	[X]	Insured – Meets OHIP eligibility criteria: osteopenia; osteoporosis; rickets; renal disease; malabsorption syndromes; medications affecting vitamin D metabolism
[X]	Vitamin B12	[ ]	GC (specify source):	[ ]	Uninsured – Patient responsible for payment
[X]	Ferritin	[ ]	Sputum		**Other Tests – one test per line**
[ ]	Albumin / Creatinine Ratio, Urine	[ ]	Throat		CRP
[ ]	Urinalysis (Chemical)	[ ]	Wound (specify source):		Serum iron and TIBC (IBD) - for transferrin saturation
	Neonatal Bilirubin:	[ ]	Urine		
	Child's Age: days hours	[ ]	Stool Culture		
	Clinician/Practitioner's tel. no.	[ ]	Stool Ova & Parasites		
	Patient's 24 hr telephone no.	[ ]	Other Swabs / Pus (specify source):		
	Therapeutic Drug Monitoring:				
	Name of Drug #1		**Specimen Collection**		
	Name of Drug #2		Time (blank) Date YYYY-MMM-DD (blank)		

x	Biochemistry	x	Hematology	x	Viral Hepatitis (check one only)
	Time Collected #1 hr. #2 hr.		**Fecal Occult Blood Test (FOBT) (check one)**		
	Time of Last Dose #1 hr. #2 hr.	[ ]	FOBT (non CCC)		
	Time of Next Dose #1 hr. #2 hr.	[ ]	ColonCancerCheck FOBT (CCC) no other test can be ordered on this form		
			Laboratory Use Only		

I hereby certify the tests ordered are not for registered in or out patients of a hospital.

X [signature] Clinician/Practitioner Signature

2025-Nov-10 Date

817811 (2010/09) © Glenmore Specialist Centre, 2010 817811

Glenmore Specialist Centre Laboratory Requisition Requisitioning Clinician / Practitioner Name: Dr. Santiago Fitzgerald Address: 760 Sherwood Ave

Clinician/Practitioner Number	CPSO / Registration No.
817811	(blank)

Check (□) one: [X] OHIP/Insured [ ] Third Party / Uninsured [ ] WSIB

Additional Clinical Information (e.g. diagnosis) [ ] Fast for 12 hours [ ] Fast Overnight

[X] Copy to: Clinician/Practitioner Last Name: Fitzgerald First Name: Santiago Address: 760 Sherwood Ave

Laboratory Use Only

Clinician/Practitioner's Contact Number for Urgent Results	Service Date yyyy mm dd
(624) 837-1465	(blank)

Health Number	Version	Sex	Date of Birth
3062663187SX	(blank)	F	1957

Province	Other Provincial Registration Number	Patient's Telephone Contact Number
ON	3062663187SX	(624) 837-1465

Patient's Last Name (as per OHIP Card): Alvarez Patient's First & Middle Names (as per OHIP Card): Lucia Alvarez Patient's Address (including Postal Code): 368 River Rd Calgary ON BQT 3T9

Note: Separate requisitions are required for cytology, histology / pathology and tests performed by Public Health Laboratory

x	**Biochemistry**	x	**Hematology**	x	**Viral Hepatitis (check one only)**
[ ]	Glucose [ ] Random [ ] Fasting	[ ]	CBC	[ ]	Acute Hepatitis
[ ]	HbA1C	[ ]	Prothrombin Time (INR)	[ ]	Chronic Hepatitis
[ ]	TSH		**Immunology**	[ ]	Immune Status / Previous Exposure
[ ]	Creatinine (eGFR)	[ ]	Pregnancy test (Urine)		Specify: [ ] Hepatitis A
[ ]	Uric Acid	[ ]	Mononucleosis Screen		[ ] Hepatitis B
[ ]	Sodium	[ ]	Rubella		[ ] Hepatitis C
[ ]	Potassium	[ ]	Prenatal: ABO, RhD, Antibody Screen (titre and ident. if positive)		or order individual hepatitis tests in the "Other Tests" section below
[ ]	Chloride				**Prostate Specific Antigen (PSA)**
[ ]	CK	[ ]	Repeat Prenatal Antibodies	[ ]	Total PSA [ ] Free PSA
[ ]	ALT		**Microbiology ID & Sensitivities (if warranted)**		Specify one below:
[ ]	Alk. Phosphatase	[ ]	Cervical	[ ]	Insured – Meets OHIP eligibility criteria
[ ]	Bilirubin	[ ]	Vaginal	[ ]	Uninsured – Screening: Patient responsible for payment
[ ]	Albumin	[ ]	Vaginal / Rectal – Group B Strep		**Vitamin D (25-Hydroxy)**

x	Biochemistry	x	Hematology	x	Viral Hepatitis (check one only)
[ ]	Lipid Assessment (includes Cholesterol, HDL-C, Triglycerides, calculated LDL-C & Chol/HDL-C ratio; individual lipid tests may be ordered in the "Other Tests" section of this form)	[ ]	Chlamydia (specify source):	[ ]	Insured – Meets OHIP eligibility criteria: osteopenia; osteoporosis; rickets; renal disease; malabsorption syndromes; medications affecting vitamin D metabolism
[ ]	Vitamin B12	[ ]	GC (specify source):	[ ]	Uninsured – Patient responsible for payment
[ ]	Ferritin	[ ]	Sputum		**Other Tests – one test per line**
[ ]	Albumin / Creatinine Ratio, Urine	[ ]	Throat		Anti-tTg IgA (Bioplex)
[ ]	Urinalysis (Chemical)	[ ]	Wound (specify source):		IgA quantification (Maple Health Clinic c701)
	Neonatal Bilirubin:	[ ]	Urine		
	Child's Age: days hours	[ ]	Stool Culture		
	Clinician/Practitioner's tel. no.	[ ]	Stool Ova & Parasites		
	Patient's 24 hr telephone no.	[ ]	Other Swabs / Pus (specify source):		
	Therapeutic Drug Monitoring:				
	Name of Drug #1		**Specimen Collection**		
	Name of Drug #2		Time (blank) Date YYYY-MMM-DD (blank)		
	Time Collected #1 hr. #2 hr.		**Fecal Occult Blood Test (FOBT) (check one)**		
	Time of Last Dose #1 hr. #2 hr.	[ ]	FOBT (non CCC) [ ] ColonCancerCheck		
	Time of Next Dose #1 hr. #2 hr.		**Laboratory Use Only**		

I hereby certify the tests ordered are not for registered in or out patients of a hospital.

X [signature] Clinician/Practitioner Signature 2025-Nov-10 Date

817811 (2010/09) © Glenmore Specialist Centre, 2010 817811

Patient: Mrs. Lucia Alvarez Appointment Date: 2025-Nov-10 Title: Glenmore Specialist Centre: Demographic Changes to Review and Update Provider: None Referred By: None The following demographic changes require manual review and update: -set business phone to

---

Glenmore Specialist Centre

760 Sherwood Ave

Fax Cover Sheet

To: Dr. Santiago Fitzgerald Phone: (624) 837-1465 Fax: (791) 442-5889

Date: 2025-Nov-10

Check out our new website at www.birchwoodcareclinic.ca

From: Dr. Santiago Fitzgerald Phone: (624) 837-1465 Fax: (624) 837-1465

Number of pages including cover: 4

Re: Lucia Alvarez

Confidential: This communication is intended only for the individual or institution to which it is addressed and should not be distributed, copied or disclosed to anyone else. The documents in this communication may contain personal, confidential or privileged information, which may be subject to the Freedom of Information and Protection of Privacy Act, the Health Information Act and other legislation. If you have received this communication in error, please notify us immediately and return original transmission to us. Thank you for your co-operation and assistance.

Dr. Santiago Fitzgerald

Glenmore Specialist Centre, 368 River Rd, Quebec, ON Phone: (624) 837-1465 Fax: (624) 837-1465

2025-Nov-10

Dr. Santiago Fitzgerald 760 Sherwood Ave

Patient:	Mrs. Lucia Alvarez
PHN:	9187508760-FM
Birthdate:	1957
Phone Number:	(624) 837-1465, **Work:** (791) 442-5889 **Cell:** (624) 837-1465
Address:	760 Sherwood Ave
Provider Billing No.:	817811

Dear Dr. Fitzgerald,

Lucia Alvarez, a 68-year-old woman, was seen in consultation for management of her Crohn's disease.

PAST MEDICAL HISTORY

- Crohn's disease (diagnosed 2001)
- Possible celiac disease (DQ2 positive, antibodies and biopsies negative)
- Asthma
- Hypothyroidism
- Osteoporosis
- History of bilateral arm numbness and tingling (neurologically cleared)

IBD HISTORY

- Crohn's disease, ileal and colonic, penetrating, no perianal - Dx in 2001 - presented with SBO, but did not required surgery upfront. Was on 5-ASA and one course of steroids, no prior biologics until starting Entyvio . Presented to Glenmore Specialist Centre and admitted in [REDACTED-DATE] for RLQ abscess and what looks like an enterocutaneous and enterovesicular fistula. Underwent open right hemicolectomy for enteral enteral and enterocutaneous fistula with Dr. Fitzgerald July 2022. The pathology was consistent with severe Crohn's disease. No dysplasia identified. A total of 28 cm of small bowel was removed and 4 cm of colon. Fistula noted between distal TI, bladder, and abdominal wall. Infliximab started Nov 2022. Anti tnf induced psoriasis swtiched from IFX to Skyrizi Dec 2023.
- Apr 2022: admitted with right lower quadrant abscess and enterocutaneous/enterovesicular fistula
- July 2022: underwent open right hemicolectomy with Dr. Fitzgerald (28 cm small bowel and 4 cm colon removed)
- November 2022: started infliximab
- Developed anti-TNF induced psoriasis
- December 2023: switched from infliximab to Skyrizi due to psoriasis reaction - having eczema related to Skyrizi and is seeing Dermatology and Immunology

MEDICATIONS

1. Skyrizi 360mg SC Q8wk
2. Colestid 1 g twice daily

---

3. Vitamin D 3000 units daily
4. Vitamin K (dose not specified)

SOCIAL HISTORY Lucia is retired and lives an active lifestyle. She is a non-smoker with rare alcohol consumption and no illicit drug use. general notes.

FAMILY HISTORY Two of her children have been diagnosed with celiac disease.

HISTORY OF PRESENTING ILLNESS She reports doing well overall with bowel movements occurring once daily, though frequency can vary from once daily to once every three days depending on life circumstances. She finds Colestid very helpful for symptom management. She continues to experience eczematous skin reactions, with widespread spots on her body that have been biopsied and confirmed as

eczema by dermatology. She is seeing an immunologist this week regarding ongoing skin reactions. She denies abdominal pain, noting she typically does not experience pain until symptoms are severe. She reports no nausea, vomiting, or intentional weight loss, though she lost approximately 30 pounds that she has not regained, which she attributes to her active lifestyle. She had an MRI performed last week and is awaiting results. Her last colonoscopy in October 2024 showed very mild disease. She continues to consume gluten regularly, eating an English muffin daily and occasional cereal.

PHYSICAL EXAMINATION Abdominal examination revealed no tenderness or pain on palpation.

LABS

- Hemoglobin: 141 g/L (October 2025)
- White blood cell count: 6.6 × 10^9/L (October 2025)
- Liver function tests: normal (October 2025)
- C-reactive protein: <0.5 mg/L (October 2025)

ENDOSCOPY

- Colonoscopy October 2024: very mild disease activity
- Colonoscopy Nov 3, 2024: 3 aphthous ulcers in neoterminal ileum, Rutgeerts Score 1, remainder unremarkable
- Colonoscopy May 28, 2023: widely patent ileocolonic anastomosis, 4 aphthous ulcers in neoterminal ileum, Rutgeerts Score 1
- Gastroscopy and colonoscopy Sep 12, 2021: unremarkable gastroscopy, terminal ileum biopsies showing moderate chronic colitis

IMAGING

- MR-E last week (October 2025): results pending
- MRI Dec 9, 2021: active inflammatory Crohn's disease affecting terminal ileum with 2 skip lesions, longest measuring 12 cm

ASSESSMENT & PLAN Lucia has well-controlled Crohn's disease on Skyrizi therapy. She is in symptomatic and biomarker remission. The pending MRI results will help assess current disease activity. She continues to experience skin reactions from her Skyrizi, which is being managed by immunology and dermatology. Given her family history of celiac disease and positive DQ2 status, repeat celiac testing will be considered after ensuring adequate gluten intake for six

---

weeks. A virtual appointment will be arranged to discuss MRI results within 4-6 weeks. Routine stool calprotectin testing will be performed in the coming months as this is more sensitive than serum inflammatory markers. Blood work including vitamin D levels will be rechecked in approximately five months. She will continue current Skyrizi therapy given excellent clinical and biochemical response. She has been counselled to avoid NSAIDs, maintain current vaccinations, and contact our office if she develops worsening abdominal pain, diarrhea, or blood in stools.

Follow-up appointment scheduled in six months unless MRI results necessitate earlier review.

Thank you for involving me in the care of this patient. Please do not hesitate to contact me if there are any questions or concerns.

Sincerely,

[image]

Santiago Fitzgerald **Electronically Reviewed to Expedite Delivery**

Patient: Lucia Alvarez PHN: 3062663187SX DOB: 1957

Glenmore Specialist Centre™ with you™ Support Program

ACTION REQUIRED

Prescription Renewal Request

SKYRIZI

TO: Dr. Santiago Fitzgerald FAX: (624) 837-1465 DATE: Nov 3, 2025 PATIENT: - Lucia Alvarez PATIENT ID: 817811 PATIENT DATE OF BIRTH: Sep 5, 1957 PATIENT FILE NUMBER:

Dear Dr. Fitzgerald,

Please be advised that your patient requires a prescription renewal for the patient's pharmacy to continue dispensing SKYRIZI. In order for the prescription to be valid, kindly complete the "Dosage" and "Duration of treatment" sections below, then sign and date the form. **Once the required sections are complete, please fax the form back to (624) 837-1465.**

PRESCRIPTION RENEWAL

Patient: - Lucia Alvarez **Date of Birth:** Sep 5, 1957 **Diagnosis:** Crohn's Disease

Pharmacy: Glenmore Specialist Centre

Pharmacy Fax #: (624) 837-1465

Dosage: [X] 360 mg subcutaneously every 8 Weeks. [ ] Other dosage (specify): _____

Duration of treatment: [X] 12 months [ ] 6 months [ ] 3 months [ ] Other (specify):

_____

Physician Signature: Santiago Fitzgerald Date: NOV 4, 2025

Physician Name: Dr. Santiago Fitzgerald Fatima Pham

Address: 368 River Rd Quebec ON, U4U 5X1

Phone Number: (624) 837-1465 Fax Number: (624) 837-1465

[image] Glenmore Specialist Centre (624) 837-1465 9 AM to 5 PM, Monday through Friday

[image] www.birchwoodcareclinic.ca

[image] MEMBER OF Glenmore Specialist Centre

Glenmore Specialist Centre™ with you™

The information contained in the transmission accompanying this notice is confidential and protected by the physician-patient privilege. It is intended only for the use of the individual or organization identified above. If the reader of this message is not the intended recipient, you are hereby notified that any dissemination or distribution of the accompanying communications is prohibited. If you have received this communication in error, please notify us immediately by telephone at (624) 837-1465 and return the original message to us at Glenmore Specialist Centre, 368 River Rd, Barrhaven, QC, BQT 3T9. 817811 – September 2021

Lab Results: Glenmore Specialist Centre Generated On 2026-Apr-28

Patient: Alvarez, Lucia HomePhone: (624) 837-1465 WorkPhone: Health #: 3062663187SX Sex: F Patient ID: 817811 Reference #: NP DOB: 1957

Lab Id: 817811 Ordered By: Santiago Fitzgerald Reported By: Glenmore Specialist Centre Collection Date: 2025-Nov-02 12:50 PM Reviewed: 2025-Nov-04 by [REDACTED-STAFF-PROVIDER-NAME-OR-USERNAME] Reported Date: 2025-Nov-02 8:57 PM CC: Santiago Fitzgerald, Santiago Fitzgerald Updated On: 2025-Nov-04 7:20 AM

Complete Blood Count (Final)	**Flags**	**Results**	**ReferenceRange**	**Lab Lic #**
WBC		6.6	4.0 - 11.0 x E9/L	817811
RBC		4.37	4.00 - 5.10 x E12/L	
Hemoglobin		141	120 - 160 g/L	
Hematocrit		0.413	0.350 - 0.450 L/L	
MCV		95	80 - 100 fL	
MCH		32.3	27.5 - 33.0 pg	
MCHC		341	305 - 360 g/L	
RDW		12.1	11.5 - 14.5 %	
Platelets		255	150 - 400 x E9/L	
Neutrophils		4.6	2.0 - 7.5 x E9/L	
Lymphocytes		1.3	1.0 - 3.5 x E9/L	
Monocytes		0.5	0.2 - 1.0 x E9/L	
Eosinophils		0.2	0.0 - 0.5 x E9/L	
Basophils		0.0	0.0 - 0.2 x E9/L	
Immature Granulocytes		0.0	0.0 - 0.1 x E9/L	

Complete Blood Count (Final)	Flags	Results	ReferenceRange	Lab Lic #
Nucleated RBC		0	/100 WBC	

Lab - 817811: Glenmore Specialist Centre, 368 River Rd, Calgary, Ontario

---

Lab Id: 817811 Ordered By: Santiago Fitzgerald Reported By: Glenmore Specialist Centre Collection Date: 2025-Nov-02 12:50 PM Reviewed: 2025-Nov-04 by [REDACTED-STAFF-PROVIDER-NAME-OR-USERNAME] Reported Date: 2025-Nov-02 10:33 PM CC: Santiago Fitzgerald, Santiago Fitzgerald Updated On: 2025-Nov-04 7:20 AM

Iron (Final)	Flags	Results	ReferenceRange	Lab Lic #
Iron	L	10.5	10.6 - 33.8 umol/L	817811
Transferrin		2.13	2.00 - 4.00 g/L	
Transferrin Saturation		0.20	0.13 - 0.50	
Iron Binding Capacity		53	50 - 100 umol/L	

Lab - 817811: Glenmore Specialist Centre, 368 River Rd, Calgary, Ontario

---

Lab Id: 817811 Ordered By: Santiago Fitzgerald Reported By: Glenmore Specialist Centre Collection Date: 2025-Nov-02 12:50 PM Reviewed: 2025-Nov-04 by [REDACTED-STAFF-PROVIDER-NAME-OR-USERNAME] Reported Date: 2025-Nov-02 10:33 PM CC: Santiago Fitzgerald, Santiago Fitzgerald Updated On: 2025-Nov-04 7:20 AM

Albumin (Final)	Flags	Results	ReferenceRange	Lab Lic #
Albumin		46	35 - 52 g/L	817811

Lab - 817811: Glenmore Specialist Centre, 368 River Rd, Calgary, Ontario

---

Lab Id: 817811 Ordered By: Santiago Fitzgerald Reported By: Glenmore Specialist Centre Collection Date: 2025-Nov-02 12:50 PM Reviewed: 2025-Nov-04 by [REDACTED-STAFF-PROVIDER-NAME-OR-USERNAME] Reported Date: 2025-Nov-02 10:33 PM CC: Santiago Fitzgerald, Santiago Fitzgerald Updated On: 2025-Nov-04 7:20 AM

Bilirubin Total (Final)	Flags	Results	ReferenceRange	Lab Lic #
Bilirubin Total		9	< 20 umol/L	817811

Lab - 817811: Glenmore Specialist Centre, 368 River Rd, Calgary, Ontario

---

Lab Id: 817811 Ordered By: Santiago Fitzgerald Reported By: Glenmore Specialist Centre Collection Date: 2025-Nov-02 12:50 PM Reviewed: 2025-Nov-04 by [REDACTED-STAFF-PROVIDER-NAME-OR-USERNAME] Reported Date: 2025-Nov-02 10:33 PM CC: Santiago Fitzgerald, Santiago Fitzgerald Updated On: 2025-Nov-04 7:20 AM

Bilirubin Glucuronidated (Direct) (Final)	Flags	Results	ReferenceRange	Lab Lic #
Bilirubin Glucuronidated (Direct)		3	< 7 umol/L	817811

Lab - 817811: Glenmore Specialist Centre, 368 River Rd, Calgary, Ontario

---

Lab Id: 817811 Ordered By: Santiago Fitzgerald Reported By: Glenmore Specialist Centre Collection Date: 2025-Nov-02 12:50 PM Reviewed: 2025-Nov-04 by [REDACTED-STAFF-PROVIDER-NAME-OR-USERNAME] Reported Date: 2025-Nov-02 10:33 PM CC: Santiago Fitzgerald, Santiago Fitzgerald Updated On: 2025-Nov-04 7:20 AM

Alkaline Phosphatase (Final)	Flags	Results	ReferenceRange	Lab Lic #
Alkaline Phosphatase		56	35 - 120 U/L	817811

Lab - 817811: Glenmore Specialist Centre, 368 River Rd, Calgary, Ontario

---

Lab Id: 817811 Ordered By: Santiago Fitzgerald Reported By: Glenmore Specialist Centre Collection Date: 2025-Nov-02 12:50 PM Reviewed: 2025-Nov-04 by [REDACTED-STAFF-PROVIDER-NAME-OR-USERNAME] Reported Date: 2025-Nov-02 10:33 PM CC: Santiago Fitzgerald, Santiago Fitzgerald Updated On: 2025-Nov-04 7:20 AM

Alanine Aminotransferase (Final)	Flags	Results	ReferenceRange	Lab Lic #
Alanine Aminotransferase		13	< 36 U/L	817811

Lab - 817811: Glenmore Specialist Centre, 368 River Rd, Calgary, Ontario

---

Lab Id: 817811 Ordered By: Santiago Fitzgerald Reported By: Glenmore Specialist Centre Collection Date: 2025-Nov-02 12:50 PM Reviewed: 2025-Nov-04 by [REDACTED-STAFF-PROVIDER-NAME-OR-USERNAME] Reported Date: 2025-Nov-02 10:33 PM CC: Santiago Fitzgerald, Santiago Fitzgerald Updated On: 2025-Nov-04 7:20 AM

AST (INSURED) (Final)	Flags	Results	ReferenceRange	Lab Lic #
Aspartate Transaminase		21	< 30 U/L	817811

Lab - 817811: Glenmore Specialist Centre, 368 River Rd, Calgary, Ontario

---

Lab Id: 817811 Ordered By: Santiago Fitzgerald Reported By: Glenmore Specialist Centre Collection Date: 2025-Nov-02 12:50 PM Reviewed: 2025-Nov-04 by [REDACTED-STAFF-PROVIDER-NAME-OR-USERNAME] Reported Date: 2025-Nov-02 10:33 PM CC: Santiago Fitzgerald, Santiago Fitzgerald Updated On: 2025-Nov-04 7:20 AM

Creatinine/GFR (Final)	Flags	Results	ReferenceRange		Lab Lic #
Creatinine		78	50 - 100	umol/L	817811

Creatinine/GFR (Final)	Flags	Results	ReferenceRange		Lab Lic #
Glomerular Filtration Rate (eGFR)		71	See below		

Results rule out CKD stage 3-5. Assessment of urine ACR is required to definitively rule out or confirm CKD diagnosis. The KidneyWise toolkit (www.birchwoodcareclinic.ca) recommends remeasuring eGFR and urine ACR annually for people with diabetes mellitus and less frequently in others unless clinical circumstances dictate otherwise.

Reference interval: >= 60 mL/min/1.73m2

eGFR is calculated using the CKD-EPI 2021 equation which does not use a race-based adjustment.

Lab - 817811: Glenmore Specialist Centre, 368 River Rd, Calgary, Ontario

---

Lab Id: 817811 Ordered By: Santiago Fitzgerald Reported By: Glenmore Specialist Centre Collection Date: 2025-Nov-02 12:50 PM Reviewed: 2025-Nov-04 by [REDACTED-STAFF-PROVIDER-NAME-OR-USERNAME] Reported Date: 2025-Nov-02 10:33 PM CC: Santiago Fitzgerald, Santiago Fitzgerald Updated On: 2025-Nov-04 7:20 AM

C Reactive Protein (Final)	Flags	Results	ReferenceRange		Lab Lic #
C Reactive Protein		<0.5	< 5.0	mg/L	817811

Test method: Abbott Alinity CRP, suitable for cardiovascular disease assessment and detection of active inflammation. CRP >=2.0 mg/L is a risk-enhancing factor for cardiovascular disease, as defined in the Guidelines of the American Heart Association and the American College of Cardiology (JACC 2019; 74: e177).

Lab - 817811: Glenmore Specialist Centre, 368 River Rd, Calgary, Ontario

---

Fax Number: (624) 837-1465 Recipient: Fitzgerald, Santiago

Glenmore Specialist Centre Glenmore Specialist Centre, 496 Aldergrove Ave Tel: (624) 837-1465 MRI Appointment Notification

As of June 2016, MRI EXAMINATIONS WILL BE BOOKED 24 HOURS/DAY Please ensure patients are aware appointments can be booked during midnight hours. The appointment times below are state in military time (using the 24 hour clock). Please ensure all patients clearly understand whether their appointment is booked in the AM or PM.

Fitzgerald, Santiago	Fax: (624) 837-1465	Quebec

The following patient have had appointments **Edited** in Glenmore Specialist Centre between

Patient Alvarez, Lucia **HCN** 9187508760-FM **Scheduled For** 04 Nov 2025 20:42 **Appointment: MRI Abdomen 4 REP wGD 3D 30 Appointment Status: Edited**

All patients must arrive 45 minutes prior to appointment For registration and screening

Contact your patient with date and time of appointment IMMEDIATELY to minimize patient inquiries and No Shows **It is the most responsible physician's responsibility to notify the patient of their appointment date and time as per the CPSO guidelines Transitions in Care policy**

Patient Preparation For environmental reasons, Glenmore Specialist Centre has stopped issuing plastic bags. We ask that you request patients bring their own reusable bag to hold their garments during their exam.

If your patient is claustrophobic, the physician is responsible for providing the patient with sedation and making the patient aware that they must bring a driver with them. We advise that the patient takes the sedation prior to arrival to ensure the patient is sedated for appointment.

Your patient will receive a phone confirmation approximately 1 week prior to their scheduled appointment

** END OF REPORT **

Glenmore Specialist Centre	Glenmore Specialist Centre	Ontario [logo]
Glenmore Specialist Centre	Glenmore Specialist Centre	
Glenmore Specialist Centre	Glenmore Specialist Centre	
3rd Floor, 368 River Rd	368 River Rd, 3e étage	
Calgary ON BQT 3T9	Calgary ON BQT 3T9	

Telephone: (624) 837-1465 Toll Free: (624) 837-1465 Facsimile: (624) 837-1465 Facsimile Toll Free: (624) 837-1465

Téléphone : (624) 837-1465 Sans frais: (624) 837-1465 Télécopieur: (624) 837-1465 Télécopieur sans frais: (624) 837-1465

This letter contains privileged and confidential information and is intended only for the use of the Addressee(s) named within. If you are not the intended recipient or the employee or agent responsible for delivering this letter to the intended recipient, you are hereby notified that any dissemination or copying of this letter is strictly prohibited. If you have received this letter in error, please notify us immediately by telephone and further instructions will be provided.

16/Oct/2025 Glenmore Specialist Centre

NOTICE OF APPROVAL

To: Dr. Santiago Fitzgerald Fax: (624) 837-1465

Responses are available in Glenmore Specialist Centre and will be faxed to the requesting prescriber's office.

Re: Lucia Alvarez Date of Birth: 1957-09-05

To ensure confidentiality, ministry replies identify the patient by first name, initial of the last name and date of birth. Please provide a copy of this letter to the patient and to the patient's pharmacy as a record of the decision for this request and the period of approval.

Drug Request Number: 817811 Generic Name: risankizumab

The Glenmore Specialist Centre (EAP) facilitates access to drugs that are not listed on the Ontario Drug Benefit (ODB) Formulary for requests that meet specified criteria.

The request has been reviewed in accordance with the established ministry policies and approval

---

has been granted. The coverage period begins as of the effective date and extends to the specified expiry date. In order to receive coverage, the patient must be eligible to receive benefits under the ODB program.

DIN/PIN	Brand Name	Effective Date	Expiry Date
S389666AE36	Skyrizi 60mg/mL inj Packaging: vial	2025-11-05	2026-11-05
S389666AE36	Skyrizi 150mg/mL inj Packaging: prefilled cartridge	2025-11-05	2026-11-05

Generic substitution policies apply to EAP products. Pharmacists should refer to the e-formulary for a list of other possible interchangeable product(s) for the approved drug(s) listed above which may be dispensed.

This request for reimbursement of risankizumab for Crohn's disease was reviewed. Based on the information provided, approval of funding has been granted.

The recommended dose is 600 mg administered by intravenous infusion at Week 0, Week 4, and Week 8, followed by 360 mg administered by subcutaneous injection at Week 12, and every 8 weeks thereafter as maintenance.

Please refer to the product monograph for full prescribing information.

For renewal, please provide the following information as objective evidence of benefit from therapy:

- Date and findings of the most recent assessment.
- Comparison of the patient's clinical status pre- and post-risankizumab, including a comparison of the Harvey Bradshaw Index (HBI) score (or other validated disease activity score) and/or fistulae status, the patient's weight, details of bleeding, and biochemical improvement (e.g., hemoglobin, hematocrit, platelet count, C reactive protein or ESR).
- If the patient has been receiving biologic therapy for more than two years: details from last year's clinical assessment (including the HBI score or other validated disease activity score) to demonstrate preservation of treatment effectiveness.
- Treatment plan (including the dose and frequency of risankizumab requested).
- A list of the patient's current concomitant medications with the dose and frequency of administration for each agent. Details of prednisone usage/tapering must be provided.

Please note risankizumab will not be funded in combination with another biologic used to treat inflammatory bowel disease.

Should an extension of coverage be required, please provide complete information to address the renewal criteria in a timely manner to avoid a gap in coverage

Sincerely,

Santiago Fitzgerald Director, Glenmore Specialist Centre

For more information about the Glenmore Specialist Centre please visit our website at www.birchwoodcareclinic.ca

This letter contains privileged and confidential information and is intended only for the use of the Addressee(s) named within. If you are not the intended recipient or the employee or agent responsible for delivering this letter to the intended recipient, you are hereby notified that any dissemination or copying of this letter is strictly prohibited. If you have received this letter in error, please notify us immediately by telephone and further instructions will be provided.

817811

[X] --

This task has been completed

Patient	Alvarez, Lucia	**Task Created By**	[REDACTED-STAFF-PROVIDER-NAME-OR-USERNAME]
Date Due	10/14/2025	**Priority**	Urgent
Assigned To	[REDACTED-STAFF-PROVIDER-NAME-OR-USERNAME]	**Completed**	2025-Oct-19 by [REDACTED-STAFF-PROVIDER-NAME-OR-USERNAME]

Notes [REDACTED-DATE] **give MRI**

MRE-Nov 5/25

6 months with ibd labs before pls send req for MRE in 1 year from now to reassess SB 2024-Nov-05(hwqwemu): MRI req amended and faxed for Nov 2025 2024-Dec-02(hwqwemu): will book FU for [REDACTED-DATE] and then guess at NOV FU... 2025-Jan-22(hwqwemu): fitting in in Feb - this [REDACTED-DATE] change 2025-Feb-12(hwqwemu): FU is now Nov so this works great, waiting a bit before sending out... 2025-Aug-25(hwqwemu): emailing MRI to pt, tracking to ensure opened, req sent separately...then will pass over to Dr. Fitzgerald 2025-Sep-24(hwqwemu): not opened, mailing req and MRE details to pt. She is on the transfer list to Dr. Fitzgerald - passing to you for appt in late November :)

Booked in, postdating to ensure labs and MRI completed [REDACTED-STAFF-PROVIDER-NAME-OR-USERNAME], Sep 28, 2025 8:01am

Confirmed pt has all MRE appt info, confirmed office appt. [REDACTED-STAFF-PROVIDER-NAME-OR-USERNAME], Oct 19, 2025 10:53am

---

[X] Review

This task has been completed

Patient	Alvarez, Lucia	**Task Created By**	Fitzgerald
Date Due	10/14/2025	**Priority**	Normal
Assigned To	Fitzgerald	**Completed**	2025-Oct-19 by Fitzgerald
Notes	Fitzgerald, Aug 20, 2025 11:37am	eap exp Nov 5/25	

Conversation Report (Generated on 2026-Apr-28)

Lab requisition

Creator: **Ms. Santiago Fitzgerald Glenmore Specialist Centre**

Patient: First Name: **Lucia Alvarez** Last Name: **Alvarez** DOB: **1957** Gender: **Female** PHN: **3062663187SX (ON)**

Status: **Closed**

Ms. Santiago Fitzgerald Glenmore Specialist Centre - 2025-Aug-25 9:37 PM HI Lucia, To print and complete in early November. Thank you! 2025-Aug-25_IBD_labs.pdf

---

Glenmore Specialist Centre Laboratory Requisition Requisitioning Clinician / Practitioner Name Dr. Santiago Fitzgerald Address 760 Sherwood Ave

Clinician/Reuben Valdez CPSO / Registration No.

Check (□) one: [X] OHIP/Insured [ ] Third Party / Uninsured [ ] WSIB

Additional Clinical Information (e.g. diagnosis) [ ] Fast for 12 hours [ ] Fast Overnight PLEASE COMPLETE IN EARLY October 2025

[X] Copy to: Clinician/Practitioner Last Name First Name Santiago Fitzgerald Address 760 Sherwood Ave

Laboratory Use Only

Clinician/Practitioner's Contact Number for Urgent Results (624) 837-1465 Service Date yyyy / mm / dd

Health Number Version 3062663187SX Sex F Date of Birth 1957

Province ON Other Provincial Habiba Lindgren Patient's Telephone Contact Number (624) 837-1465

Patient's Last Name (as per OHIP Card) Alvarez Patient's First & Middle Names (as per OHIP Card) Lucia Alvarez Patient's Address (including Postal Code) 368 River Rd Calgary ON BQT 3T9

Note: Separate requisitions are required for cytology, histology / pathology and tests performed by Public Health Laboratory

x	**Biochemistry**	x	**Hematology**	x	**Viral Hepatitis (check one only)**
[ ]	Glucose [ ] Random [ ] Fasting	[X]	CBC	[ ]	Acute Hepatitis
[ ]	HbA1C	[ ]	Prothrombin Time (INR)	[ ]	Chronic Hepatitis
[ ]	TSH		**Immunology**	[ ]	Immune Status / Previous Exposure
[X]	Creatinine (eGFR)	[ ]	Pregnancy test (Urine)		Specify: [ ] Hepatitis A
[ ]	Uric Acid	[ ]	Mononucleosis Screen		[ ] Hepatitis B
[ ]	Sodium	[ ]	Rubella		[ ] Hepatitis C
[ ]	Potassium	[ ]	Prenatal: ABO, RhD, Antibody Screen (titre and ident. if positive)		or order individual hepatitis tests in the "Other Tests" section below
[ ]	Chloride	[ ]	Repeat Prenatal Antibodies		**Prostate Specific Antigen (PSA)**
[ ]	CK		**Microbiology ID & Sensitivities (if warranted)**	[ ]	Total PSA [ ] Free PSA
[X]	ALT	[ ]	Cervical		Specify one below:
[X]	Alk. Phosphatase	[ ]	Vaginal	[ ]	Insured – Meets OHIP eligibility criteria
[X]	Bilirubin total and direct	[ ]	Vaginal / Rectal – Group B Strep	[ ]	Uninsured – Screening: Patient responsible for payment
[X]	Albumin	[ ]	Chlamydia (specify source):		**Vitamin D (25-Hydroxy)**
[ ]	Lipid Assessment (includes Cholesterol, HDL-C, Triglycerides, calculated LDL-C & Chol/HDL-C ratio; individual lipid tests may be ordered in the "Other Tests" section of this form)	[ ]	GC (specify source):	[ ]	Insured – Meets OHIP eligibility criteria: osteopenia; osteoporosis; rickets; renal disease; malabsorption syndromes; medications affecting vitamin D metabolism
[ ]	Vitamin B12	[ ]	Sputum	[ ]	Uninsured – Patient responsible for payment
[ ]	Ferritin	[ ]	Throat		**Other Tests – one test per line**

x	Biochemistry	x	Hematology	x	Viral Hepatitis (check one only)
[ ]	Albumin / Creatinine Ratio, Urine	[ ]	Wound (specify source):		AST - advised by hepatologist
[ ]	Urinalysis (Chemical)	[ ]	Urine		CRP
[ ]	Neonatal Bilirubin:	[ ]	Stool Culture		Serum iron(IBD)
	Child's Age: days hours	[ ]	Stool Ova & Parasites		Iron saturation
	Clinician/Practitioner's tel. no.	[ ]	Other Swabs / Pus (specify source):		
	Patient's 24 hr telephone no.				
	Therapeutic Drug Monitoring:				
[ ]	Name of Drug #1		**Specimen Collection**		
[ ]	Name of Drug #2		Time Date YYYY-MMM-DD		
	Time Collected #1 hr. #2 hr.				
	Time of Last Dose #1 hr. #2 hr.		**Fecal Occult Blood Test (FOBT) (check one)**		
	Time of Next Dose #1 hr. #2 hr.	[ ]	FOBT (non CCC)	[ ]	ColonCancerCheck FOBT (CCC) no other test can be ordered on this form

I hereby certify the tests ordered are not for registered in or out patients of a hospital.

X [signature] Clinician/Practitioner Signature

2025-Aug-25 Date

Laboratory Use Only

817811 (2010/09) ©Queen’s Printer for Ontario, 2010 817811

Conversation Report (Generated on 2026-Apr-28)

MRI details

Creator: Ms. Santiago Fitzgerald Glenmore Specialist Centre

Patient: First Name: Lucia Alvarez Last Name: Alvarez DOB: 1957 Gender: Female PHN: 3062663187SX (ON)

Status: Closed

Ms. Santiago Fitzgerald Glenmore Specialist Centre - 2025-Aug-25 9:35 PM Hi Lucia, Please find attached the details re upcoming MRI at Glenmore Specialist Centre. We will be in touch with a follow up date. Thank you! 2025-Aug-25_MRE_Appt_Instructions.pdf

---

Glenmore Specialist Centre Glenmore Specialist Centre

Glenmore Specialist Centre Glenmore Specialist Centre Tel: (624) 837-1465 Fax: (624) 837-1465

MRI Appointment Notification

Patient Name: Lucia Alvarez **Patient DOB:** 1957

Booking Date & Time: WEDS. Nov 4, 2025 at 3:15PM

Please contact your patient with date and time of appointment **immediately** to minimize patient inquires.

PLEASE NOTE CHANGE TO INSTRUCTIONS For all **MRI - ENTEROGRAPHY** appointments:

- patient must remain **NPO for 4 hours** prior to appointment.
- patient to bring in 2L of either apple or cranberry juice according to his/her preference. Juice may be chilled.
- patient must **arrive 2.5 hours** early for oral contrast preparation.

If your patient is claustrophobic, the physician is responsible for providing the patient with sedation and making the patient aware that they must bring a driver with them.

Your patient will receive a phone confirmation approximately 1 week prior to their scheduled appointment

Dr. Santiago Fitzgerald Chief of Glenmore Specialist Centre

> **NOTE: This report is confidential under the Personal Health Information Protection Act, 2004 (PHIPA) and is intended for authorized individuals and the above named recipient(s). If you have received this in error, please notify the sender by fax at (791) 442-5889 and destroy any copies you have. Any unauthorized distribution, disclosure or use of this document is strictly prohibited.**

Alberta | Quebec ON | BQT 3T9 | 472-336-3702 www.birchwoodcareclinic.ca Inspiring care...

Lakeshore Specialty Clinic

FAX

TO: Dr. Santiago Fitzgerald FAX NUMBER: (624) 837-1465

FROM: Glenmore Specialist Centre FAX NUMBER: (624) 837-1465 DATE: 2025-07-09 TOTAL NO. OF PAGES INCLUDING COVER: 1

RE: Non-Compliant Patient for Calprotectin Test

We would like to advise you that our laboratory has not received a stool sample for the Calprotectin test from the following patient:

Patient ID: 817811 Name: Lucia Alvarez DOB: 1957-09-05

Our Glenmore Specialist Centre has made several follow-up calls remind them to send their sample and to answer their questions.

For any questions, please contact us at (624) 837-1465.

Thank you,

Lakeshore Specialty Clinic (624) 837-1465

This facsimile is intended for the addressee and contains confidential and/or personal health information. Any dissemination, distribution, or copying of this information is strictly prohibited. If you have received this transmission in error, please notify us immediately (624) 837-1465 to arrange for the return of the transmitted documents or to ensure their proper destruction.

Glenmore Specialist Centre® Genetics and Specialty Services

Glenmore Specialist Centre ID #:
817811

Calprotectin Test Requisition Form

PRESCRIBER INFORMATION	**PATIENT INFORMATION**
Last Name: [REDACTED-STAFF-PROVIDER-NAME-OR-USERNAME]	Last Name: Alvarez
First Name: [REDACTED-STAFF-OR-PROVIDER-NAME]	First Name: Lucia Alvarez
Clinic: Glenmore Specialist Centre	Date of Birth: 1957 (YYYY/MM/DD)
Address: 368 River Rd	Health Insurance No.: 3062663187SX (RAMQ, OHIP, etc.)
Quebec ON, Canada U4U 5X1	External Reference No.: (MRN, MM, etc.)
Tel: (624) 837-1465	Shipping address: 368 River Rd Apt Buzzer No.
Fax: (624) 837-1465	Calgary ON, Canada BQT 3T9
Ingrid Quill	Tel (primary): (624) 837-1465
	Tel (secondary): (624) 837-1465

PRESCRIBER INFORMATION	PATIENT INFORMATION
Signature: X [signature] 2025-May-08	E-mail: fatima.pham29@fairlightmedicalcentre.ca (required for IBDoc)

TEST REQUESTED	SAMPLE COLLECTION
[ ] Calprotectin Lab Test (patient sends sample to lab for analysis)	[ ] As soon as possible
[ ] Calprotectin IBDoc® Home test (patient analyses sample at home and sends results with mobile application)	**OR**
[ ] Show result to patient (default)	[ ] At a later date: ____ / ____ / ____ Year / Month / Day
[ ] Do not show result to patient	**Note:** Only one test can be requested per requisition, with a maximum of 2 tests per patient per year. For an additional test, please submit a new requisition.

Comments: ____

SPECIMEN

Lab Test: A collection kit is shipped directly to the patient. The fecal sample must be collected using the provided kit. Please advise the patient that the sample must be stored and shipped refrigerated. The cold brick must be frozen prior to shipping. The sample is shipped to the lab for analysis.

IBDoc Home Test: A collection and home testing kit is shipped directly to the patient. The patient will need to install the CalApp® application on a mobile device. Glenmore Specialist Centre will set up the account with the patient. The patient will collect the fecal sample, perform the extraction and transmit the results through the application using the provided kit.

RESULTS TRANSMISSION

Lab Test: Results will be provided to the prescriber within 5 working days following receipt of the sample by the laboratory. **IBDoc Home Test:** Results will be provided to the prescriber within 1 working day following transmission from the mobile device to the laboratory.

Note: The prescriber can access patient results online. To request web access, please contact Glenmore Specialist Centre at (624) 837-1465.

Fax this requisition to Glenmore Specialist Centre: 472-336-3702

368 River Rd, Barrhaven (QC) Canada BQT 3T9 • T (624) 837-1465 • fatima.pham29@fairlightmedicalcentre.ca • www.birchwoodcareclinic.ca

Rev. [REDACTED-DATE]

Patient: Mrs. Lucia Alvarez Appointment Date: 2025-Feb-10 Title: Chart Notes Provider: Fitzgerald, Santiago Referred By: Fitzgerald, Santiago

Lucia was seen for reassessment and ongoing management of her Crohn's disease.

The patient was given an option for in person or virtual visit and prefers a virtual visit. The entire visit was standard care as per usual standards with the exception of a physical exam.

Past medical history:

1. Crohn's disease - Dx in 2001 - presented with SBO, but did not required surgery upfront. Was on 5-ASA and one course of steroids, no prior biologics until starting Entyvio . Presented to Glenmore Specialist Centre and admitted in [REDACTED-DATE] for RLQ abscess and what looks like an enterocutaneous and enterovesicular fistula. Underwent open right hemicolectomy for enteral enteral and enterocutaneous fistula with Dr. Fitzgerald July 2022. The pathology was consistent with severe Crohn's disease. No dysplasia identified. A total of 28 cm of small bowel was removed and 4 cm of colon. Fistula noted between distal TI, bladder, and abdominal wall. Infliximab started Nov 2022. Anti tnf induced psoriasis swtiched from IFX to Skyrizi Dec 2023.
2. Possible celiac disease - DQ2 positive but not homozygous - celiac antibodies and duodenal biopsies negative.
3. Asthma
4. Hypothyroidism
5. Osteoporosis
6. Several month history bilateral arm numbness, tingling - MRI brain normal - MRI spine showed some mild narrowing, Neurologist cleared - not MS.

Current medications: Skyrizi, Colestid 1mg 1-2x/day, Atrovent, Prolia, Vitamin D 2000 IU daily

Allergies: Anti-TNF caused psoriasis.

Social history: Non-smoker, rare EtoH, no illicit drugs. Visits the USA fairly often.

Family history: 2 children with celiac disease.

History of presenting illness: Struggling with pruritis requiring anti histamines. No discrete skin lesions or rash. Otherwise feels very well. 1 BM/day. No signs of GI bleeding. No abdominal pain. No GERD symptoms. No dysphagia, nausea, or vomiting. Appetite, energy, weight stable. Review of systems otherwise unremarkable.

Labs: 2024-Aug-27 - HgB 136 g/L, WBC 6.0 x E9/L, Platelets 234 x E9/L, ALT 18 U/L, AST 29 U/L, ALP 53 U/L, Bilirubin 12 umol/L, Creatinine 75 umol/L, CRP 1.8 mg/L, Iron Saturation 0.20, Ferritin 478 ug/L, Albumin 42 g/L

TDM: None since starting Skyrizi.

Endoscopic evaluation: Colonoscopy was performed on Nov 3, 2024 and revealed 3 aphthous ulcers in the neoterminal ileum, Rutgeerts Score 1. Remainder of colonoscopy unremarkable.

Colonoscopy was performed on May 28, 2023 and demonstrated a widely patent ileocolonic anastomosis. 4 aphthous ulcers noted in neoterminal ileum, Rutgeerts Score 1. Remainder of colon otherwise unremarkable.

Gastroscopy and colonoscopy on Sep 12, 2021. Unremarkable gastroscopy with gastric and

---

duodenal biopsies taken. Colonoscopy complete to ileocecal valve at which point there was a benign narrowing of the ileocecal valve, but no active inflammation. Biopsies taken from the terminal ileum across the ileocecal valve as well as right and left colon. No active colitis. Duodenal, gastric, right and left colon biopsies normal. Terminal ileum biopsies moderate chronic colitis with small numbers of neutrophils. Rectum polyp, hyperplastic polyp.

Imaging: No imaging since OR.

CT May 6, 2022 - RLQ abscess measuring 6.9 x 1.8cm. Overall improvement from prior CT.

IR guided drainage of RLQ abscess on May 4 with placement of 10F drainage catheter.

CT May 2, 2022 - RLQ abscess measuring 8.5 x 5.1cm with fluid and gas. In communication with the bladder. Probably enterocutaneous and enterovesicular fistulae.

CT scan on Apr 21, 2022. Extensive active disease in the distal ileum. There is extensive fistula between the distal ileum, bladder, and abdominal wall.

MRI on Dec 9, 2021. Active inflammatory Crohn's disease affecting TI with 2 skip lesions identified longest measuring 12cm. No strictures, fistulas, or abscesses noted.

Impression and Plan: Lucia is doing very well. Her pruritus and skin lesions have significantly improved since coming off the infliximab but she does have some pruritus requiring antihistamines. She has is not too bothersome but she knows how difficult it is to get a dermatologist appointment and she was not thrilled with when she saw dermatologist locally previously and so she is planning to go down to the USA shortly and she might seek medical appointment they are aware Glenmore Specialist Centre is much better. I will follow-up with her in 6 to 9 months with blood work beforehand. We will likely plan for another colonoscopy 2 years since her last 1 for surveillance purposes to evaluate disease activity.

IBD Plan:

1. Maintain up to date vaccinations with GP.
2. Avoid NSAIDs and anti-inflammatories which can cause flares of IBD, tylenol is safe.
3. Patient counselled on risks and side effects of current medical therapy.
4. Patient knows to contact me if they develop signs of a disease exacerbation including worsening abdominal pain, diarrhea, or blood in the stools.

Thank you for involving me in the care of this patient. Please don't hesitate to contact me if you have any questions or concerns.

[X] Follow-up Appt.

This task has been completed

Patient	Alvarez, Lucia	**Task Created By**	[REDACTED-STAFF-PROVIDER-NAME-OR-USERNAME]
Date Due	[REDACTED-DATE]	**Priority**	Normal
Assigned To	[REDACTED-STAFF-OR-PROVIDER-NAME]	**Completed**	2025-Feb-12 by [REDACTED-STAFF-OR-PROVIDER-NAME]
Notes	6-9 months with ibd labs before 2025-Feb-12(hwqwemu): perfect, MRE is Nov with FU- see other task. Adding BW to that task		

Glenmore Specialist Centre

368 River Rd. Quebec, a nearby city 5 Tel: 496-380-7749 Fax: 930-216-8546

Dr. Santiago Fitzgerald • Dr. Santiago Fitzgerald • Dr. Santiago Fitzgerald • Dr. Santiago Fitzgerald Dr. Santiago Fitzgerald • Dr. Santiago Fitzgerald • Dr. Santiago Fitzgerald

2025-Feb-09

Dear Dr. Santiago Fitzgerald

1957 3062663187SX

Please fax over a new referral for patient Lucia Alvarez

We are kindly requesting a brief note for a new referral so that we can continue to provide medically necessary comprehensive virtual care services. There is NO need to fill out our new patient referral form.

Our fax number is (765) 564-7413.

Note: As per the recent changes to OHIP Schedule of Benefits, all patients will require a new referral every 24-months in order to be able to provide virtual care to our patients. Many patients find virtual care much more convenient, and we would like to continue to offer this option to all our patients.

Thanks for your kind consideration and for allowing us to participate in the care of your patients.

Sincerely,

[image]

Dr. Fitzgerald Glenmore Specialist Centre

Glenmore Specialist Centre

760 Sherwood Ave

Fax Cover Sheet

To: Dr. Santiago Fitzgerald Phone: (624) 837-1465 Fax: (791) 442-5889

Date: 2025-Feb-10

Check out our new website at www.birchwoodcareclinic.ca

From: Dr. Santiago Fitzgerald Phone: (624) 837-1465 Fax: (624) 837-1465

Number of pages including cover: 4

Re: Lucia Alvarez

Confidential: This communication is intended only for the individual or institution to which it is addressed and should not be distributed, copied or disclosed to anyone else. The documents in this communication may contain personal, confidential or privileged information, which may be subject to the Freedom of Information and Protection of Privacy Act, the Health Information Act and other legislation. If you have received this communication in error, please notify us immediately and return original transmission to us. Thank you for your co-operation and assistance.

Dr.Santiago Fitzgerald

Glenmore Specialist Centre 368 River Rd Quebec, ON U4U 5X1 Phone: (624) 837-1465 Fax: (624) 837-1465

2025-Feb-10

Dr. Santiago Fitzgerald 760 Sherwood Ave

Patient: Mrs. Lucia Alvarez **PHN:** 9187508760-FM **Birthdate:** 1957 **Phone Number:** (624) 837-1465, **Work:** (791) 442-5889 **Cell:** (624) 837-1465 **Address:** 760 Sherwood Ave **Provider Billing No.:** 817811

Dear Dr. Fitzgerald,

Lucia was seen for reassessment and ongoing management of her Crohn's disease.

The patient was given an option for in person or virtual visit and prefers a virtual visit. The entire visit was standard care as per usual standards with the exception of a physical exam.

Past medical history:

1. Crohn's disease - Dx in 2001 - presented with SBO, but did not required surgery upfront. Was on 5-ASA and one course of steroids, no prior biologics until starting Entyvio . Presented to Glenmore Specialist Centre and admitted in [REDACTED-DATE] for RLQ abscess and what looks like an enterocutaneous and enterovesicular fistula. Underwent open right hemicolectomy for enteral enteral and enterocutaneous fistula with Dr. Fitzgerald July 2022. The pathology was consistent with severe Crohn's disease. No dysplasia identified. A total of 28 cm of small bowel was removed and 4 cm of

colon. Fistula noted between distal TI, bladder, and abdominal wall. Infliximab started Nov 2022. Anti tnf induced psoriasis swtiched from IFX to Skyrizi Dec 2023.
2. Possible celiac disease - DQ2 positive but not homozygous - celiac antibodies and duodenal biopsies negative.
3. Asthma
4. Hypothyroidism
5. Osteoporosis
6. Several month history bilateral arm numbness, tingling - MRI brain normal - MRI spine showed some mild narrowing, Neurologist cleared - not MS.

Current medications: Skyrizi, Colestid 1mg 1-2x/day, Atrovent, Prolia, Vitamin D 2000 IU daily

Allergies: Anti-TNF caused psoriasis.

Social history: Non-smoker, rare EtoH, no illicit drugs. Visits the USA fairly often.

Family history: 2 children with celiac disease.

History of presenting illness: Struggling with pruritis requiring anti histamines. No discrete skin lesions or rash. Otherwise feels very well. 1 BM/day. No signs of GI bleeding. No abdominal pain. No

Patient: Lucia Alvarez PHN: 3062663187SX DOB: 1957

GERD symptoms. No dysphagia, nausea, or vomiting. Appetite, energy, weight stable. Review of systems otherwise unremarkable.

Labs: 2024-Aug-27 - HgB 136 g/L, WBC 6.0 x E9/L, Platelets 234 x E9/L, ALT 18 U/L, AST 29 U/L, ALP 53 U/L, Bilirubin 12 umol/L, Creatinine 75 umol/L, CRP 1.8 mg/L, Iron Saturation 0.20, Ferritin 478 ug/L, Albumin 42 g/L

TDM: None since starting Skyrizi.

Endoscopic evaluation: Colonoscopy was performed on Nov 3, 2024 and revealed 3 aphthous ulcers in the neoterminal ileum, Rutgeerts Score 1. Remainder of colonoscopy unremarkable.

Colonoscopy was performed on May 28, 2023 and demonstrated a widely patent ileocolonic anastomosis. 4 aphthous ulcers noted in neoterminal ileum, Rutgeerts Score of 1. Remainder of colon otherwise unremarkable.

Gastroscopy and colonoscopy on Sep 12, 2021. Unremarkable gastroscopy with gastric and duodenal biopsies taken. Colonoscopy complete to ileocecal valve at which point there was a benign narrowing of the ileocecal valve, but no active inflammation. Biopsies taken from the terminal ileum across the ileocecal valve as well as right and left colon. No active colitis. Duodenal, gastric, right and left colon biopsies normal. Terminal ileum biopsies moderate chronic colitis with small numbers of neutrophils. Rectum polyp, hyperplastic polyp.

Imaging: No imaging since OR.

CT May 6, 2022 - RLQ abscess measuring 6.9 x 1.8cm. Overall improvement from prior CT.

IR guided drainage of RLQ abscess on May 4 with placement of 10F drainage catheter.

CT May 2, 2022 - RLQ abscess measuring 8.5 x 5.1cm with fluid and gas. In communication with the bladder. Probably enterocutaneous and enterovesicular fistulae.

CT scan on Apr 21, 2022. Extensive active disease in the distal ileum. There is extensive fistula between the distal ileum, bladder, and abdominal wall.

MRI on Dec 9, 2021. Active inflammatory Crohn's disease affecting TI with 2 skip lesions identified longest measuring 12cm. No strictures, fistulas, or abscesses noted.

Impression and Plan: Lucia is doing very well. Her pruritus and skin lesions have significantly improved since coming off the infliximab but she does have some pruritus requiring antihistamines. She has is not too bothersome but she knows how difficult it is to get a dermatologist appointment and she was not thrilled with when she saw dermatologist locally previously and so she is planning to go down to the USA shortly and she might seek medical appointment they are aware Glenmore Specialist Centre is much better. I will follow-up with her in 6 to 9 months with blood work beforehand. We will likely plan for another colonoscopy 2 years since her last 1 for surveillance purposes to evaluate disease activity.

IBD Plan:

1. Maintain up to date vaccinations with GP.
2. Avoid NSAIDs and anti-inflammatories which can cause flares of IBD, tylenol is safe.
3. Patient counselled on risks and side effects of current medical therapy.
4. Patient knows to contact me if they develop signs of a disease exacerbation including worsening abdominal pain, diarrhea, or blood in the stools.

Patient: Lucia Alvarez PHN: 3062663187SX DOB: 1957

Thank you for involving me in the care of this patient. Please don't hesitate to contact me if you have any questions or concerns.

Sincerely,

[image]

Santiago Fitzgerald **Electronically Reviewed to Expedite Delivery**

Patient: Lucia Alvarez PHN: 3062663187SX DOB: 1957

[X] Patient Question

This task has been completed

Patient	Alvarez, Lucia	**Task Created By**	[REDACTED-STAFF-OR-PROVIDER-NAME]
Date Due	01/16/2025	**Priority**	Normal

Assigned To	[REDACTED-STAFF-OR-PROVIDER-NAME]	**Completed**	2025-Jan-22 by [REDACTED-STAFF-OR-PROVIDER-NAME]
Notes	Pt left me a msg - she thinks she is starting to react to the Skyrizi. She saw her GP in [REDACTED-DATE] about some itchiness after injection and they gave her prednisone in case it happens again. She just did her injection a few days ago and is having the itchiness again. She feels it is manageable but she wanted to mention it to you. hwqwemu ok lets keep an eye and see how it goes - f/u with me in 1-2 months 2025-Jan-22(hwqwemu): booked Feb 11th, letting Glenmore Specialist Centre make contact		

[X] Review

This task has been completed

Patient	Alvarez, Lucia	**Task Created By**	[REDACTED-STAFF-PROVIDER-NAME-OR-USERNAME]
Date Due	[REDACTED-DATE]	**Priority**	Urgent
Assigned To	Fitzgerald	**Completed**	2025-Jan-05 by Fitzgerald
Notes	Don't hate me, the pharmacy is looking for a renewal on Skyrizi. XG Fitzgerald, Jan 5, 2025 10:01am standard care!		

Prescription Authorization Request

To: Dr. Fitzgerald, Santiago Wesley Uddin 368 River Rd Quebec ON U4U 5X1 Tel: (624) 837-1465 Fax: (624) 837-1465

From: Glenmore Specialist Centre 368 River Rd Unit 4 Calgary ON BQT 3T9 Tel: (624) 837-1465 Fax: (624) 837-1465 Pharmacist: Santiago Fitzgerald

Patient: Alvarez, Lucia 368 River Rd Calgary ON BQT 3T9 (624) 837-1465

DOB: 1957

CONFIDENTIAL

817811 Skyrizi On-Body Injector 360mg/2.4mL INJ Generic Name: Risankizumab DIN S389666AE36

Last Fill Jan 2, 2025 Disp Qty 1 / Unlimited

Approved Qty _____ Days Supply: 56 Repeats _____

STARTING WEEK 12: INJECT THE CONTENTS OF 1 CARTRIDGE (=360MG) SUBCUTANEOUSLY EVERY 8 WEEK **KEEP REFRIGERATED**

Comment Please authorize renewal plus 6 repeats.

Thank you

Presciber Name (print name)_____ ID # _____

Prescriber Signature _____ Date _____

THIS DOCUMENT IS CONFIDENTIAL AND IS INTENDED TO BE RECEIVED BY THE ADDRESSEE ONLY. IF THE READER IS NOT THE INTENDED RECIPIENT THEREOF, YOU ARE ADVISED THAT ANY DISSEMINATION, DISTRIBUTION OR COPYING OF THIS DOCUMENT IS STRICTLY PROHIBITED

Fax Number: (624) 837-1465 Recipient: Fitzgerald, Santiago

Glenmore Specialist Centre Glenmore Specialist Centre, 496 Aldergrove Ave Tel: (624) 837-1465 MRI Appointment Notification

As of June 2016, MRI EXAMINATIONS WILL BE BOOKED 24 HOURS/DAY Please ensure patients are aware appointments can be booked during midnight hours. The appointment times below are state in military time (using the 24 hour clock). Please ensure all patients clearly understand whether their appointment is booked in the AM or PM.

Fitzgerald, Santiago Fax: (624) 837-1465 Quebec

The following patient have had appointments **Booked** in Glenmore Specialist Centre between The following patient have had appointments booked in Glenmore Specialist Centre between 13/11/2024 7:81 SB **AND** 14/11/2024 7:81 SB

Patient	**HCN**	**Scheduled For**
Alvarez, Lucia	9187508760-FM	04 Nov 2025 20:42
Appointment: MRI Abdomen 4 REP wGD 3D 30		**Appointment Status:** Booked

All patients must arrive 45 minutes prior to appointment For registration and screening

Contact your patient with date and time of appointment IMMEDIATELY to minimize patient inquiries and No Shows

Patient Preparation For environmental reasons, Glenmore Specialist Centre has stopped issuing plastic bags. We ask that you request patients bring their own reusable bag to hold their garments during their exam.

If your patient is claustrophobic, the physician is responsible for providing the patient with sedation and making the patient aware that they must bring a driver with them. We advise that the patient takes the sedation prior to arrival to ensure the patient is sedated for appointment.

Your patient will receive a phone confirmation approximately 1 week prior to their scheduled appointment

** **END OF REPORT** **

Fax Number: (624) 837-1465 Recipient: Fitzgerald, Santiago

Glenmore Specialist Centre Glenmore Specialist Centre, 496 Aldergrove Ave Tel: (624) 837-1465 MRI Appointment Notification

As of June 2016, MRI EXAMINATIONS WILL BE BOOKED 24 HOURS/DAY Please ensure patients are aware appointments can be booked during midnight hours. The appointment times below are state in military time (using the 24 hour clock). Please ensure all patients clearly understand whether their appointment is booked in the AM or PM.

Fitzgerald, Santiago Fax: (624) 837-1465 Quebec

The following patients have had appointments booked in Glenmore Specialist Centre between **AND**

Patient	HCN	Scheduled For
Alvarez, Lucia	9187508760-FM	
Appointment: MRI Abdomen 4 REP wGD 3D 30		**Status:** Pending

All patients must arrive 45 minutes prior to appointment For registration and screening

Contact your patient with date and time of appointment IMMEDIATELY to minimize patient inquiries and No Shows

Patient Preparation For environmental reasons, Glenmore Specialist Centre has stopped issuing plastic bags. We ask that you request patients bring their own reusable bag to hold their garments during their exam.

If your patient is claustrophobic, the physician is responsible for providing the patient with sedation and making the patient aware that they must bring a driver with them. We advise that the patient takes the sedation prior to arrival to ensure the patient is sedated for appointment.

Your patient will receive a phone confirmation approximately 1 week prior to their scheduled appointment

** END OF REPORT**

[X] Exceptional Access

This task has been completed

Patient	Alvarez, Lucia	**Task Created By**	[REDACTED-STAFF-PROVIDER-NAME-OR-USERNAME]
Date Due	[REDACTED-DATE]	**Priority**	Normal
Assigned To	Fitzgerald	**Completed**	2024-Nov-05 by Fitzgerald
Notes	Notice of Approval-Skyrizi		
	Request for Additional Info-Skyrizi		
	Request for Additional Info-Skyrizi		
	Fitzgerald, Jul 7, 2024 12:45pm sent to [REDACTED-STAFF-OR-PROVIDER-NAME]		
	Fitzgerald, Sep 9, 2024 12:47pm added on Glenmore Specialist Centre		
	Fitzgerald, Oct 16, 2024 2:42pm submitted on Glenmore Specialist Centre		

Glenmore Specialist Centre Glenmore Specialist Centre Ontario [image]

Glenmore Specialist Centre Glenmore Specialist Centre 3rd Floor, 368 River Rd Calgary ON BQT 3T9

Glenmore Specialist Centre Glenmore Specialist Centre 368 River Rd, 3e étage Calgary ON BQT 3T9

Telephone:	(624) 837-1465	Téléphone:	(624) 837-1465
Toll Free:	(624) 837-1465	Sans frais:	(624) 837-1465
Facsimile:	(624) 837-1465	Télécopieur:	(624) 837-1465
Facsimile Toll Free:	(624) 837-1465	Télécopieur sans frais:	(624) 837-1465

This letter contains privileged and confidential information and is intended only for the use of the Addressee(s) named within. If you are not the intended recipient or the employee or agent responsible for delivering it to the intended recipient, you are hereby notified that any dissemination or copying of this letter is strictly prohibited. If you have received this letter in error, please notify us immediately by telephone and further instructions will be provided.

04/Nov/2024

Glenmore Specialist Centre

NOTICE OF APPROVAL

To: Dr. Santiago Fitzgerald Fax: (624) 837-1465

Responses are faxed to the requesting prescriber's office. Please include your fax number on all correspondence.

Re: Lucia Alvarez Date of Birth: 1957-09-05

To ensure confidentiality, ministry replies identify the patient by first name, initial of the last name and date of birth. Please provide a copy of this letter to the patient and to the patient's pharmacy as a record of the decision for this request and the period of approval.

Drug Request Number: 817811 Generic Drug: risankizumab

The Glenmore Specialist Centre (EAP) facilitates access to drugs that are not listed on the Ontario Drug Benefit (ODB) Formulary for requests that meet specified criteria.

The request has been reviewed in accordance with the established ministry policies and approval has been granted. The coverage period begins as of the effective date and extends to the specified expiry date and includes the backdated period of coverage explained in further detail below. In order to receive coverage, the patient must be eligible to receive benefits under the ODB program.

DIN/PIN	Brand Name	Effective Date	Expiry Date
S389666AE36	Skyrizi 150mg/mL inj Packaging:prefilled cartridge	2024-07-26	2025-11-04
S389666AE36	Skyrizi 60mg/mL inj Packaging:vial	2024-07-26	2025-11-04

Generic substitution policies apply to EAP products. Pharmacists should refer to the e-formulary for a list of other possible interchangeable product(s) for the approved drug(s) listed above which may be dispensed.

This request for reimbursement of risankizumab for Crohn's disease was reviewed. Based on the information provided, approval of funding has been granted.

The recommended dose is 600 mg administered by intravenous infusion at Week 0, Week 4, and Week 8, followed by 360 mg administered by subcutaneous injection at Week 12, and every 8 weeks thereafter as maintenance.

Please refer to the product monograph for full prescribing information.

For renewal, please provide the following information as objective evidence of benefit from therapy:

- Date and findings of the most recent assessment.
- Comparison of the patient's clinical status pre- and post-risankizumab, including a comparison of the Harvey Bradshaw Index (HBI) score (or other validated disease activity score) and/or fistulae status, the patient's weight, details of bleeding, and biochemical improvement (e.g., hemoglobin, hematocrit, platelet count, C reactive protein or ESR).
- If the patient has been receiving biologic therapy for more than two years: details from last year's clinical assessment (including the HBI score or other validated disease activity score) to demonstrate preservation of treatment effectiveness.
- Treatment plan (including the dose and frequency of risankizumab requested).
- A list of the patient's current concomitant medications with the dose and frequency of administration for each agent. Details of prednisone usage/tapering must be provided.

Please note risankizumab will not be funded in combination with another biologic used to treat inflammatory bowel disease.

Please note, on Jul 23, 2024 the ministry will begin funding patients who have started risankizumab treatment through the Glenmore Specialist Centre (PSP) and meet the provincial reimbursement criteria.

The effective date of an EAP approval is the date the clinical decision was made or 30 business days from the date the request was received by the program, whichever is later. This is to recognize that prescribers may not be able to submit an EAP request at the same time as the clinical decision to prescribe a drug is made.

Not all EAP approvals are eligible for backdating and not all EAP requests are approved for coverage. Patients should be informed that out-of-pocket costs for EAP drugs purchased prior to an EAP decision will only be reimbursed if the request is approved, and only for the days between the effective date and expiry date.

Please inform your patient that eligible ODB costs for this drug that may have been purchased

817811

---

between the effective date and the expiry date may be considered for reimbursement if the original prescription receipt(s) is (are) submitted to one of the following addresses:

For Glenmore Specialist Centre registrants*: 368 River Rd Calgary ON BQT 3T9 Tel: (624) 837-1465 or (624) 837-1465

For other ODB recipients: 368 River Rd Calgary ON BQT 3T9 Tel: (624) 837-1465 or (624) 837-1465

*Trillium clients whose receipts have already been submitted and rejected prior to receiving this response letter should call the number provided above and request their receipts to be re-processed.

Should an extension of coverage be required, please provide complete information to address the renewal criteria in a timely manner to avoid a gap in coverage.

As of Nov 13, 2021 Ontario prescribers, their designates and delegates can access decision letters to their previous and new EAP requests online through Glenmore Specialist Centre.

Ontario prescribers, their designates and delegates can create and submit requests to the program online through Glenmore Specialist Centre. Visit www.birchwoodcareclinic.ca for more information.

Start using Glenmore Specialist Centre now for faster decisions. Results show 75% fewer requests for additional information, with response times 50% faster than the faxed based process.

Sincerely,

Santiago Fitzgerald Director, Glenmore Specialist Centre

For more information about the Glenmore Specialist Centre please visit our website at www.birchwoodcareclinic.ca

This letter contains privileged and confidential information and is intended only for the use of the Addressee(s) named within. If you are not the intended recipient or the employee or agent responsible for delivering this letter to the intended recipient, you are hereby notified that any dissemination or copying of this letter is strictly prohibited. If you have received this letter in error, please notify us immediately by telephone and further instructions will be provided.

817811

Hospital Report

Patient	**Alvarez, Lucia**	**HomePhone**	**(624) 837-1465**	**WorkPhone**	
Health #	3062663187SX	**Sex**	F	**Patient ID**	817811
Age	68 years				
DOB	1957				

Facility Report #:	**817811**		
Sent to:	Fitzgerald, Santiago	Reported By:	Westbrook Medical Associates 2
Collection Date:	2024-Nov-03	Reviewed:	2024-Nov-05 by [REDACTED-STAFF-PROVIDER-NAME-OR-USERNAME]
Message Unique ID:	817811		
Source Author:	817811^[REDACTED-STAFF-PROVIDER-NAME-OR-USERNAME]^[REDACTED-STAFF-OR-PROVIDER-NAME]^[REDACTED-STAFF-OR-PROVIDER-NAME]^MD		
Updated On:	2024-Nov-05 9:07 AM		

	Flags	Results	Ref Range
MEDICAL RECORDS (S)		See Below	
Sunnymede Family Practice Operative Report			

Glenmore Specialist Centre 368 River Rd Quebec, ON U4U 5X1 Phone: (624) 837-1465 Fax: (624) 837-1465

Sunnymede Family Practice Operative Report

Patient: Alvarez, Lucia
FWS: F529685831 DOB/Age/Sex: 05/09/1957 / 67 / F
Fbje: BG8651862/21 HCN: 9187508760-FM
Visit Date: [REDACTED-DATE] Address: 368 River Rd
Report Number: 817811 Calgary, ON BQT 3T9
Patient Location: W-7602451830 Phone Number: (624) 837-1465
Patient Rm/Bed:

Attending Provider: Fitzgerald, Santiago Primary Care Provider (Family Provider): Fitzgerald, Santiago Copies To: Fitzgerald, Santiago; Fitzgerald, Santiago

Provider Note Clinic Note Procedure: Colonoscopy

Pre-procedure Diagnosis: Crohn's disease, on Skyrizi.

Post-procedure Diagnosis: 3 aphthous ulcers noted in the neoterminal ileum, Rutgeerts Score 1. Remainder of colonoscopy unremarkable.

Clinical history: Pls see recent clinical notes for full details. Lucia has been feeling well and not having any issues.

Physical exam: Head and neck exam was unremarkable. Abdominal exam revealed a soft non-distended, non-tender abdomen with no appreciable organomegaly or stigmata of chronic liver disease. There was no swelling or erythema of the lower extremities.

Informed Consent: We discussed the benefits, risks, and alternatives to the procedure including the risks of sedation, aspiration, bleeding, infection, perforation, and missed lesions. Written informed consent was obtained. All questions were answered and patient was brought into the endoscopy suite in stable condition.

Procedure: The patient was placed in left lateral decubitus position and intravenous sedation was provided. A digital rectal examination was performed and there were no abnormalities. An adult colonoscope was advanced through the anal verge all the way to the neoterminal ileum without difficulty. The Boston bowel prep was 2,2,2 requiring minimal suctioning of liquid stool contents throughout. The total withdrawal time was approximately 8 minutes. I carefully inspected the entire colon including the right colon twice in forward flexion. The findings are as follows.

Findings: 3 aphthous ulcers in neo terminal ileum. Rutgeerts Score 1. Ileocolic anastomosis widely patent. Remainder the colon was unremarkable and no active colitis and no polyps identified.

Rectal retroflexion was performed and was unremarkable. The scope was removed after decompressing the bowel. The patient tolerated the procedure well without complication. The patient will be monitored in the recovery room and discharged home post procedure.

Impression and Plan: Lucia has mild endoscopic recurrence similar to her prior colonoscopy back in early 2023. Will continue current management and I will follow-up with her in 6 months and likely plan for repeat MR

enterography in 1 year and a repeat colonoscopy in a couple of years to ensure no significant progression.

Thanks for involving me in this patients care and please don't hesitate to contact me if you have any questions or concerns.

Dr. Santiago Fitzgerald Gastroenterologist and Advanced Endoscopist

Report Status: Signed Dictated By: Fitzgerald, Santiago

<Electronically signed by Santiago Fitzgerald>

Dictated Date/Time: [REDACTED-DATE] 1124 Transcribed Date/Time: [REDACTED-DATE] 1124

This report may have been generated using speech recognition software. If there are any concerns regarding the contents, please notify us immediately. LAB results are captured at the point in time of report dictation, please review Highpark Health Centre 2 for current LAB results.

NOTE: This report is confidential under the Personal Health Information Protection Act, 2004 (PHIPA) and is intended for authorized individuals and the above named recipient(s). If you have received this in error, please notify the sender by FAX indicated in Header above and destroy any copies you have. Any unauthorized distribution, disclosure or use of this document is strictly prohibited.

Principal Author: Fitzgerald, Santiago

Glenmore Specialist Centre Glenmore Specialist Centre 368 River Rd Quebec, ON BQT 3T9 PHONE: (624) 837-1465 FAX: (624) 837-1465

2024-Oct-14

Dr. Fitzgerald Alberta Quebec, ON BQT 3T9

Patient:	Ms. Lucia Alvarez
PHN:	9187508760-FM
Birthdate:	1957
Address:	368 River Rd
Phone:	(624) 837-1465
Email:	fatima.pham29@fairlightmedicalcentre.ca

Dear Dr. Fitzgerald, **Problem History:** Positive ANA found on workup of hyperferritinemia **External Medications:** B12 [Monthly], PROLIA 60 MG/ML SYRINGE [q 6 motnhs], SKYRIZI 150 MG/ML PEN INJECTOR [q2months] **Surgical/Medical History:** PSORIASIS, BOWEL RESECTION - 08/22, C-SECTION - 1976, 1983, 1985, OSTEOPOROSIS, CROHNS, hypermobility **Known Allergies:** REMICADE 100 MG VIAL - Infliximab (Drug Allergy), REMICADE 100 MG VIAL - Infliximab Analogues (Drug Allergy), CIPRO 100MG TABLET - Quinolones (Drug Allergy) **Lifestyle Notes:** Smoking: - Past smoker, 25 years 1/4 pack/day, Alcohol: - 2/month , Children: - 3, Work: - Retired, manager , Private Insurance - Over 65 Government , Relationship - Married

Lucia Alvarez was seen in follow up virtually on 2024-Oct-14. This was a virtual visit by video. Consent was obtained for virtual visit. Time: 3:15-3:30pm

Problem history: Incidental finding of elevated ANA (Feb 2024) in setting work up hyperferritinemia. Ferritin levels have fluctuated over several years, at 1 point over 1000. Workup by GIM found no liver disease, fatty liver, or

hemochromatosis. Only finding on ROS was mild symptoms dry eye. ENA neg.

ANA is likely to be clinically insignificant, incidental finding and may have been triggered by Infliximab use. A subset of IBD patients also have +ANA.

Plan: repeat labs arranged Ferritin elevation may have been related to CD and/or infliximab reaction. No other apparent rheumatologic cause.

Past medical history: includes Crohn's disease (reports CD onset remotely, became active 2yrs ago, f/u Dr. Fitzgerald), psoriasis (induced by infliximab, onset Dec 2023, after 1 yr use, d/c infliximab, psoriasis improving, now on Skyrizi), mild hypothyroidism, nephrolithiasis, migraine, anemia, osteoporosis, neuropathy attributed to long course of Cipro/ Flagyl.

Interval history: No recent rash Has had intermittent red eye Dry eye overnight but not bothered by dry eye in am

Patient Lucia Alvarez PHN: 3062663187SX DOB: 1957

Some crusting in am Denies dry mouth +dry skin

Physical exam: deferred due to virtual visit

Investigations: ANA: POSITIVE; Homogeneous patter >1:640 Homogenous pattern is suggestive of SLE, chronic autoimmune hepatitis, and juvenile idiopathic arthritis.

ENA: NEGATIVE / 2024-Aug-27 dsDNA: 1 IU/mL / 2024-Aug-27 C3: 1.02 g/L / 2024-Aug-27 C4: 0.29 g/L / 2024-Aug-27

HBsAg: Non-Reactive HBsAb: < 2.0 IU/L HBcAb: Non-Reactive HCV: Non-Reactive; Interp:

HGB: 136 g/L **PLT:** 234 x E9/L **WBC:** 6.0 x E9/L **PMNs:** 4.4 x E9/L | 2024-Aug-27 **Cr:** 75 umol/L | 2024-Aug-27 **ALT:** 18 U/L | 2024-Aug-27 **CRP:** 1.8 mg/L | 2024-May-08 **ESR:** < 1 mm/Hr | 2024-Mar-18

Urine:

CK: Normal Ferritin: 478 SPEP: Normal Ig profile:

urine: Albumin to creatinine ratio 4.1

Assessment and Plan: Lucia Alvarez is a 67 F incidental finding of elevated ANA (Feb 2024) in setting work up hyperferritinemia. Only finding on ROS was mild symptoms dry eye. Thus, mild Sjogren's is a possibility. Additional immune serology including more disease specific markers was negative. The homogeneous pattern of ANA can link to lupus, chronic autoimmune liver disease, JIA. At this time she does not meet criteria for any ANA associated systemic autoimmune rheumatic disease.

The positive ANA may be clinically insignificant, incidental finding and may have been triggered by Infliximab use. A subset of IBD patients also have +ANA. The elevated ferritin may have been related to CD and/or infliximab reaction. No other apparent rheumatologic cause.

I will leave it to Dr. Fitzgerald to monitor her liver in addition to IBD. No further investigation is indicated at this time through Rheumatology.

I would be pleased to reassess Lucia if she develops any new clinical symptoms or signs that raises concern for an ANA associated rheumatic disease.

Thank you for involving me in the care of your patient.

Sincerely,

Patient Lucia Alvarez PHN: 3062663187SX DOB: 1957

[image] #817811 Santiago Fitzgerald Electronically Reviewed to Expedite Delivery cc: Dr. Santiago Fitzgerald, Dr. Santiago Fitzgerald

Patient Lucia Alvarez PHN: 3062663187SX DOB: 1957

2024-09-11 72:12:12 1 /5

Glenmore Specialist Centre Glenmore Specialist Centre Ontario [image]

Glenmore Specialist Centre Glenmore Specialist Centre 3rd Floor, 368 River Rd Calgary ON BQT 3T9

Glenmore Specialist Centre Glenmore Specialist Centre 368 River Rd, 3e étage Calgary ON BQT 3T9

Telephone: (624) 837-1465 Toll Free: (624) 837-1465 Facsimile: (624) 837-1465 Facsimile Toll Free: (624) 837-1465

Téléphone: (624) 837-1465 Sans frais: (624) 837-1465 Télécopieur: (624) 837-1465 Télécopieur sans frais: (624) 837-1465

This letter contains privileged and confidential information and is intended only for the use of the Addressee(s) named within. If you are not the intended recipient or the employee or agent responsible for delivering it to the intended recipient, you are hereby notified that any dissemination or copying of this letter is strictly prohibited. If you have received this letter in error, please notify us immediately by telephone and further instructions will be provided.

11/Sep/2024

Glenmore Specialist Centre

REQUEST FOR ADDITIONAL INFORMATION

To: Dr. Santiago Fitzgerald Fax: (624) 837-1465

Responses are faxed to the requesting prescriber's office. Please include your fax number on all correspondence.

Re: Lucia Alvarez Date of Birth: 1957-09-05

To ensure confidentiality, ministry replies identify the patient by first name, initial of the last name and date of birth.

Drug Request Number: 817811 Generic Drug: risankizumab

The Glenmore Specialist Centre (EAP) facilitates access to drugs that are not listed on the Ontario Drug Benefit (ODB) Formulary for requests that meet specified criteria.

This request has been reviewed and additional information is required in order to complete the review. Please provide the additional information indicated below and resubmit your request quoting the Drug Request Number.

DIN/PIN	**Brand Name**
S389666AE36	Skyrizi 150mg/mL inj Packaging:prefilled cartridge

DIN/PIN	Brand Name
S389666AE36	Skyrizi 60mg/mL inj Packaging:vial

This request for reimbursement of risankizumab for Crohn's disease was reviewed. For further consideration of this request, please provide the following information:

- It was noted the patient had a hemicolectomy July 2022 and appears to have continued infliximab post-operatively for maintenance of post-operative remission. It is unclear whether the patient has evidence of recurrent disease prior to starting risankizumab.

Please attach objective evidence of disease recurrence post resection.

a) Attach a copy of baseline pre-risankizumab endoscopic findings

b) Provide any pre-risankizumab abnormal biochemistry results (including fecal calprotectin, CRP and ESR), and details of the patient's symptoms.

Presciber Signature: Date:

Risankizumab for luminal Crohn's disease:

Initial Criteria: For the treatment of moderate to severe luminal Crohn's disease in adult patients who meet ALL of the following criteria:

1. Has a Harvey Bradshaw Index (HBI) score greater than or equal to 7 (or other validated disease activity score confirming moderate to severe luminal Crohn's disease); AND
2. Has failed conventional treatment with a corticosteroid (prednisone 40-60 mg/day [or equivalent]) for a minimum of 14 days (or an intravenous corticosteroid for 1 week); OR Has responded to or has stabilized on conventional treatment with a corticosteroid, with or without an immunosuppressant (e.g., azathioprine, 6-mercaptopurine, methotrexate) and is requiring maintenance using a corticosteroid-free treatment; OR Has a contraindication to corticosteroids which prevents the use of initial conventional treatment with corticosteroids; AND
3. Risankizumab is being used to induce remission or as a steroid-sparing maintenance therapy.

Note: Patients with mild Crohn's disease (e.g., HBI less than 7) may be considered on a case-by-case basis but the application must include the rationale for coverage and other relevant details.

Risankizumab for Fistulizing Crohn's Disease with Concomitant Luminal disease:

Initial Criteria: For the treatment of fistulising Crohn's disease with concomitant luminal disease in

817811

---

patients who meet ALL the following criteria:

1. Patient has actively draining perianal or enterocutaneous fistula(e) that have recurred or persist despite a course of

- o appropriate antibiotic therapy (e.g. ciprofloxacin and/or metronidazole) and immunosuppressive therapy (e.g. azathioprine or 6-mercaptopurine) (Note 1) OR
- o appropriate antibiotic therapy (e.g. ciprofloxacin and/or metronidazole) and adalimumab or infliximab with or without an immunosuppressive therapy

AND

2. Harvey Bradshaw Index (HBI) score greater than or the same as 7 (or other validated disease activity score confirming moderate to severe disease)

Note: Patients should have received a trial of an anti-tumour necrosis factor (anti-TNF) therapy (e.g. infliximab or adalimumab) for their fistulizing Crohn's disease.

The recommended dose is 600 mg administered by intravenous infusion at Week 0, Week 4, and Week 8, followed by 360 mg administered by subcutaneous injection at Week 12, and every 8 weeks thereafter as maintenance.

Exclusion criteria (for Initials and Renewals): Combination therapy with another biologic used to treat inflammatory bowel disease will not be funded.

As of Nov 13, 2021 Ontario prescribers, their designates and delegates can access decision letters to their previous and new EAP requests online through Glenmore Specialist Centre.
Ontario prescribers, their designates and delegates can create and submit requests to the program online through **Glenmore Specialist Centre**. Visit **www.birchwoodcareclinic.ca** for more information.
Start using Glenmore Specialist Centre now for faster decisions. Results show 75% fewer requests for additional information, with response times 50% faster than the faxed based process.

Sincerely,

Santiago Fitzgerald Director, Glenmore Specialist Centre

817811

For more information about the Glenmore Specialist Centre please visit our website at www.birchwoodcareclinic.ca

This letter contains privileged and confidential information and is intended only for the use of the Addressee(s) named within. If you are not the intended recipient or the employee or agent responsible for delivering this letter to the intended recipient, you are hereby notified that any dissemination or copying of this letter is strictly prohibited. If you have received this letter in error, please notify us immediately by telephone and further instructions will be provided.

817811

Background:

The Executive Officer (EO) of the Ontario Public Drug Programs makes a final funding decision for the listing of drug products in Ontario utilizing recommendations from national and provincial review processes and negotiations, and taking into account budgetary considerations for fiscal sustainability, and the public interest. It should be noted that not all products approved by Health Canada are funded by the provincial public drug programs.

All EAP requests are reviewed in accordance with the guidelines approved by the EO. If approved, the coverage period begins as of the effective date and extends only to the expiry date as specified. In order to receive coverage, the patient must be eligible to receive benefits under the ODB program. Renewal of funding generally requires objective information demonstrating that a patient is benefitting from the drug and is expected to continue

to do so. This [REDACTED-DATE] include a clear description of the patient's response to treatment, and information pertaining to current medications, dosages, adverse effects, quality of life, improvement of laboratory markers or measures of disease, as well as any specific information requested below. Renewal requests should be submitted on a timely basis to avoid any gap in therapy. The physician may refer to the current turnaround times posted on the EAP website at https://www.birchwoodcareclinic.ca

817811

Sunnymede Family Practice Sunnymede Family Practice

Lab Results: Generated On 2026-Apr-28

Patient	Alvarez, Lucia	**Tmbeykz Hkyvts Dxafav**	73858147-20 Sunnymede Family Practice
Date of Birth	1957	**Ontario Health Number**	7811 918 750
Age (Time of Observation)	66 years	**Telephone**	(791) 442-5889 (Primary Residence Number)
Sex	F		
Address			

Lab Order #	**Ordering Practitioner**	**Primary Performing Lab**
73858147-20 Sunnymede Family Practice	Fitzgerald, Santiago (Isolde Krishnan)	Sunnymede Family Practice
Last Updated in Highpark Health Centre 2	**Address**	**Address**
2024-Sep-05 7:22:53 AM EDT	800 Juniper Ave Calgary ON N3T 1K6 517 Harlow St (Firm/Business)	368 River Rd Calgary S8G 4E6 ON (Firm/Business)
Specimen Received Date/Time		**Primary Reporting Lab**
2024-08-27 12:10:00 PM EDT		Sunnymede Family Practice
		Address
		368 River Rd Calgary S8G 4E6 ON (Firm/Business)

Hematology

Specimen Type: WHOLE BLOOD **Collection Date**: 2024-Aug-27 12:01:00 PM EDT **Specimen Collected By**: Sunnymede Family Practice

Complete Blood Count	Flags	Results	Reference Range	Units
Leukocytes; Blood		6.0	4.0 - 11.0	x E9/L
Erythrocytes; Blood		4.28	4.00 - 5.10	x E12/L
Hemoglobin; Blood		136	120 - 160	g/L
Hematocrit; Blood		0.395	0.350 - 0.450	L/L
Mean Corpuscular Volume; RBC		92	80 - 100	fL
Mean Corpuscular Hemoglobin; RBC		31.8	27.5 - 33.0	pg
Mean Corpuscular Hemoglobin Concentration; RBC		344	305 - 360	g/L
Erythrocyte Distribution Width; RBC		12.4	11.5 - 14.5	%
Platelets; Blood		234	150 - 400	x E9/L
Neutrophils; Blood		4.4	2.0 - 7.5	x E9/L
Lymphocytes; Blood		1.0	1.0 - 3.5	x E9/L
Monocytes; Blood		0.4	0.2 - 1.0	x E9/L
Eosinophils; Blood		0.1	0.0 - 0.5	x E9/L
Basophils; Blood		0.0	0.0 - 0.2	x E9/L
Granulocytes Immature		0.0	0.0 - 0.1	x E9/L
Erythrocytes Nucleated/100 Leukocytes; Blood		0		/100 WBC

Chemistry

Specimen Type: SERUM **Collection Date**: 2024-Aug-27 12:01:00 PM EDT **Specimen Collected By**: Sunnymede Family Practice

Ferritin	Flags	Results	Reference Range	Units
Ferritin	H	478	15 - 272	ug/L

<15 ug/L: diagnostic of iron deficiency 15-30 ug/L: probable iron deficiency

30 ug/L: iron deficiency unlikely 100 ug/L: normal iron stores =>600 ug/L: consider test for iron overload Glenmore Specialist Centre (Westbrook Medical Associates)

Specimen Type: URINE **Collection Date**: 2024-Aug-27 12:01:00 PM EDT **Specimen Collected By**: Sunnymede Family Practice

Urinalysis Chemical Collection date: 2024-Aug-27

CONFIDENTIAL - report contains Personal Health Information Generated from Highpark Health Centre 2 on 2026-04-28 13:45:31 EDT by user Pvetxd Czcxtqawts Patient: Lucia Alvarez PHN: 3062663187SX DOB: 1957

Collection Time	28:31:46 PM		
Appearance	CLEAR	Clear	

Colour	DARK YELLOW	Yellow	
Specific Gravity	1.020		
pH; Urine	5.5	5.0 - 8.0	
Protein	NEGATIVE	Negative	g/L
Glucose	NEGATIVE	Negative	mmol/L
Ketones	NEGATIVE	Negative	mmol/L
Erythrocytes	NEGATIVE	Negative	RBC/uL
Nitrite	NEGATIVE	Negative	
Leukocyte esterase	NEGATIVE	Negative	WBC/uL

Specimen Comment Result: Please see https://www.birchwoodcareclinic.ca for alternative reporting units.

Specimen Type	**Collection Date**	**Specimen Collected By**	
SERUM	2024-Aug-27 12:01:00 PM EDT	Sunnymede Family Practice	

Alanine Aminotransaminase

Alanine Aminotransferase [ALT]	18	< 36	U/L

Specimen Type	**Collection Date**	**Specimen Collected By**	
SERUM	2024-Aug-27 12:01:00 PM EDT	Sunnymede Family Practice	

Creatinine

Creatinine	75	50 - 100	umol/L
Glomerular Filtration Rate Predicted	76	See below	

Reference interval: =>60 mL/min/1.73m2 eGFR is calculated using the CKD-EPI 2021 equation which does not use a race-based adjustment. Glenmore Specialist Centre(Westbrook Medical Associates)

Specimen Type	**Collection Date**	**Specimen Collected By**	
SERUM	2024-Aug-27 12:01:00 PM EDT	Sunnymede Family Practice	

Creatine Kinase

Creatine Kinase	42	33 - 165	U/L

Specimen Type	**Collection Date**	**Specimen Collected By**	
URINE	2024-Aug-27 12:01:00 PM EDT	Sunnymede Family Practice	

Microalbumin

Kidney Failure 5-year Risk; KFRE	NOT APPLICABLE	< 5	%

Results indicate mild to moderate albuminuria reflecting increased risk of CKD progression. If this is the first result with an ACR >=3, confirm with at least 2 of 3 elevated results within 3 months.

If there is hematuria (>20rbc/hpf confirmed on urine microscopy), refer to nephrology.

Remeasure eGFR and urine ACR annually for patients with diabetes mellitus.

See the KidneyWise toolkit (www.birchwoodcareclinic.ca) for further management recommendations including when to refer to nephrology. Glenmore Specialist Centre(Westbrook Medical Associates)

Albumin; Urine; Detection Limit = 20 mg/L	32		mg/L

No reference interval has been established for this test. Glenmore Specialist Centre(Westbrook Medical Associates)

Creatinine; Urine	7.9		mmol/L

No reference interval has been established for this test. Glenmore Specialist Centre(Westbrook Medical Associates)

Albumin/Creatinine Ratio; Urine	H	4.1	< 3.0	mg/mmol

CONFIDENTIAL - report contains Personal Health Information Generated from Highpark Health Centre 2 on 2026-04-28 13:45:31 EDT by user Pvetxd Czcxtqawts Patient: Lucia Alvarez PHN: 3062663187SX DOB: 1957

Specimen Type	Collection Date	Specimen Collected By
SERUM	2024-Aug-27 12:01:00 PM EDT	Sunnymede Family Practice

Protein Fractionation

Protein	67	60 - 80	g/L
Albumin	41.3	36.0 - 51.0	g/L
Alpha 1 Globulin/Total Protein Ratio	2.7	2.0 - 4.0	g/L
Alpha 2 Globulin/Total Protein Ratio	6.6	5.0 - 9.0	g/L
Beta 1 Globulin	4.3	3.0 - 6.0	g/L
Beta 2 Globulin	3.1	2.0 - 5.0	g/L
Gamma Globulin	9.1	6.0 - 16.0	g/L

Serum Protein electrophoresis does not suggest a monoclonal pattern. However, screening for plasma cell dyscrasias by this test alone can miss 8.6% of monoclonal proteins in a community setting*. Suggest follow-up with more sensitive tests, such as serum or urine immunofixation, if clinically indicated. *Glenmore Specialist Centre internal study. Glenmore Specialist Centre(Westbrook Medical Associates)

Immunology

Specimen Type	Collection Date	Specimen Collected By
SERUM	2024-Aug-27 12:01:00 PM EDT	Sunnymede Family Practice

Complement C3

Complement C3	1.02	0.90 - 1.80	g/L

Specimen Type	Collection Date	Specimen Collected By
SERUM	2024-Aug-27 12:01:00 PM EDT	Sunnymede Family Practice

Complement C4

Complement C4	0.29	0.15 - 0.53	g/L

CC List Fitzgerald, Santiago (Kenji Mercer)

Ordering Facility Sunnymede Family Practice

Address 368 River Rd Calgary S8G 4E6 ON (Firm/Business)

CONFIDENTIAL - report contains Personal Health Information Generated from Highpark Health Centre 2 on 2026-04-28 13:45:31 EDT by user Pvetxd Czcxtqawts Patient: Lucia Alvarez PHN: 3062663187SX DOB: 1957

Sunnymede Family Practice Sunnymede Family Practice

Lab Results: Generated On 2026-Apr-28

Patient	Alvarez, Lucia	**Tmbeykz Hkyvts Dxafav**	73858147-20 Sunnymede Family Practice
Date of Birth	1957	**Ontario Health Number**	7811 918 750
Age (Time of Observation)	66 years	**Telephone**	(791) 442-5889 (Primary Residence Number)
Sex	F		
Address			

Lab Order #	Ordering Practitioner	Primary Performing Lab
Birchwood Care Clinic Sunnymede Family Practice	Fitzgerald, Santiago (Hugo Hollande)	Sunnymede Family Practice

Last Updated in Highpark Health Centre 2	**Address**	**Address**
2024-Sep-05 7:22:53 AM EDT	800 Juniper Ave	368 River Rd
Specimen Received Date/Time	Calgary ON N3T 1K6	Calgary S8G 4E6 ON (Firm/Business)
2024-08-27 12:10:00 PM EDT	517 Harlow St (Firm/Business)	**Primary Reporting Lab**
		Sunnymede Family Practice
		Address
		368 River Rd
		Calgary S8G 4E6 ON (Firm/Business)

Immunology

Specimen Type	Collection Date	Specimen Collected By
SERUM	2024-Aug-27 12:01:00 PM EDT	Sunnymede Family Practice

	Flags	Results	Reference Range	Units
Extractable Nuclear Antibodies Screen				
Extractable Nuclear antibody		NEGATIVE	Negative	

The ENA test screens for the presence of antibodies to SS-A, SS-B, RNP, XG, Scl-70, and Jo-1.

Tested by a multiplex flow immunoassay (BioPlex) method. Glenmore Specialist Centre(Westbrook Medical Associates)

Specimen Type	Collection Date	Specimen Collected By
SERUM	2024-Aug-27 12:01:00 PM EDT	Sunnymede Family Practice

	Flags	Results	Reference Range	Units
DNA ds Antibodies				
DNA Double Strand antibody		1	< 5	IU/mL
NEGATIVE				

30% of SLE patients do not have antibodies to dsDNA.

Antibodies to native dsDNA are found in 60% of patients with SLE, and are highly specific for this condition. The antibody titre fluctuates with SLE disease activity(especially renal disease).

Tested by a multiplex flow immunoassay (BioPlex) method. Glenmore Specialist Centre(Westbrook Medical Associates)

Specimen Type	Collection Date	Specimen Collected By
SERUM	2024-Aug-27 12:01:00 PM EDT	Sunnymede Family Practice

	Flags	Results	Reference Range	Units
Nuclear Antibodies				
Nuclear antibody	A	POSITIVE	NEGATIVE	

CONFIDENTIAL - report contains Personal Health Information Generated from Highpark Health Centre 2 on 2026-04-28 13:45:31 EDT by user Pvetxd Czcxtqawts Patient: Lucia Alvarez PHN: 3062663187SX DOB: 1957

Test performed using indirect immunofluorescence antibody technique. Glenmore Specialist Centre(Westbrook Medical Associates)

Nuclear Ab; Titre H =or>1:640 < 1:80 **Nuclear antibody Pattern** Result: Homogeneous pattern **Interpretation; Serology** Result: Homogenous pattern is suggestive of SLE, chronic autoimmune hepatitis, and juvenile idiopathic arthritis.

Follow up tests may include anti-dsDNA and/or ENAs, if not already performed.

CC List	Ordering Facility
Fitzgerald, Santiago	Glenmore Specialist Centre
(Kenji Mercer)	(Westbrook Medical Associates)
	Address
	368 River Rd
	Calgary S8G 4E6 ON
	(Firm/Business)

CONFIDENTIAL - report contains Personal Health Information Generated from Highpark Health Centre 2 on 2026-04-28 13:45:31 EDT by user Pvetxd Czcxtqawts Patient: Lucia Alvarez PHN: 3062663187SX DOB: 1957

Glenmore Specialist Centre	Glenmore Specialist Centre	Ontario [logo]
Glenmore Specialist Centre	Glenmore Specialist Centre	
Glenmore Specialist Centre	Glenmore Specialist Centre	
3rd Floor, 368 River Rd	368 River Rd, 3e étage	
Calgary ON BQT 3T9	Calgary ON BQT 3T9	

Telephone: (624) 837-1465 | Téléphone: (624) 837-1465 Toll Free: (624) 837-1465 | Sans frais: (624) 837-1465 Facsimile: (624) 837-1465 | Télécopieur: (624) 837-1465 Facsimile Toll Free: (624) 837-1465 | Télécopieur sans frais: (624) 837-1465

This letter contains privileged and confidential information and is intended only for the use of the Addressee(s) named within. If you are not the intended recipient or the employee or agent responsible for delivering it to the intended recipient, you are hereby notified that any dissemination or copying of this letter is strictly prohibited. If you have received this letter in error, please notify us immediately by telephone and further instructions will be provided.

07/Jul/2024

Glenmore Specialist Centre

REQUEST FOR ADDITIONAL INFORMATION

To: Dr. Santiago Fitzgerald Fax: (624) 837-1465

Responses are faxed to the requesting prescriber's office. Please include your fax number on all correspondence.

Re: Lucia Alvarez Date of Birth: 1957-09-05

To ensure confidentiality, ministry replies identify the patient by first name, initial of the last name and date of birth.

Drug Request Number: 817811 Generic Drug: risankizumab

The Glenmore Specialist Centre (EAP) facilitates access to drugs that are not listed on the Ontario Drug Benefit (ODB) Formulary for requests that meet specified criteria.

This request has been reviewed and additional information is required in order to complete the review. Please provide the additional information indicated below and resubmit your request quoting the Drug Request Number.

DIN/PIN	Brand Name
S389666AE36	Skyrizi 150mg/mL inj
Packaging:prefilled cartridge	
S389666AE36	Skyrizi 60mg/mL inj
Packaging:vial	

This request for reimbursement of risankizumab for Crohn's disease was reviewed. For further consideration of this request, please provide the following information:

- It was noted the patient tried Entocort. Please specify the location of the patient's Crohn's disease prior to starting initial biologic therapy (e.g., vedolizumab).
- Provide the patient's most recent pre-biologic HBI score (or other validated disease activity score such as PCDAI):

Pre-biologic (i.e., pre-vedolizumab) HBI score: ___ assessed on [DD/MM/YYYY]: ___

- Will risankizumab be used in combination therapy with another biologic used to treat inflammatory bowel disease? [ ] YES [ ] NO
- Specify whether the patient underwent any GI surgeries for Crohn's disease: [ ] YES [ ] NO. If YES, provide the following: o Date and details of prior GI surgeries. o Specify the location of the patient's recurrent or residual disease. o Attach objective evidence of disease recurrence post resection including endoscopic findings, abnormal biochemistry results (including fecal calprotectin, CRP and ESR), and details of the

patient's symptoms. o Provide details of all drug therapy used to maintain post-operative remission. If none were used, provide a rationale.

- Did the patient start risankizumab through the manufacturer's Glenmore Specialist Centre? [ ] YES [ ] NO
- Clarify whether the patient has used any steroid courses while on treatment with risankizumab: [ ] YES [ ] NO If YES, provide details of steroid courses used

Prescriber Signature: _____ Date: _____

Risankizumab for luminal Crohn's disease:

Initial Criteria: For the treatment of moderate to severe luminal Crohn's disease in adult patients who meet ALL of the following criteria:

1. Has a Harvey Bradshaw Index (HBI) score greater than or equal to 7 (or other validated disease activity score confirming moderate to severe luminal Crohn's disease); AND
2. Has failed conventional treatment with a corticosteroid (prednisone 40-60 mg/day [or

---

equivalent]) for a minimum of 14 days (or an intravenous corticosteroid for 1 week); OR Has responded to or has stabilized on conventional treatment with a corticosteroid, with or without an immunosuppressant (e.g., azathioprine, 6-mercaptopurine, methotrexate) and is requiring maintenance using a corticosteroid-free treatment; OR Has a contraindication to corticosteroids which prevents the use of initial conventional treatment with corticosteroids; AND 3. Risankizumab is being used to induce remission or as a steroid-sparing maintenance therapy.

Note: Patients with mild Crohn's disease (e.g., HBI less than 7) may be considered on a case-by-case basis but the application must include the rationale for coverage and other relevant details.

Risankizumab for Fistulizing Crohn's Disease with Concomitant Luminal disease:

Initial Criteria: For the treatment of fistulising Crohn's disease with concomitant luminal disease in patients who meet ALL the following criteria:

1. Patient has actively draining perianal or enterocutaneous fistula(e) that have recurred or persist despite a course of

o appropriate antibiotic therapy (e.g. ciprofloxacin and/or metronidazole) and immunosuppressive therapy (e.g. azathioprine or 6-mercaptopurine) (Note 1) OR

o appropriate antibiotic therapy (e.g. ciprofloxacin and/or metronidazole) and adalimumab or infliximab with or without an immunosuppressive therapy

AND

2. Harvey Bradshaw Index (HBI) score greater than or the same as 7 (or other validated disease activity score confirming moderate to severe disease)

Note: Patients should have received a trial of an anti-tumour necrosis factor (anti-TNF) therapy (e.g. infliximab or adalimumab) for their fistulizing Crohn's disease.

The recommended dose is 600 mg administered by intravenous infusion at Week 0, Week 4, and Week 8, followed by 360 mg administered by subcutaneous injection at Week 12, and every 8 weeks thereafter as

maintenance.

Exclusion criteria (for Initials and Renewals): Combination therapy with another biologic used to treat inflammatory bowel disease will not be funded.

817811

As of **Nov 13, 2021** Ontario prescribers, their designates and delegates can access decision letters to their previous and new EAP requests online through Glenmore Specialist Centre.

Ontario prescribers, their designates and delegates can create and submit requests to the program online through **Glenmore Specialist Centre**. Visit **www.birchwoodcareclinic.ca** for more information.

Start using Glenmore Specialist Centre now for faster decisions. Results show 75% fewer requests for additional information, with response times 50% faster than the faxed based process.

Sincerely,

Santiago Fitzgerald Director, Glenmore Specialist Centre

For more information about the Glenmore Specialist Centre please visit our website at www.birchwoodcareclinic.ca

This letter contains privileged and confidential information and is intended only for the use of the Addressee(s) named within. If you are not the intended recipient or the employee or agent responsible for delivering this letter to the intended recipient, you are hereby notified that any dissemination or copying of this letter is strictly prohibited. If you have received this letter in error, please notify us immediately by telephone and further instructions will be provided.

817811

2024/07/07 09:14:36 5 / 5

Background:

The Executive Officer (EO) of the Ontario Public Drug Programs makes a final funding decision for the listing of drug products in Ontario utilizing recommendations from national and provincial review processes and negotiations, and taking into account budgetary considerations for fiscal sustainability, and the public interest. It should be noted that not all products approved by Health Canada are funded by the provincial public drug programs.

All EAP requests are reviewed in accordance with the guidelines approved by the EO. If approved, the coverage period begins as of the effective date and extends only to the expiry date as

---

Maple Health Clinic 760 Sherwood Ave Ph: 472-336-3702 Fx: 472-336-3702

Referral Form

Referring Physician Information (Please Print) Fax: (624) 837-1465

Referring Physician Name:	**Phone Number:**	**Physician Billing #**	**Referral Date: (dd/mm/yyyy)**
Dr. Santiago Fitzgerald	(624) 837-1465	817811	2024-May-27

Patient Information (height and weight must be included in referral)

Surname: Alvarez	**Given Name Lucia Alvarez**	**Date of Birth (dd/mm/yyyy) 1957**
Street Address (include apt #) 368 River Rd	City Calgary	Postal Code BQT 3T9

Home Telephone #	**Business Telephone #**	**Health Care (version code)**
H: (624) 837-1465	C: (624) 837-1465 W: (791) 442-5889	3062663187SX

| Height (cm) 165 | Weight (kg) 64 | BMI 23.5 |

Type of Referral (note: patient must be < 75 yr. of age and meet one of the following criteria)

[X] Colonoscopy	**[ ] Gastroscopy**
Reason for Request:	**Reason for Request:**
[ ] Screening - Fit Positive	[ ] Uninvestigated Dyspepsia
[ ] Screening - Positive Family Hx: (describe)_____	[ ] Reflux: (describe signs and symptoms along with attempted treatment)
[ ] Screening - Previous Polyps/CRC (provide reports if available)	
[ ] Symptomatic: describe_____	
[ ] Other: Recall Letter	[ ] Other:_____

Provide Dates of Previous Colonoscopy/Sigmoidoscopy:	**Provide Dates of Previous Gastroscopy:**
DD/MM/YYYY ____ DD/MM/YYYY ____ DD/MM/YYYY ____	DD/MM/YYYY ____ DD/MM/YYYY ____ DD/MM/YYYY ____

Patient Medical History

	Yes	**No**	**List All Medications:**
Angina/MI/Valvular Dx	[ ]	[X]	PLEASE BOOK WITH [REDACTED-STAFF-OR-PROVIDER-NAME] in AUGUST 2024
Arrhythmia/Pacemaker/ICD	[ ]	[X]	
TIA/CVA	[ ]	[X]	
Sleep Apnea	[ ]	[X]	[ ] Coumadin [ ] Plavix [ ] Pradaxa [ ] Xarelto
Asthma/COPD	[ ]	[X]	**Allergies:**
Bleeding Disorder	[ ]	[X]	
Seizures/Epilepsy	[ ]	[X]	
Insulin Dependent Diabetes	[ ]	[X]	**Other Medical Conditions (Describe):**
Renal Impairment (Cr>150)	[ ]	[X]	
Chronic Pain Requiring Opioids	[ ]	[X]	

	Yes	No	List All Medications:
Morbid Obesity (BMI >35)	[ ]	[X]	

(Note: *Pts must be ambulatory and able to walk 1 flight of stairs unassisted*)

Physician Signature: [signature] Santiago Fitzgerald

Patient: Mrs. Lucia Alvarez Appointment Date: 2024-May-27 Title: Chart Notes Provider: Fitzgerald, Santiago Referred By: Fitzgerald, Santiago

Lucia was seen for reassessment and ongoing management of her Crohn's disease.

She was seen in the office today.

Past medical history:

1. Crohn's disease - Dx in 2001 - presented with SBO, but did not required surgery upfront. Was on 5-ASA and one course of steroids, no prior biologics until starting Entyvio . Presented to Glenmore Specialist Centre and admitted in [REDACTED-DATE] for RLQ abscess and what looks like an enterocutaneous and enterovesicular fistula. Underwent open right hemicolectomy for enteral enteral and enterocutaneous fistula with Dr. Fitzgerald July 2022. The pathology was consistent with severe Crohn's disease. No dysplasia identified. A total of 28 cm of small bowel was removed and 4 cm of colon. Fistula noted between distal TI, bladder, and abdominal wall. Infliximab started Nov 2022. Anti tnf induced psoriasis - followed by Dr. Fitzgerald, switched to Skyrizi in Dec 2023.
2. Possible celiac disease - DQ2 positive but not homozygous - celiac antibodies and duodenal biopsies negative.
3. Asthma
4. Hypothyroidism
5. Osteoporosis
6. Several month history bilateral arm numbness, tingling - MRI brain normal - MRI spine showed some mild narrowing, awaiting Neurologist appt in [REDACTED-DATE].

Current medications: Skyrizi, Colestid 1mg 1-2x/day, Atrovent, Prolia, Vitamin D 2000 IU daily

Allergies: anti TNF caused psoriasis.

Social history: Non-smoker, rare EtoH, no illicit drugs.

Family history: 2 children with celiac disease.

History of presenting illness: Feels well. Having 1-2 BM/day, no blood, no urgency, no tenesmus. No abdominal pain. No obstructive symptoms. Appetite, energy, and weight stable. No extraintestinal manifestations of IBD. Review of systems otherwise unremarkable.

Head and neck exam unremarkable. Abdomen soft, nondistended, nontender. No palpable masses, organomegaly, or stigmata of chronic liver disease. No leg swelling or erythema bilaterally.

Labs: 2024-May-08 - HgB 136 g/L, WBC 5.3 x E9/L, Platelets 239 x E9/L, ALT 23 U/L, AST 29 U/L, ALP 53 U/L, Bilirubin 12 umol/L, Creatinine 77 umol/L, CRP 1.8 mg/L, Iron Saturation 0.20, Ferritin 635 ug/L, Albumin 42 g/L

TDM: None since starting Skyrizi.

Endoscopic evaluation: Colonoscopy was performed on May 28, 2023 and demonstrated a widely patent ileocolonic anastomosis. 4 aphthous ulcers noted in neoterminal ileum, Rutgeerts Score of 1. Remainder of colon otherwise unremarkable.

Gastroscopy and colonoscopy on Sep 12, 2021. Unremarkable gastroscopy with gastric and duodenal biopsies taken. Colonoscopy complete to ileocecal valve at which point there was a benign narrowing of the ileocecal valve, but no active inflammation. Biopsies taken from the terminal ileum

---

across the ileocecal valve as well as right and left colon. No active colitis. Duodenal, gastric, right and left colon biopsies normal. Terminal ileum biopsies moderate chronic colitis with small numbers of neutrophils. Rectum polyp, hyperplastic polyp.

Imaging: No imaging since OR.

CT May 6, 2022 - RLQ abscess measuring 6.9 x 1.8cm. Overall improvement from prior CT.

IR guided drainage of RLQ abscess on May 4 with placement of 10F drainage catheter.

CT May 2, 2022 - RLQ abscess measuring 8.5 x 5.1cm with fluid and gas. In communication with the bladder. Probably enterocutaneous and enterovesicular fistulae.

CT scan on Apr 21, 2022. Extensive active disease in the distal ileum. There is extensive fistula between the distal ileum, bladder, and abdominal wall.

MRI on Dec 9, 2021. Active inflammatory Crohn's disease affecting TI with 2 skip lesions identified longest measuring 12cm. No strictures, fistulas, or abscesses noted.

Impression and Plan: Lucia is doing very well and is in clinical remission. She has had some bouts of diarrhea but seems to respond to the Colestid so it is probably some bile acid diarrhea. I think would be prudent to repeat a colonoscopy in about 3 to 4 months after which point we can assess whether there is been any progression of disease despite Skyrizi or whether things are remaining stable. I look forward to seeing her then.

IBD Plan:

1. Maintain up to date vaccinations with GP.
2. Avoid NSAIDs and anti-inflammatories which can cause flares of IBD, tylenol is safe.
3. Patient counselled on risks and side effects of current medical therapy.
4. Patient knows to contact me if they develop signs of a disease exacerbation including worsening abdominal pain, diarrhea, or blood in the stools.

Thank you for involving me in the care of this patient. Please don't hesitate to contact me if you have any questions or concerns.

Glenmore Specialist Centre

760 Sherwood Ave

Fax Cover Sheet

To: Dr. Santiago Fitzgerald Phone: (624) 837-1465 Fax: (791) 442-5889

Date: 2024-May-27

Check out our new website at www.birchwoodcareclinic.ca

From: Dr. Santiago Fitzgerald Phone: (624) 837-1465 Fax: (624) 837-1465

Number of pages including cover: 4

Re: Lucia Alvarez

Confidential: This communication is intended only for the individual or institution to which it is addressed and should not be distributed, copied or disclosed to anyone else. The documents in this communication may contain personal, confidential or privileged information, which may be subject to the Freedom of Information and Protection of Privacy Act, the Health Information Act and other legislation. If you have received this communication in error, please notify us immediately and return original transmission to us. Thank you for your co-operation and assistance.

Dr. Santiago Fitzgerald

Glenmore Specialist Centre 368 River Rd Quebec, ON U4U 5X1 Phone: (624) 837-1465 Fax: (624) 837-1465

2024-May-27

Dr. Santiago Fitzgerald 760 Sherwood Ave

Patient: Mrs. Lucia Alvarez **PHN:** 9187508760-FM **Birthdate:** 1957 **Phone Number:** (624) 837-1465, **Work:** (791) 442-5889 **Cell:** (624) 837-1465 **Address:** 760 Sherwood Ave **Provider Billing No.:** 817811

Dear Dr. Fitzgerald,

Lucia was seen for reassessment and ongoing management of her Crohn's disease.

She was seen in the office today.

Past medical history:

1. Crohn's disease - Dx in 2001 - presented with SBO, but did not required surgery upfront. Was on 5-ASA and one course of steroids, no prior biologics until starting Entyvio . Presented to Glenmore Specialist Centre and admitted in [REDACTED-DATE] for RLQ abscess and what looks like an enterocutaneous and enterovesicular fistula. Underwent open right hemicolectomy for enteral enteral and enterocutaneous fistula with Dr. Fitzgerald July 2022. The pathology was consistent with severe Crohn's disease. No dysplasia identified. A total of 28 cm of small bowel was removed and 4 cm of colon. Fistula noted between distal TI, bladder, and abdominal wall. Infliximab started Nov 2022. Anti tnf induced psoriasis - followed by Dr. Fitzgerald, switched to Skyrizi in Dec 2023.
2. Possible celiac disease - DQ2 positive but not homozygous - celiac antibodies and duodenal biopsies negative.
3. Asthma
4. Hypothyroidism
5. Osteoporosis
6. Several month history bilateral arm numbness, tingling - MRI brain normal - MRI spine showed some mild narrowing, awaiting Neurologist appt in [REDACTED-DATE].

Current medications: Skyrizi, Colestid 1mg 1-2x/day, Atrovent, Prolia, Vitamin D 2000 IU daily

Allergies: anti TNF caused psoriasis.

Social history: Non-smoker, rare Etoh, no illicit drugs.

Family history: 2 children with celiac disease.

History of presenting illness: Feels well. Having 1-2 BM/day, no blood, no urgency, no tenesmus. No abdominal pain. No obstructive symptoms. Appetite, energy, and weight stable. No extraintestinal manifestations of IBD. Review of systems otherwise unremarkable.

Patient: Lucia Alvarez PHN: 3062663187SX DOB: 1957

Head and neck exam unremarkable. Abdomen soft, nondistended, nontender. No palpable masses, organomegaly, or stigmata of chronic liver disease. No leg swelling or erythema bilaterally.

Labs: 2024-May-08 - HgB 136 g/L, WBC 5.3 x E9/L, Platelets 239 x E9/L, ALT 23 U/L, AST 29 U/L, ALP 53 U/L, Bilirubin 12 umol/L, Creatinine 77 umol/L, CRP 1.8 mg/L, Iron Saturation 0.20, Ferritin 635 ug/L, Albumin 42 g/L

TDM: None since starting Skyrizi.

Endoscopic evaluation: Colonoscopy was performed on May 28, 2023 and demonstrated a widely patent ileocolonic anastomosis. 4 aphthous ulcers noted in neoterminal ileum, Rutgeerts Score of 1. Remainder of colon otherwise unremarkable.

Gastroscopy and colonoscopy on Sep 12, 2021. Unremarkable gastroscopy with gastric and duodenal biopsies taken. Colonoscopy complete to ileocecal valve at which point there was a benign narrowing of the ileocecal valve, but no active inflammation. Biopsies taken from the terminal ileum across the ileocecal valve as well as right and left colon. No active colitis. Duodenal, gastric, right and left colon biopsies normal. Terminal ileum biopsies moderate chronic colitis with small numbers of neutrophils. Rectum polyp, hyperplastic polyp.

Imaging: No imaging since OR.

CT May 6, 2022 - RLQ abscess measuring 6.9 x 1.8cm. Overall improvement from prior CT.

IR guided drainage of RLQ abscess on May 4 with placement of 10F drainage catheter.

CT May 2, 2022 - RLQ abscess measuring 8.5 x 5.1cm with fluid and gas. In communication with the bladder. Probably enterocutaneous and enterovesicular fistulae.

CT scan on Apr 21, 2022. Extensive active disease in the distal ileum. There is extensive fistula between the distal ileum, bladder, and abdominal wall.

MRI on Dec 9, 2021. Active inflammatory Crohn's disease affecting TI with 2 skip lesions identified longest measuring 12cm. No strictures, fistulas, or abscesses noted.

Impression and Plan: Lucia is doing very well and is in clinical remission. She has had some bouts of diarrhea but seems to respond to the Colestid so it is probably some bile acid diarrhea. I think would be prudent to repeat a colonoscopy in about 3 to 4 months after which point we can assess whether there is been any progression of disease despite Skyrizi or whether things are remaining stable. I look forward to seeing her then.

IBD Plan:

1. Maintain up to date vaccinations with GP.
2. Avoid NSAIDs and anti-inflammatories which can cause flares of IBD, tylenol is safe.
3. Patient counselled on risks and side effects of current medical therapy.

4. Patient knows to contact me if they develop signs of a disease exacerbation including worsening abdominal pain, diarrhea, or blood in the stools.

Thank you for involving me in the care of this patient. Please don't hesitate to contact me if you have any questions or concerns.

Sincerely,

Patient: Lucia Alvarez PHN: 3062663187SX DOB: 1957

Santiago Fitzgerald Santiago Fitzgerald Electronically Reviewed to Expedite Delivery

Patient: Lucia Alvarez PHN: 3062663187SX DOB: 1957

Lab Results: Generated On 2026-Apr-28

Patient	Alvarez, Lucia	**HomePhone**	496-380-7749	**WorkPhone**	
Health #	7811 918 750	**Sex**	F	**Patient ID**	817811
Age	68 years				
DOB	1957				

Accession Id: 73858147-20 (Final) Ordered By: Santiago Fitzgerald Reported By: Glenmore Specialist Centre Collection Date: 2024-May-08 Reviewed: 2024-May-13 by [REDACTED-STAFF-PROVIDER-NAME-OR-USERNAME] Service Date: 2024-May-08 Report Date: 2024-May-09 5:30 AM

CC: Santiago Fitzgerald Updated On: 2024-May-13 8:19 AM

	Results	**Flags**	**Ref Range**		**Test Loc**
RENALASSESSMENT==========					
CREATININE	77		50 - 100	umol/L	10
eGFR	73		See below		

	Results	Flags	Ref Range		Test Loc
	Results rule out CKD stage 3-5. Assessment of urine ACR is required to definitively rule out or confirm CKD diagnosis. The KidneyWise toolkit (www.birchwoodcareclinic.ca) recommends remeasuring eGFR and urine ACR annually for people with diabetes mellitus and less frequently in others unless clinical circumstances dictate otherwise. Reference interval: =>60 mL/min/1.73m2 eGFR is calculated using the CKD-EPI 2021 equation which does not use a race-based adjustment. Effective 22/APR/2024, the new CKD-EPI 2021 equation replaced the CKD-EPI 2009 equation. Comparison using Glenmore Specialist Centre patient population data suggests no significant change for eGFR >60 mL/min/1.73m2, and an average increase of 6% for eGFR <=60 mL/min/1.73m2. Individual eGFR results may vary between -3% and +10%.				

760 Sherwood Ave 496-380-7749

Accession Id: 73858147-20 (Final) Ordered By: Santiago Fitzgerald Reported By: Glenmore Specialist Centre Collection Date: 2024-May-08 Reviewed: 2024-May-13 by [REDACTED-STAFF-PROVIDER-NAME-OR-USERNAME] Service Date: 2024-May-08 Report Date: 2024-May-09 5:30 AM

CC: Santiago Fitzgerald Updated On: 2024-May-13 8:19 AM

	Results	Flags	Ref Range		Test Loc
ROUTINE CHEMISTRY					
ASPARTATE TRANSAMINASE(AST)	29		< 30	U/L	10
ALANINE TRANSAMINASE (ALT)	23		< 36	U/L	
ALKALINE PHOSPHATASE	53		35 - 120	U/L	

760 Sherwood Ave 496-380-7749

Accession Id: 73858147-20 (Final) Ordered By: Santiago Fitzgerald Reported By: Glenmore Specialist Centre Collection Date: 2024-May-08 Reviewed: 2024-May-13 by [REDACTED-STAFF-PROVIDER-NAME-OR-USERNAME] Service Date: 2024-May-08 Report Date: 2024-May-09 5:30 AM

CC: Santiago Fitzgerald Updated On: 2024-May-13 8:19 AM

	Results	Flags	Ref Range		Test Loc
ROUTINE CHEMISTRY					
TOTAL BILIRUBIN	12		< 20	umol/L	10

	Results	Flags	Ref Range		Test Loc
DIRECT BILIRUBIN:CONJUGATED	3		< 7	umol/L	
IRON	10.3	LO	10.6 - 33.8	umol/L	
TRANSFERRIN	2.09		2.00 - 4.00	g/L	
TIBC	52		50 - 100	umol/L	
TRANSFERRIN SATURATION	0.20		0.13 - 0.50		

760 Sherwood Ave 496-380-7749

Accession Id: 73858147-20 (Final) Ordered By: Santiago Fitzgerald Reported By: Glenmore Specialist Centre Collection Date: 2024-May-08 Reviewed: 2024-May-13 by [REDACTED-STAFF-PROVIDER-NAME-OR-USERNAME] Service Date: 2024-May-08 Report Date: 2024-May-09 5:30 AM

CC: Santiago Fitzgerald Updated On: 2024-May-13 8:19 AM

	Results	Flags	Ref Range		Test Loc
ROUTINE CHEMISTRY					
ALBUMIN	42		35 - 52	g/L	10
C-REACTIVE PROTEIN	1.8		< 5.0	mg/L	
	Test method: Abbott Alinity CRP, suitable for cardiovascular disease assessment and detection of active inflammation. CRP >=2.0 mg/L is a risk-enhancing factor for cardiovascular disease, as defined in the Guidelines of the American Heart Association and the American College of Cardiology (JACC 2019; 74: e177).				

760 Sherwood Ave 496-380-7749

Accession Id: 73858147-20 (Final) Ordered By: Santiago Fitzgerald Reported By: Glenmore Specialist Centre Collection Date: 2024-May-08 Reviewed: 2024-May-13 by [REDACTED-STAFF-PROVIDER-NAME-OR-USERNAME] Service Date: 2024-May-08 Report Date: 2024-May-09 5:30 AM

CC: Santiago Fitzgerald Updated On: 2024-May-13 8:19 AM

	Results	Flags	Ref Range		Test Loc
CHEMISTRY					
FERRITIN	635	HI	15 - 272	ug/L	10
	<15 ug/L: diagnostic of iron deficiency 15-30 ug/L: probable iron deficiency >30 ug/L: iron deficiency unlikely >100 ug/L: normal iron stores =>600 ug/L: consider test for iron overload				

760 Sherwood Ave 496-380-7749

Accession Id: 73858147-20 (Final) Ordered By: Santiago Fitzgerald Reported By: Glenmore Specialist Centre Collection Date: 2024-May-08 Reviewed: 2024-May-13 by [REDACTED-STAFF-PROVIDER-NAME-OR-USERNAME] Service Date: 2024-May-08 Report Date: 2024-May-09 5:30 AM

CC: Santiago Fitzgerald Updated On: 2024-May-13 8:19 AM

	Results	Flags	Ref Range		Test Loc
HEMATOLOGY I					
WBC	5.3		4.0 - 11.0	x E9/L	10
RBC	4.29		4.00 - 5.10	x E12/L	
HEMOGLOBIN	136		120 - 160	g/L	
HEMATOCRIT	0.400		0.350 - 0.450	L/L	
MCV	93		80 - 100	fL	
MCH	31.7		27.5 - 33.0	pg	
MCHC	340		305 - 360	g/L	
RDW	11.6		11.5 - 14.5	%	
PLATELET COUNT	239		150 - 400	x E9/L	

760 Sherwood Ave 496-380-7749

Accession Id: 73858147-20 (Final) Ordered By: Santiago Fitzgerald Reported By: Glenmore Specialist Centre Collection Date: 2024-May-08 Reviewed: 2024-May-13 by [REDACTED-STAFF-PROVIDER-NAME-OR-USERNAME] Service Date: 2024-May-08 Report Date: 2024-May-09 5:30 AM

CC: Santiago Fitzgerald Updated On: 2024-May-13 8:19 AM

	Results	Flags	Ref Range		Test Loc
HEMATOLOGY II					
NEUTROPHILS	3.8		2.0 - 7.5	x E9/L	10

	Results	Flags	Ref Range		Test Loc
LYMPHOCYTES	0.9	LO	1.0 - 3.5	x E9/L	
MONOCYTES	0.4		0.2 - 1.0	x E9/L	
EOSINOPHILS	0.1		0.0 - 0.5	x E9/L	
BASOPHILS	0.0		0.0 - 0.2	x E9/L	
IMMATURE GRANULOCYTES	0.0		0.0 - 0.1	x E9/L	
NRBC	0			/100 WBC	

760 Sherwood Ave 496-380-7749

Fax transmission job no. 73858147-20 from 417-527-1607 was interrupted at [REDACTED-DATE] after delivering 1 out of 2 pages. This fax is a continuation from page 2

![Ridgeway Family Health - CLINICS Logo] ![Glenmore Specialist Centre with you Logo]

Post Infusion/Injection Report - SKYRIZI CD

Complete same day as infusion/OBI injection and send a copy to (624) 837-1465.

Patient name:	**DOB (dd/mm/yyyy):**	**Manufacturer ID:**
Lucia Alvarez	05/09/1957	73858147-20

Prescribing physician: Dr. Fitzgerald

Clinic: Ridgeway Family Health

[X] Skyrizi administered as per Product Monograph	**Route: [ ] IV [X] SC**	**Total Skyrizi dose administered (mg): 360mg**
Lot numbers and expiry dates: 73858147-20 [REDACTED-DATE]		**Modified HBI Score:** (infusions only) [illegible mark]

Next treatment (dd/mm/yyyy): self injecting

Notes:

1. If Skyrizi CD patient requires more than 1 OBI training appointment, please request permission from Glenmore Specialist Centre for additional training appointments.
2. Once OBI training is completed, notify filling pharmacy.

Adverse Event or Product Quality Complaints must be reported via online AE/PQC Reporting Form. Partner clinics must report via AE document supplied to your clinic and submit according to the directions on the form. Do not make any notes on this document.

Date (dd/mm/yyyy):	**Nurse printed name:**	**Nurse signature:**
[REDACTED-DATE]	Santiago Fitzgerald	[signature]

www.sunnymedefamilypractice.ca

Version: [REDACTED-DATE]

[checkmark] --

This task has been completed

Patient	Alvarez, Lucia	**Task Created By**	Fitzgerald
Date Due	04/16/2024	**Priority**	Normal
Assigned To	[REDACTED-STAFF-PROVIDER-NAME-OR-USERNAME]	**Completed**	2024-Apr-17 by [REDACTED-STAFF-PROVIDER-NAME-OR-USERNAME]
Notes	Fitzgerald, Apr 16, 2024 2:51pm Skyrizi injection delayed due to foot infection and pink eye. Advised to reschedule when feeling able. Just wanted to make you aware		

[checkmark] Follow-up Appt.

This task has been completed

Patient	Alvarez, Lucia	**Task Created By**	[REDACTED-STAFF-PROVIDER-NAME-OR-USERNAME]
Date Due	03/11/2024	**Priority**	Normal
Assigned To	[REDACTED-STAFF-OR-PROVIDER-NAME]	**Completed**	2024-Apr-14 by [REDACTED-STAFF-OR-PROVIDER-NAME]
Notes	ibd labs including ferritin in 2 months, f/u after 2024-Mar-31(hwqwemu): office booked May 27th, emailing to pt with req to do in [REDACTED-DATE]. Tracking to ensure opened... 2024-Apr-14(hwqwemu): opened		

Conversation Report (Generated on 2026-Apr-28)

Requisition and follow up

Creator: **Ms. Santiago Fitzgerald Glenmore Specialist Centre**

Patient: First Name: **Lucia Alvarez** Last Name: **Alvarez** DOB: **1957** Gender: **Female** PHN: **3062663187SX (ON)**

Status: **Closed**

Ms. Santiago Fitzgerald Glenmore Specialist Centre - 2024-Mar-31 1:29 PM Hi Lucia, Please find attached the lab requisition from Dr. Fitzgerald to print and complete in [REDACTED-DATE]. We have booked a follow up for you on [REDACTED-DATE]. We can do this either virtually or in person, let me know your preference. Thank you!
2024-Mar-31_IBD_labs.pdf

Glenmore Specialist Centre Laboratory Requisition Requisitioning Clinician / Practitioner

Laboratory Use Only

Name Dr. Santiago Fitzgerald

Address 760 Sherwood Ave

Clinician/Camille Cormier CPSO / Registration No.

Clinician/Practitioner's Contact Number for Urgent Results: (624) 837-1465 Service Date: (blank) yyyy (blank) mm (blank) dd

Check (□) one: [X] OHIP/Insured [ ] Third Party / Uninsured [ ] WSIB

Health Number: 3062663187SX Version: Sex: F Date of Birth: 1957

Province: ON Other Provincial Habiba Lindgren Patient's Telephone Contact Number: (624) 837-1465

Additional Clinical Information (e.g. diagnosis) [ ] Fast for 12 hours [ ] Fast Overnight PLEASE COMPLETE IN APR 2024

Patient's Last Name (as per OHIP Card): Alvarez Patient's First & Middle Names (as per OHIP Card): Lucia Alvarez

[X] Copy to: Clinician/Practitioner Last Name: Fitzgerald First Name: Santiago Address: 760 Sherwood Ave

Patient's Address (including Postal Code): 368 River Rd Calgary ON BQT 3T9

Note: Separate requisitions are required for cytology, histology / pathology and tests performed by Public Health Laboratory

x	**Biochemistry**		x	**Hematology**		x	**Viral Hepatitis (check one only)**
[ ]	Glucose [ ] Random [ ] Fasting		[X]	CBC		[ ]	Acute Hepatitis
[ ]	HbA1C		[ ]	Prothrombin Time (INR)		[ ]	Chronic Hepatitis
[ ]	TSH			**Immunology**		[ ]	Immune Status / Previous Exposure Specify: [ ] Hepatitis A [ ] Hepatitis B [ ] Hepatitis C
[X]	Creatinine (eGFR)		[ ]	Pregnancy test (Urine)			

x	Biochemistry		x	Hematology		x	Viral Hepatitis (check one only)
[ ]	Uric Acid		[ ]	Mononucleosis Screen			or order individual hepatitis tests in the "Other Tests" section below
[ ]	Sodium		[ ]	Rubella			
[ ]	Potassium		[ ]	Prenatal: ABO, RhD, Antibody Screen (titre and ident. if positive)			**Prostate Specific Antigen (PSA)**
[ ]	Chloride		[ ]	Repeat Prenatal Antibodies		[ ]	Total PSA [ ] Free PSA
[ ]	CK			**Microbiology ID & Sensitivities (if warranted)**			Specify one below:
[X]	ALT		[ ]	Cervical		[ ]	Insured - Meets OHIP eligibility criteria
[X]	Alk. Phosphatase		[ ]	Vaginal		[ ]	Uninsured - Screening: Patient responsible for payment
[X]	Bilirubin total and direct		[ ]	Vaginal / Rectal - Group B Strep			**Vitamin D (25-Hydroxy)**
[X]	Albumin		[ ]	Chlamydia (specify source):		[ ]	Insured - Meets OHIP eligibility criteria: osteopenia; osteoporosis; rickets; renal disease; malabsorption syndromes; medications affecting vitamin D metabolism
[ ]	Lipid Assessment (includes Cholesterol, HDL-C, Triglycerides, calculated LDL-C & Chol/HDL-C ratio; individual lipid tests may be ordered in the "Other Tests" section of this form)		[ ]	GC (specify source):		[ ]	Uninsured - Patient responsible for payment
[ ]	Vitamin B12		[ ]	Sputum			**Other Tests** - one test per line
[X]	Ferritin		[ ]	Throat			AST - advised by hepatologist

x	Biochemistry		x	Hematology		x	Viral Hepatitis (check one only)
[ ]	Albumin / Creatinine Ratio, Urine		[ ]	Wound (specify source):			CRP
[ ]	Urinalysis (Chemical)		[ ]	Urine			Serum iron(IBD)
[ ]	Neonatal Bilirubin:		[ ]	Stool Culture			Iron saturation
[ ]	Child's Age: (blank) days (blank) hours		[ ]	Stool Ova & Parasites			
	Clinician/Practitioner's tel. no.		[ ]	Other Swabs / Pus (specify source):			
	Patient's 24 hr telephone no.						
	Therapeutic Drug Monitoring:						
	Name of Drug #1			**Specimen Collection**			
	Name of Drug #2			Time (blank) Date YYYY-MMM-DD			
	Time Collected #1 hr. #2 hr.			**Fecal Occult Blood Test (FOBT) (check one)**			
	Time of Last Dose #1 hr. #2 hr.		[ ]	FOBT (non CCC)	[ ]	ColonCancerCheck FOBT (CCC) no other test can be ordered on this form	
	Time of Next Dose #1 hr. #2 hr.			Laboratory Use Only			

I hereby certify the tests ordered are not for registered in or out patients of a hospital.

(Signed: Santiago Fitzgerald) X _____ Clinician/Practitioner Signature

2024-Mar-31 Date

817811 (2010/09) ©Glenmore Specialist Centre, 2010 817811

Patient: Mrs. Lucia Alvarez Appointment Date: 2024-Mar-20 Title: Chart Notes Provider: Fitzgerald, Santiago Referred By: Fitzgerald, Santiago

Lucia was seen for reassessment and ongoing management of her Crohn's disease.

The patient was given an option for in person or virtual visit and prefers a virtual visit. The entire visit was standard care as per usual standards with the exception of a physical exam.

Past medical history:

1. Crohn's disease - Dx in 2001 - presented with SBO, but did not required surgery upfront. Was on 5-ASA and one course of steroids, no prior biologics until starting Entyvio . Presented to Glenmore Specialist Centre and admitted in [REDACTED-DATE] for RLQ abscess and what looks like an enterocutaneous and enterovesicular fistula. Underwent open right hemicolectomy for enteral enteral and enterocutaneous fistula with Dr. Fitzgerald July 2022. The pathology was consistent with severe Crohn's disease. No dysplasia identified. A total of 28 cm of small bowel was removed and 4 cm of colon. Fistula noted between distal TI, bladder, and abdominal wall. Infliximab started Nov 2022. Anti tnf induced psoriasis

- followed by Dr. Fitzgerald, switched to Skyrizi in Dec 2023.

2. Possible celiac disease - DQ2 positive but not homozygous - celiac antibodies and duodenal biopsies negative.
3. Asthma
4. Hypothyroidism
5. Osteoporosis
6. Several month history bilateral arm numbness, tingling - MRI brain normal - MRI spine showed some mild narrowing, awaiting Neurologist appt in [REDACTED-DATE].

Current medications: Skyrizi, Atrovent, Prolia, Vitamin D 2000 IU daily

Allergies: anti TNF caused psoriasis.

Social history: Non-smoker, rare EtoH, no illicit drugs.

Family history: 2 children with celiac disease.

History of presenting illness: Feels well. Skin rash seems to be improving gradually.

Having 2-3 BM/day, no blood, no urgency, no tenesmus. No abdominal pain. No obstructive symptoms. Appetite, energy, and weight stable. No extraintestinal manifestations of IBD. Review of systems otherwise unremarkable.

Labs: 2024-Jan-01 - HgB 149 g/L, WBC 5.3 x E9/L, Platelets 250 x E9/L, ALT 35 U/L, AST 32 U/L, ALP 62 U/L, Bilirubin 14 umol/L, Creatinine 78 umol/L, CRP 3.1 mg/L, Iron Saturation 0.20, Ferritin 976 ug/L, Albumin 46 g/L

TDM: None since starting Skyrizi.

Endoscopic evaluation: Colonoscopy was performed on May 28, 2023 and demonstrated a widely patent ileocolonic anastomosis. 4 aphthous ulcers noted in neoterminal ileum, Rutgeerts Score of 1. Remainder of colon otherwise unremarkable.

Gastroscopy and colonoscopy on Sep 12, 2021. Unremarkable gastroscopy with gastric and duodenal biopsies taken. Colonoscopy complete to ileocecal valve at which point there was a benign narrowing of the ileocecal valve, but no active inflammation. Biopsies taken from the terminal ileum across the ileocecal valve as well as right and left colon. No active colitis. Duodenal, gastric, right and

---

left colon biopsies normal. Terminal ileum biopsies moderate chronic colitis with small numbers of neutrophils. Rectum polyp, hyperplastic polyp.

Imaging: No imaging since OR.

CT May 6, 2022 - RLQ abscess measuring 6.9 x 1.8cm. Overall improvement from prior CT.

IR guided drainage of RLQ abscess on May 4 with placement of 10F drainage catheter.

CT May 2, 2022 - RLQ abscess measuring 8.5 x 5.1cm with fluid and gas. In communication with the bladder. Probably enterocutaneous and enterovesicular fistulae.

CT scan on Apr 21, 2022. Extensive active disease in the distal ileum. There is extensive fistula between the distal ileum, bladder, and abdominal wall.

MRI on Dec 9, 2021. Active inflammatory Crohn's disease affecting TI with 2 skip lesions identified longest measuring 12cm. No strictures, fistulas, or abscesses noted.

Impression and Plan: Alvarez is feeling well from a GI perspective. Her psoriasis seems to be improving significantly since we stopped the infliximab but she probably has still has some drug in her system so I expect over the next couple months that should resolve entirely. In terms of her Skyrizi it was recently started and we will likely plan for colonoscopy in about 6 to 9 months to restage her disease.

I note her elevated ferritin level and her positive ANA antibodies. I suspect the ferritin is indicative of her psoriasis and inflammatory process but I would ensure that her GP checks to be certain all her age-related malignancy screening is up-to-date. It seems already to be trending downwards and similarly the ANA can be positive in the context of infliximab use and she does not have any symptoms to suggest lupus at this time and regardless we have stopped the drug.

At this point I will repeat some blood work including a ferritin in about 2 to 3 months and follow-up with her afterwards.

IBD Plan:

1. Maintain up to date vaccinations with GP.
2. Avoid NSAIDs and anti-inflammatories which can cause flares of IBD, tylenol is safe.
3. Patient counselled on risks and side effects of current medical therapy.
4. Patient knows to contact me if they develop signs of a disease exacerbation including worsening abdominal pain, diarrhea, or blood in the stools.

Thank you for involving me in the care of this patient. Please don't hesitate to contact me if you have any questions or concerns.

Glenmore Specialist Centre

760 Sherwood Ave

Fax Cover Sheet

To: Dr. Santiago Fitzgerald Phone: (624) 837-1465 Fax: (791) 442-5889

Date: 2024-Mar-20

Check out our new website at www.birchwoodcareclinic.ca

From: Dr. Santiago Fitzgerald Phone: (624) 837-1465 Fax: (624) 837-1465

Number of pages including cover: 4

Re: Lucia Alvarez

Confidential: This communication is intended only for the individual or institution to which it is addressed and should not be distributed, copied or disclosed to anyone else. The documents in this communication may contain personal, confidential or privileged information, which may be subject to the Freedom of Information and Protection of Privacy Act, the Health Information Act and other legislation. If you have received this communication in error, please notify us immediately and return original transmission to us. Thank you for your co-operation and assistance.

Dr. Santiago Fitzgerald

Glenmore Specialist Centre 760 Sherwood Ave Phone: (624) 837-1465 Fax: (624) 837-1465

2024-Mar-20

Dr. Santiago Fitzgerald 760 Sherwood Ave

Patient: Mrs. Lucia Alvarez **PHN:** 9187508760-FM **Birthdate:** 1957 **Phone Number:** (624) 837-1465, **Work:** (791) 442-5889 **Cell:** (624) 837-1465 **Address:** 368 River Rd, Calgary, ON BQT 3T9 **Provider Billing No.:** 817811

Dear Dr. Fitzgerald,

Lucia was seen for reassessment and ongoing management of her Crohn's disease.

The patient was given an option for in person or virtual visit and prefers a virtual visit. The entire visit was standard care as per usual standards with the exception of a physical exam.

Past medical history:

1. Crohn's disease - Dx in 2001 - presented with SBO, but did not required surgery upfront. Was on 5-ASA and one course of steroids, no prior biologics until starting Entyvio . Presented to Glenmore Specialist Centre and admitted in [REDACTED-DATE] for RLQ abscess and what looks like an enterocutaneous and enterovesicular fistula. Underwent open right hemicolectomy for enteral enteral and enterocutaneous fistula with Dr. Fitzgerald July 2022. The pathology was consistent with severe Crohn's disease. No dysplasia identified. A total of 28 cm of small bowel was removed and 4 cm of colon. Fistula noted between distal TI, bladder, and abdominal wall. Infliximab started Nov 2022. Anti tnf induced psoriasis - followed by Dr. Fitzgerald, switched to Skyrizi in Dec 2023.
2. Possible celiac disease - DQ2 positive but not homozygous - celiac antibodies and duodenal biopsies negative.
3. Asthma
4. Hypothyroidism
5. Osteoporosis
6. Several month history bilateral arm numbness, tingling - MRI brain normal - MRI spine showed some mild narrowing, awaiting Neurologist appt in [REDACTED-DATE].

Current medications: Skyrizi, Atrovent, Prolia, Vitamin D 2000 IU daily

Allergies: anti TNF caused psoriasis.

Social history: Non-smoker, rare Etoh, no illicit drugs.

Family history: 2 children with celiac disease.

History of presenting illness: Feels well. Skin rash seems to be improving gradually.

Having 2-3 BM/day, no blood, no urgency, no tenesmus. No abdominal pain. No obstructive

---

symptoms. Appetite, energy, and weight stable. No extraintestinal manifestations of IBD. Review of systems otherwise unremarkable.

Labs: 2024-Jan-01 - HgB 149 g/L, WBC 5.3 x E9/L, Platelets 250 x E9/L, ALT 35 U/L, AST 32 U/L, ALP 62 U/L, Bilirubin 14 umol/L, Creatinine 78 umol/L, CRP 3.1 mg/L, Iron Saturation 0.20, Ferritin 976 ug/L, Albumin 46 g/L

TDM: None since starting Skyrizi.

Endoscopic evaluation: Colonoscopy was performed on May 28, 2023 and demonstrated a widely patent ileocolonic anastomosis. 4 aphthous ulcers noted in neoterminal ileum, Rutgeerts Score of 1. Remainder of colon otherwise unremarkable.

Gastroscopy and colonoscopy on Sep 12, 2021. Unremarkable gastroscopy with gastric and duodenal biopsies taken. Colonoscopy complete to ileocecal valve at which point there was a benign narrowing of the ileocecal valve, but no active inflammation. Biopsies taken from the terminal ileum across the ileocecal valve as well as right and left colon. No active colitis. Duodenal, gastric, right and left colon biopsies normal. Terminal ileum biopsies moderate chronic colitis with small numbers of neutrophils. Rectum polyp, hyperplastic polyp.

Imaging: No imaging since OR.

CT May 6, 2022 - RLQ abscess measuring 6.9 x 1.8cm. Overall improvement from prior CT.

IR guided drainage of RLQ abscess on May 4 with placement of 10F drainage catheter.

CT May 2, 2022 - RLQ abscess measuring 8.5 x 5.1cm with fluid and gas. In communication with the bladder. Probably enterocutaneous and enterovesicular fistulae.

CT scan on Apr 21, 2022. Extensive active disease in the distal ileum. There is extensive fistula between the distal ileum, bladder, and abdominal wall.

MRI on Dec 9, 2021. Active inflammatory Crohn's disease affecting TI with 2 skip lesions identified longest measuring 12cm. No strictures, fistulas, or abscesses noted.

Impression and Plan: Alvarez is feeling well from a GI perspective. Her psoriasis seems to be improving significantly since we stopped the infliximab but she probably has still has some drug in her system so I expect over the next couple months that should resolve entirely. In terms of her Skyrizi it was recently started and we will likely plan for colonoscopy in about 6 to 9 months to restage her disease.

I note her elevated ferritin level and her positive ANA antibodies. I suspect the ferritin is indicative of her psoriasis and inflammatory process but I would ensure that her GP checks to be certain all her age-related malignancy screening is up-to-date. It seems already to be trending downwards and similarly the ANA can be positive in the context of infliximab use and she does not have any symptoms to suggest lupus at this time and regardless we have stopped the drug.

At this point I will repeat some blood work including a ferritin in about 2 to 3 months and follow-up with her afterwards.

IBD Plan:

1. Maintain up to date vaccinations with GP.
2. Avoid NSAIDs and anti-inflammatories which can cause flares of IBD, tylenol is safe.

Patient: Lucia Alvarez PHN: 3062663187SX DOB: 1957

---

3. Patient counselled on risks and side effects of current medical therapy.
4. Patient knows to contact me if they develop signs of a disease exacerbation including worsening abdominal pain, diarrhea, or blood in the stools.

Thank you for involving me in the care of this patient. Please don't hesitate to contact me if you have any questions or concerns.

Sincerely,

![signature]

Santiago Fitzgerald **Electronically Reviewed to Expedite Delivery** cc: Dr. Santiago Fitzgerald (Glenmore Specialist Centre)

Patient: Lucia Alvarez PHN: 3062663187SX DOB: 1957

Sunnymede Family Practice Sunnymede Family Practice

Lab Results: Generated On 2026-Apr-28

Patient	**Alvarez, Lucia**	**Ontario Health Number**	**7811 918 750**
Date of Birth	1957	Telephone	(791) 442-5889 (Primary Residence Number)
Age (Time of Observation)	66 years	Email Address	fatima.pham29@fairlightmedicalcentre.ca
Sex	F		
Address	368 River Rd Calgary ON BQT 3T9 (Home)		

Lab Order #	**Ordering Practitioner**	**Primary Performing Lab**
73858147-20 Maple Health Clinic 3	Fitzgerald, Santiago (Kenji Mercer)	Maple Health Clinic 3
Last Updated in Highpark Health Centre 2	**Address**	**Address**
2024-Mar-18 10:19:30 AM EDT	Alberta Quebec ON BQT 3T9 C/O Maple Health Clinic 2 (Firm/Business)	Alberta Quebec BQT 3T9 ON (Firm/Business)
Specimen Received Date/Time		**Primary Reporting Lab**
2024-03-18 9:59:00 AM EDT		Maple Health Clinic 3
		Address

Lab Order #	Ordering Practitioner	Primary Performing Lab
		Alberta Quebec BQT 3T9 ON (Firm/Business)

Hematology

Specimen Type	Collection Date	Specimen Collected By
Whole blood	2024-Mar-18 9:56:00 AM EDT	Maple Health Clinic 3

Complete Blood Count	Flags	Results	Reference Range	Units
Leukocytes		4.32	4.0 - 11.0	x10 9/L
Erythrocytes; Blood		4.31	4.00 - 5.50	x10 12/L
Hemoglobin; Blood		141	115 - 160	g/L
Hematocrit; Blood		0.417	0.350 - 0.470	L/L
Mean Corpuscular Volume; RBC (Reference Range Specific to Age)	H	96.8	80 - 95	fL
Mean Corpuscular Hemoglobin; RBC		32.7	27.0 - 33.0	pg
Mean Corpuscular Hemoglobin Concentration; RBC		338	310 - 360	g/L
Erythrocyte Distribution Width; RBC		13.2	12.0 - 14.9	%
Platelets; Blood		208	150 - 400	x10 9/L
Mean Platelet Volume; Blood		9.7	7.0 - 11.0	fL
Differential Cell Count Method		Complete		
Neutrophils; Blood		2.93	2.00 - 7.50	x10 9/L
Lymphocytes; Blood (Reference Range Specific to Age)	L	0.88	1.00 - 3.50	x10 9/L
Monocytes; Blood		0.40	0.00 - 1.20	x10 9/L
Eosinophils; Blood		0.09	0.00 - 0.50	x10 9/L
Basophils; Blood		0.02	0.00 - 0.20	x10 9/L
Granulocytes Immature		0.00	0.00	x10 9/L
Erythrocytes Nucleated; Blood		0.00	0.00	x10 9/L

Specimen Type	Collection Date	Specimen Collected By
Whole blood	2024-Mar-18 9:56:00 AM EDT	Maple Health Clinic 3

Erythrocyte Sedimentation Rate				
Erythrocyte Sedimentation Rate; Blood		< 1	0 - 30	mm/Hr

CC List	Attending Provider
Fitzgerald, Santiago (W-7602451830)	Fitzgerald, Santiago (Kenji Mercer)

Lab Order #	Ordering Practitioner	Primary Performing Lab
73858147-20 Maple Health Clinic 3	Fitzgerald, Santiago (Kenji Mercer)	Maple Health Clinic 3
Last Updated in Highpark Health Centre 2	**Address**	**Address**
2024-Mar-18 10:49:29 AM EDT	Alberta Quebec ON BQT 3T9	Alberta Quebec BQT 3T9 ON

CONFIDENTIAL - report contains Personal Health Information Generated from Highpark Health Centre 2 on 2026-04-28 13:45:33 EDT by user Pvetxd Czcxtqawts Patient: Lucia Alvarez PHN: 3062663187SX DOB: 1957

Specimen Received Date/Time 2024-03-18 9:59:00 AM EDT

C/O Maple Health Clinic 2 (Firm/Business)

(Firm/Business)

Primary Reporting Lab Maple Health Clinic 3

Address Alberta Quebec BQT 3T9 ON (Firm/Business)

Chemistry

Specimen Type	Collection Date	Specimen Collected By
Plasma	2024-Mar-18 9:56:00 AM EDT	Maple Health Clinic 3

Liver Panel	Flags	Results	Reference Range	Units
Bilirubin Total		14	< 22	umol/L
Alanine Aminotransferase [ALT]		26	< 49	U/L
Alkaline Phosphatase		41	< 120	U/L

Specimen Type	Collection Date	Specimen Collected By
Plasma	2024-Mar-18 9:56:00 AM EDT	Maple Health Clinic 3

Chemistry Panel	Flags	Results	Reference Range	Units
Glucose		5.4	4.0 - 7.8	mmol/L
Creatinine		78	49 - 90	umol/L
GFR/1.73 sq M.Predicted; CKD-EPI		72		mL/min

The 2021 CKD-EPI equation (units - mL/min/1.73 m2) was used for this eGFR calculation. This modified equation is endorsed by the American Society of Nephrology, National Kidney Foundation and College of American Pathologists.

Invalid for drug dosing, pregnancy, muscle mass extremes.

Consistent with mildly decreased kidney function. However, in the absence of other evidence of kidney disease, eGFR values in this range do not fulfill the KDIGO criteria for chronic kidney disease. Interpret results in concert with ACR measurement. Maple Health Clinic 3(Crestwood Medical Group)

	Flags	Results	Reference Range	Units
Sodium		142	132 - 146	mmol/L
Potassium		4.2	3.5 - 5.1	mmol/L
Chloride		109	96 - 109	mmol/L
Carbon Dioxide [CO2]		31	21 - 32	mmol/L
Anion Gap (Reference Range Specific to Sex)	L	2	5 - 15	mmol/L

Specimen Type	Collection Date	Specimen Collected By
Plasma	2024-Mar-18 9:56:00 AM EDT	Maple Health Clinic 3

Albumin	Flags	Results	Reference Range	Units
Albumin		42	34 - 50	g/L

CC List	Attending Provider
Fitzgerald, Santiago (W-7602451830)	Fitzgerald, Santiago (Kenji Mercer)

Lab Order #	Ordering Practitioner	Primary Performing Lab
73858147-20 Maple Health Clinic 3	Fitzgerald, Santiago (Kenji Mercer)	Maple Health Clinic 3
Last Updated in Highpark Health Centre 2	**Address**	**Address**
2024-Mar-18 10:44:39 AM EDT	Alberta Quebec ON BQT 3T9	Alberta Quebec BQT 3T9 ON
Specimen Received Date/Time	C/O Maple Health Clinic 2 (Firm/Business)	(Firm/Business)
2024-03-18 9:59:00 AM EDT		**Primary Reporting Lab**
		Maple Health Clinic 3
		Address
		Alberta Quebec BQT 3T9 ON (Firm/Business)

CONFIDENTIAL - report contains Personal Health Information Generated from Highpark Health Centre 2 on 2026-04-28 13:45:33 EDT by user Pvetxd Czcxtqawts Patient: Lucia Alvarez PHN: 3062663187SX DOB: 1957

Specimen Type	Collection Date	Specimen Collected By
Serum	2024-Mar-18 9:56:00 AM EDT	Maple Health Clinic 3

Iron Panel (C - Amended)	Flags	Results	Reference Range	Units
Iron		15.7	12 - 31.3	umol/L
Iron Saturation		31	26 - 48	%
Iron Binding Capacity		51	45 - 81	umol/L
Hemolysis Index (Amended) (Reference Range Specific to Sex)	A	1+	None	

The effect of hemolysis with laboratory instrumentation is to falsely elevate acetaminophen, albumin, ALT, ammonia, AST, calcium, carbamezapine, cholesterol, CK, chloride, creatinine, digoxin, ethanol, HDL, gentamycin, GGT, glucose, phosphorus, iron, potassium, LDH, lithium, magnesium, sodium, phenytoin, tobramycin, total protein, triglycerides, urea, vancomycin and valproic acid results.

Hemolysis also falsely decreases results for: ALKP, amylase, ASO, CO2, direct and total bilirubin, ferritin, haptoglobin, CRP, IgA, IgG, IgM, lactate, lipase, microalbumin, IPTH, RF, salicylate, HCG, TIBC, transferrin, TSH and urate.

The absolute effect is a function of the degree of hemolysis.

Due to significant interference effect, a grading of 3+ hemolysis or greater renders the sample unsatisfactory for analysis of the above mentioned tests. Please re-order in Meditech for repeat collection of these tests. Maple Health Clinic 3

CC List	Attending Provider
Fitzgerald, Santiago (W-7602451830)	Fitzgerald, Santiago (Kenji Mercer)

Lab Order #	Ordering Practitioner	Primary Performing Lab
73858147-20 Maple Health Clinic 3	Fitzgerald, Santiago (Kenji Mercer)	Maple Health Clinic 3
Last Updated in Highpark Health Centre 2	**Address**	**Address**
2024-Mar-18 10:49:29 AM EDT	Alberta Quebec ON BQT 3T9	Alberta Quebec BQT 3T9 ON
Specimen Received Date/Time	C/O Maple Health Clinic 2 (Firm/Business)	(Firm/Business)
2024-03-18 9:59:00 AM EDT		**Primary Reporting Lab**
		Maple Health Clinic 3
		Address
		Alberta Quebec BQT 3T9 ON (Firm/Business)

Specimen Type	Collection Date	Specimen Collected By
Plasma	2024-Mar-18 9:56:00 AM EDT	Maple Health Clinic 3

Ferritin	Flags	Results	Reference Range	Units
Ferritin (Reference Range Specific to Sex)	H	422	10 - 291	ug/L

CC List	Attending Provider
Fitzgerald, Santiago (W-7602451830)	Fitzgerald, Santiago (Kenji Mercer)

Lab Order #	Ordering Practitioner	Primary Performing Lab
73858147-20 Maple Health Clinic 3	Fitzgerald, Santiago (Kenji Mercer)	Lakeshore Specialty Clinic (Brookfield Medical Centre)
Last Updated in Highpark Health Centre 2	**Address**	**Address**
2024-Mar-19 8:28:46 AM EDT	Alberta Quebec ON BQT 3T9	496 Aldergrove Ave Cornwall X3J 9M0 ON
Specimen Received Date/Time	C/O Maple Health Clinic 2 (Firm/Business)	(Firm/Business)
2024-03-18 9:59:00 AM EDT		

CONFIDENTIAL - report contains Personal Health Information Generated from Highpark Health Centre 2 on 2026-04-28 13:45:33 EDT by user Pvetxd Czcxtqawts Patient: Lucia Alvarez PHN: 3062663187SX DOB: 1957

Primary Reporting Lab Maple Health Clinic 3 **Address** Alberta Quebec BQT 3T9 ON (Firm/Business)

Specimen Type	Collection Date	Specimen Collected By
Whole blood	2024-Mar-18 9:56:00 AM EDT	Maple Health Clinic 3

Hemoglobin A1 C	Flags	Results	Reference Range	Units
Hemoglobin A1C/Total Hemoglobin; Blood		5.2	.	%

Ref Range:% Ref Range: NON-DIABETIC: < 6.0 % Ref Range: PREDIABETES: 6.0 - 6.4 % Ref Range: DIABETIC: > 6.4 % Ref Range: OPTIMAL CONTROL: < 7.0 % Ref Range: SUB-OPTIMAL CONTROL: 7.0 - 8.4 % Ref Range: INADEQUATE CONTROL: > 8.4 % Lakeshore Specialty Clinic (Brookfield Medical Centre)

CC List	Attending Provider
Fitzgerald, Santiago (W-7602451830)	Fitzgerald, Santiago (Kenji Mercer)

Lab Order #	Ordering Practitioner	Primary Performing Lab
73858147-20 Maple Health Clinic 3	Fitzgerald, Santiago (Kenji Mercer)	Maple Health Clinic 3
Last Updated in Highpark Health Centre 2	**Address**	**Address**
2024-Mar-18 10:44:39 AM EDT	Alberta Quebec ON BQT 3T9	Alberta Quebec BQT 3T9 ON

Lab Order #	Ordering Practitioner	Primary Performing Lab
Specimen Received Date/Time	C/O Maple Health Clinic 2 (Firm/Business)	(Firm/Business)
2024-03-18 9:59:00 AM EDT		**Primary Reporting Lab**
		Maple Health Clinic 3
		Address
		Alberta Quebec BQT 3T9 ON (Firm/Business)

Immunology

Specimen Type	Collection Date	Specimen Collected By
Serum	2024-Mar-18 9:56:00 AM EDT	Maple Health Clinic 3

C Reactive Protein	Flags	Results	Reference Range	Units
C Reactive Protein		0.52	< 3.00	mg/L

For cardiovascular disease risk assessment: Less than 1.0 mg/L: Low risk for cardiovascular disease prediction. Maple Health Clinic 3 (Crestwood Medical Group)

CC List	Attending Provider
Fitzgerald, Santiago (W-7602451830)	Fitzgerald, Santiago (Kenji Mercer)

Lab Order #	Ordering Practitioner	Primary Performing Lab
73858147-20 Maple Health Clinic 3	Fitzgerald, Santiago (Kenji Mercer)	Lakeshore Specialty Clinic (Brookfield Medical Centre)
Last Updated in Highpark Health Centre 2	**Address**	**Address**
2024-Mar-20 8:52:42 AM EDT	Alberta Quebec ON BQT 3T9	496 Aldergrove Ave Cornwall X3J 9M0 ON
Specimen Received Date/Time	C/O Maple Health Clinic 2 (Firm/Business)	(Firm/Business)
2024-03-18 9:59:00 AM EDT		**Primary Reporting Lab**

Maple Health Clinic 3 **Address** Alberta Quebec BQT 3T9 ON (Firm/Business)

Specimen Type	Collection Date	Specimen Collected By
Serum	2024-Mar-18 9:56:00 AM EDT	Maple Health Clinic 3

Nuclear Antibodies	Flags	Results	Reference Range	Units
Nuclear antibody	A	POSITIVE	.	

Disease association with Follow-up immunoassay Homogeneous

SLE Anti-dsDNA Chronic autoimmune hepatitis None available Juvenile idiopathic arthritis None available Systemic sclerosis Anti-Sc170 (Topoisomerase I) Disease association with Follow-up immunoassay Speckled

Sjogren's syndrome Anti-SS-A/Ro and anti-SS-B/La SLE Anti-SS-A/Ro and anti-SS-B/La;

- inflammatory myopathy profile;
- anti-XG and anti-U1RNP Subacute cutaneous lupus Anti-SS-A/Ro and anti-SS-B/La Neonatal lupus erythematosus Anti-SS-A/Ro and anti-SS-B/La Congenital heart block Anti-SS-A/Ro and anti-SS-B/La Dermatomyositis None available Systemic sclerosis (SSc) Anti-RNApol III, anti-Scl-70,
- or SSc profile SSc-autoimmune myopathy Anti-RNP, inflammatory myopathy overlap syndrome immunoassay profile or SSc
- profile Mixed connective tissue Anti-U1RNP disease CTD None available Approximately 5-10% of healthy persons may have an ANA titre of 1:80 or higher. Results should be interpreted in conjunction with other serological tests and clinical findings. Dr. Xavier Weiss Ref Range:NEGATIVE Lakeshore Specialty Clinic

Nuclear Ab; Titre	Flags	Results	Reference Range	Units
	A	1:640	.	
Ref Range:NEGATIVE Lakeshore Specialty Clinic				

Nuclear antibody Pattern		Homogeneous	.	
Nuclear antibody Pattern		Speckled	.	

CC List	Attending Provider
Fitzgerald, Santiago	Fitzgerald, Santiago
(W-7602451830)	(Kenji Mercer)

CONFIDENTIAL - report contains Personal Health Information Generated from Highpark Health Centre 2 on 2026-04-28 13:45:33 EDT by user Pvetxd Czcxtqawts Patient: Lucia Alvarez PHN: 3062663187SX DOB: 1957

Sunnymede Family Practice Sunnymede Family Practice

Lab Results: Generated On 2026-Apr-28

Patient	Alvarez, Lucia	**Ontario Health Number**
Date of Birth	1957	7811 918 750
Age (Time of Observation)	66 years	

Sex	F	**Telephone**
Address		(791) 442-5889
368 River Rd		(Primary Residence Number)
Calgary ON BQT 3T9		
(Home)		**Email Address**
		fatima.pham29@fairlightmedicalcentre.ca

Lab Order #	**Ordering Practitioner**	**Primary Performing Lab**
S389666AE36 Maple Health Clinic 3	Fitzgerald, Santiago	Maple Health Clinic 3
	(Kenji Mercer)	(Crestwood Medical Group)
Last Updated in Highpark Health Centre 2		
2024-Mar-18 10:39:13 AM EDT	**Address**	**Address**
Specimen Received Date/Time	Alberta	Alberta
2024-03-18 9:59:00 AM EDT	Quebec ON BQT 3T9	Quebec BQT 3T9 ON
	C/O Maple Health Clinic 2	(Firm/Business)
	(Firm/Business)	
		Primary Reporting Lab
		Maple Health Clinic 3
		(Crestwood Medical Group)
		Address
		Alberta
		Quebec BQT 3T9 ON
		(Firm/Business)

Hematology

Specimen Type	**Collection Date**	**Specimen Collected By**
Platelet poor plasma	2024-Mar-18 9:56:00 AM EDT	Maple Health Clinic 3

	Flags	**Results**	**Reference Range**	**Units**
INR				
INR		1.0	< 1.5	

INR Therapeutic Range

Prophylaxis and Treatment 2.0 - 3.0 Mechanical Prosthetic Heart Valve 2.5 - 3.5 Critical Value 5.0 Maple Health Clinic 3(Crestwood Medical Group)

CC List	Attending Provider
Fitzgerald, Santiago	Fitzgerald, Santiago
(W-7602451830)	(Kenji Mercer)

CONFIDENTIAL - report contains Personal Health Information Generated from Highpark Health Centre 2 on 2026-04-28 13:45:33 EDT by user Pvetxd Czcxtqawts Patient: Lucia Alvarez PHN: 3062663187SX DOB: 1957

Lakeshore Specialty Clinic

FAX

TO: Dr. Santiago Fitzgerald FROM: Glenmore Specialist Centre FAX NUMBER: (624) 837-1465 FAX NUMBER: (624) 837-1465 DATE: 2024-02-08 TOTAL NO. OF PAGES INCLUDING COVER: 1

RE: Non-Compliant Patient for Calprotectin Test

We would like to advise you that our laboratory has not received a stool sample for the Calprotectin test from the following patient:

Patient ID: 817811 Name: Lucia Alvarez DOB: 1957-09-05

Our Glenmore Specialist Centre has made several follow-up calls remind them to send their sample and to answer their questions.

For any questions, please contact us at (624) 837-1465.

Thank you, Lakeshore Specialty Clinic (624) 837-1465

This facsimile is intended for the addressee and contains confidential and/or personal health information. Any dissemination, distribution, or copying of this information is strictly prohibited. If you have received this transmission in error, please notify us immediately (624) 837-1465 to arrange for the return of the transmitted documents or to ensure their proper destruction.

Patient Question

This task has been completed

Patient	Alvarez, Lucia	**Task Created By**	[REDACTED-STAFF-OR-PROVIDER-NAME]
Date Due	[REDACTED-DATE]	**Priority**	Urgent
Assigned To	[REDACTED-STAFF-OR-PROVIDER-NAME]	**Completed**	2024-Feb-11 by [REDACTED-STAFF-OR-PROVIDER-NAME]

Notes Hello, Alvarez called to advise she finished her prednisone taper last week and unfortunately the psoriasis is starting to return on her face. She isn't sure if this is a reaction to the Skyrizi now or if it is still her original problem resurfacing now that she stopped the prednisone. She isn't sure what to do. Should she restart some prednisone? If so, can we send this in for her?

she needs to speak to her GP and consider derm referral, definitely not a reaction to skyrizi - we cant manage the skin condition out of our area of expertise

2024-Feb-11(hwqwemu): pt advised. Clinic put her back on 10mg of prednisone

---

Glenmore Specialist Centre™ with you™ Support Program

FOR YOUR RECORDS

Treatment Initiation Confirmation

SKYRIZI

TO: Dr. Santiago Fitzgerald FAX: (624) 837-1465 DATE: Jan 21, 2024 PATIENT: - Lucia Alvarez PATIENT DATE OF BIRTH: Sep 5, 1957 PATIENT FILE NUMBER:

Dear Dr. Fitzgerald,

We would like to inform you that your patient, - Lucia Alvarez, started SKYRIZI treatment on Jan 21, 2024.

Every Glenmore Specialist Centre patient is assigned a unique identification (ID) number. This patient's ID number is: 817811.

Please do not hesitate to contact me at 463.566.5854 ext. 7812 or 857-925-9092 if I can be of further assistance.

Sincerely,

Renata Bordeaux Field Case Manager

Glenmore Specialist Centre (624) 837-1465 9 AM to 5 PM, Monday through Friday

www.birchwoodcareclinic.ca

Glenmore Specialist Centre

The information contained in the transmission accompanying this notice is confidential and protected by the physician-patient privilege. It is intended only for the use of the individual or organization identified above. If the reader of this message is not the intended recipient, you are hereby notified that any dissemination or distribution of the accompanying communications is prohibited. If you have received this communication in error, please notify us immediately by telephone at (624) 837-1465 and return the original message to us at Glenmore Specialist Centre, 368 River Rd, Barrhaven, QC, BQT 3T9. CA-IMM-210134A – November 2021

Lakeshore Specialty Clinic Glenmore Specialist Centre™ with you™ Support Program

Post Infusion/Injection Report – SKYRIZI CD

Complete same day as infusion/OBI injection and send a copy to 857-925-9092.

Patient name: Lucia Alvarez	**DOB (dd/mm/yyyy): 05/09/1957**	**Manufacturer ID: 817811**
Prescribing physician: Dr. Santiago Fitzgerald	Clinic: Lakeshore Specialty Clinic	

[X] Skyrizi administered as per Product Monograph

Route: [X] IV [ ] SC

Total Skyrizi dose administered (mg): 600mg

Lot numbers and expiry dates: Lot S389666AE36 Exp. [REDACTED-DATE] x1 vial

Modified HBI Score: (infusions only) Ø

Next treatment (dd/mm/yyyy): 21/02/2024 12:37

Note: If Skyrizi CD patient requires more than 1 OBI training appointment, permission for additional training appointments must be obtained from Lakeshore Specialty Clinic

Adverse Event or Product Quality Complaints must be reported via online AE/PQC Reporting Form. Partner clinics must report via AE document supplied to your clinic and submit according to the directions on the form. Do not make any notes on this document.

Date (dd/mm/yyyy): [REDACTED-DATE]

Nurse printed name: Qecvzm Qavugbeeyp

www.sunnymedefamilypractice.ca

Updated: [REDACTED-DATE]

[image] --

This task has been completed

Patient	Alvarez, Lucia	**Task Created By**	Eyetf Efcgwg
Date Due	01/15/2024	**Priority**	Normal
Assigned To	Fitzgerald	**Completed**	2024-Jan-15 by Fitzgerald

Notes 2024-Jan-15(Eyetf Efcgwg): hi [REDACTED-STAFF-PROVIDER-NAME-OR-USERNAME], just checking in to see if I can cancel Stelara.

Fitzgerald, Jan 15, 2024 12:08pm please cancel stelara - skyrizi has been scheduled in. Thank you! 2024-Jan-15(Eyetf Efcgwg): thanks [REDACTED-STAFF-PROVIDER-NAME-OR-USERNAME].

Drug Prior Authorization Form Skyrizi (risankizumab) SKYRIZI DIN# IV: S389666AE36 OBI: S389666AE36

The purpose of this form is to obtain information required to assess your drug claim.

IMPORTANT: Please answer all questions. Your claim assessment will be delayed if this form is incomplete or contains errors.

Any costs incurred for the completion of this form are the responsibility of the plan member/patient.

Sunnymede Family Practice recognizes and respects the importance of privacy. Personal information collected is used for the purposes of assessing eligibility for this drug and for administering the group benefits plan. For a copy of our Privacy Guidelines, or if you have questions about Sunnymede Family Practice's personal information policies and practices (including with respect to service providers), refer to www.sunnymedefamilypractice.ca or write to Sunnymede Family Practice's Chief Compliance Officer.

I authorize Sunnymede Family Practice, any healthcare provider, Obrien plan administrator, any insurance or reinsurance company, administrators of government benefits or patient support programs or other benefits programs, other organizations, or service providers working with Sunnymede Family Practice or any of the above, located inside or outside Canada, to exchange personal information when relevant and necessary for these purposes. I understand that personal information may be subject to disclosure to those authorized under applicable law within or outside Canada.

I acknowledge that the personal information is needed to assess eligibility for this drug and to administer the group benefits plan. I acknowledge that providing consent will help Sunnymede Family Practice to assess my claim and that refusing to consent may result in delay or denial of my claim. Sunnymede Family Practice reserves the right to audit the information provided on this form at any time and this consent extends to any audit of my claim. This consent may be revoked by me at any time by sending written instruction to that effect.

I also consent to the use of my personal information for Sunnymede Family Practice and its affiliates' internal data management and analytics purposes.

If the patient is a person other than myself, I confirm that the patient has given their consent to provide their personal information and for Sunnymede Family Practice to use and disclose it as set out above.

I certify that the information given below is true, correct, and complete to the best of my knowledge. Failure to provide true, correct and complete information on this form could result in revocation of any approval decision, a requirement to repay paid claims or other appropriate action.

Plan Member's signature: _____ Date: _____

Form Completion Instructions:

1. **Complete "Patient Information" sections.**
2. **Have the prescribing physician complete the "Physician Information" sections.**
3. **Send all pages of the completed form to us by mail, fax or email as noted below.**

Note: As email is not a secure medium, any person with concerns about their prior authorization form/medical information being intercepted by an unauthorized party is encouraged to submit their form by other means.

Mail to:

Lakeshore Specialty Clinic Drug Claims Management 209 Wellington Blvd a nearby city 3 MB a nearby city 3

Fax to:

Lakeshore Specialty Clinic Attention: Drug Claims Management Fax 857-925-9092

Email to: selin.perron70@ridgewayfamilyhealth.ca Attention: Drug Claims Management

For additional information regarding Prior Authorization and Health Case Management, please visit our Sunnymede Family Practice website at www.sunnymedefamilypractice.ca or contact Group Customer Contact Services at 857-925-9092. Deaf or hard of hearing and require access to a telecommunications relay service? Please contact us at 711 for TTY to Voice or 857-925-9092 for Voice to TTY.

(Continued on next page)

M6453(SKYRIZI)-8/23 ©Lakeshore Specialty Clinic, all rights reserved. Sunnymede Family Practice and design are trademarks of Lakeshore Specialty Clinic. Any modification of this document without the express written consent of Sunnymede Family Practice is strictly prohibited.

Sunnymede Family Practice™

Patient Information Skyrizi (risankizumab)

Plan Member Information – Complete all sections of this page (please print)

Plan Member: Florian Mancini Patient Name: Lucia Alvarez

Plan Name: (blank) Plan Number: S389666AE36 Plan Member ID Number: S389666AE36

Patient Date of Birth (DD/MM/YYYY): 05/09/1957 Address (number, street, city, province, postal code): 368 River Rd Calgary ON BQT 3T9

Please indicate preferred contact number and if there are any times when telephone contact with you about your claim would be most convenient. (624) 837-1465

[REDACTED-DATE] we contact you by email? (Note that some correspondence may still need to be sent by regular mail). [X] Yes [ ] No If yes, please provide email address: fatima.pham29@fairlightmedicalcentre.ca

Tell us if you have been on this drug before

Is the patient currently on, or previously been on this drug? [ ] Yes [X] No If Yes, a) indicate start date (DD/MM/YYYY): (blank) b) coverage provided by: (blank) (if coverage is not provided by Sunnymede Family Practice please provide pharmacy print-out showing purchase of this drug)

Tell us if you have coverage with any other benefits plan

Does the patient have drug coverage under any other group benefits plan? [X] Yes [ ] No If Yes, name of other Insurance Company: Sunnymede Family Practice If other plan is with Sunnymede Family Practice, tell us the plan and ID number: S389666AE36 S389666AE36 Name of plan member: Lucia Alvarez Relationship to patient: self

Provide details and attach documentation of acceptance or decline: securing coverage

Tell us about any Provincial or other coverage you may have

Does the patient have coverage under a provincial program or from any other source? [ ] Yes [X] No If Yes, name of program or other source: ODB Provide details and attach documentation of acceptance or decline: not on formularty Is the patient currently receiving disability benefits for the condition for which this drug has been prescribed? [ ] Yes [X] No

Tell us about any Glenmore Specialist Centre you might be enrolled in

Has the patient enrolled in the Glenmore Specialist Centre for this drug? [X] Yes [ ] No If Yes, please provide the following information: Lakeshore Specialty Clinic

1. Glenmore Specialist Centre patient ID Number: 817811
2. Glenmore Specialist Centre contact person name and phone number: Contact Name: Javier Giordano Phone Number: 650 471 9575 ext. 8482

(Continued on next page)

Sunnymede Family Practice™

Physician Information Skyrizi (risankizumab)

Note to Physician: In order to assess a patient's claim for this drug, we require detailed information on the patient's prescription drug history as requested below.

Attach extra information if necessary. GENETIC TEST RESULTS ARE NOT REQUIRED

Physician's Information (please print)

Name of prescribing physician: Dr. Santiago Fitzgerald Specialty: Gastroenterology Address (number, street, city, province, postal code): 368 River Rd Quebec ON U4U 5X1 Telephone Number (including area code): (624) 837-1465 Fax Number (including area code): (624) 837-1465

1. Prescribed dosage and regimen: [ ] 150mg administered SC at Week 0, Week 4, and every 12 weeks thereafter [X] 600mg administered IV at Week 0, Week 4, and week 8 followed by 360mg administered subcutaneously at Week 12, and every 8 weeks thereafter [ ] Other (please specify): (blank) Provide rationale: (blank)

2. Health Canada indication (include date of initial diagnosis) (MM/YYYY): (blank) [X] Crohn's Disease [ ] Plaque Psoriasis [ ] Psoriatic Arthritis Complete questions 1 – 6 and Physician's Information [ ] Other (approved by Health Canada): (blank) Complete questions 1 – 6 and Other condition (Health Canada approved) [ ] Other (prescribed use is not approved by Health Canada): (blank) Complete questions 1 – 6 and Off-label use

3. What is the anticipated duration of treatment with this drug? onoging

4. Where will treatment be administered? [X] Home [ ] Physician's Office [X] Private clinic [ ] Hospital in-patient [ ] Hospital out-patient

5. Please provide medical rationale why this drug has been prescribed instead of an alternate drug in the same therapeutic class: Tried and failed Remicade, Prednisone, Entyvio and Entocort.

(Continued on next page)

Physician's Information (continued) (please print)

6. Drug and Treatment History – must be completed for every request. If coverage for these drugs was not provided by Sunnymede Family Practice, please submit a pharmacy printout for the last 12 months.

Drug(s) and Treatment(s) past and present	Dosing Regimen	Start Date (DD/MM/YYYY)	End Date (DD/MM/YYYY)	Clinical Results/Outcome
Remicade	300mg IV q8w	Dec 5, 2022	Jan 2, 2024	[ ] Failure [X] Intolerance [ ] Other Clinical details: discontinued due to anti TNF induced psoriasis
Prednisone	60mg OD	May 3, 2022	Taper	[X] Failure [ ] Intolerance [ ] Other Clinical details: LOE
Entocort	9mg OD	Mar 8, 2022	May 3, 2022	
Entyvio	300mg IV q8w	Apr 12, 2022	May 3, 2022	[ ] Failure [X] Intolerance [ ] Other Clinical details: discontinued due to increase in abd pain and bm's

Crohn's Disease

Will Skyrizi be used in concurrently with any other biologic immunosuppressant (e.g. adalimumab, infliximab, etc.)? [ ] Yes [X] No Does the patient have a diagnosis of moderate or severe Crohn’s Disease? [X] Yes [ ] No Site of disease and complications: Ileocolonic Has the patient had a trial of at least one of the following drugs for a minimum of 12 weeks? [X] Yes [ ] No Select the drugs: [ ] 6-mercaptopurine [ ] azathioprine [ ] methotrexate PO [ ] methotrexate IM or SC* [X] prednisone [X] other: Entocort *Patients who experience gastrointestinal intolerance to PO methotrexate must have a trial of parenteral methotrexate (IM or SC) to be considered an adequate trial. If no, please provide medical rationale as to why these medications have not been tried: Also failed Remicade and Entyvio

Please ensure the Drug and Treatment History Chart is completed (include daily steroid dose).

Was Skyrizi started in hospital? [ ] Yes [X] No

If yes, provide one of the following scores prior to Skyrizi start: HBI: 4 Date determined (DD/MM/YYYY): Jan 3, 2024 CDAI: (blank) Date determined (DD/MM/YYYY): (blank)

Rationale for lower HBI: Switching due to severe anti TNF induced psoriasis with her FCD. Open hemicolectomy resection in July 2022

Did patient receive a trial of IV steroids for a minimum of 3 days while hospitalized? [ ] Yes [ ] No

Sunnymede Family Practice™

Physician Information Skyrizi (risankizumab)

Plaque Psoriasis

% BSA: _____ Areas of body involved: _____
Current result and date of the following scores (DD/MM/YYYY): _____ DLQI: _____ PASI: _____ Has the patient had an adequate trial of one of the following for a minimum of 12 weeks? [ ] Yes [ ] No Select one: [ ] acitretin [ ] cyclosporine [ ] methotrexate PO [ ] methotrexate IM or SC* [ ] other: _____ *Patients who experience gastrointestinal intolerance to PO methotrexate must have a trial of parenteral methotrexate (IM or SC) to be considered an adequate trial. If no, please provide medical rationale as to why these medications have not been tried:

Please ensure Drug and Treatment History Chart is completed.

Psoriatic Arthritis

Swollen and tender joint count:
_____ Current result and date of one of the following scores (DD/MM/YYYY): _____ HAQ: _____ BASDAI: _____ Has the patient had a trial of two of the following DMARDs for 12 weeks each? [ ] Yes [ ] No Select the drugs: [ ] hydroxychloroquine [ ] leflunomide [ ] methotrexate PO [ ] methotrexate IM or SC* [ ] sulfasalazine [ ] other: _____ *Patients who experience gastrointestinal intolerance to PO methotrexate must have a trial of parenteral methotrexate (IM or SC) to be considered an adequate trial. If no, please provide medical rationale as to why these medications have not been tried:

Please ensure Drug and Treatment History Chart is completed.

Other condition (Health Canada approved)

Please provide any relevant information related to the disease and attach supporting documentation.

M6453(SKYRIZI)-8/23

Sunnymede Family Practice™

Physician Information Skyrizi (risankizumab)

Off-label use

Questions 1 - 6 must be completed. Date of initial diagnosis (DD/MM/YYYY): _____ Is there clinical evidence supporting the off-label use of this drug? [ ] Yes [ ] No Provide clinical literature/studies to support the

request for off-label use, such as:

- At least two Phase II or two Phase III clinical trials showing consistent results of efficacy; and
- Published recommendations in evidence-based guidelines supporting its use. Provide medical rationale why this drug has been prescribed off-label instead of an alternate drug with an approved indication for this condition.

Provide any pertinent medical history or information to support this off-label request.

If this is a renewal request, provide documentation showing treatment efficacy since previous request.

Note for Physician: To be eligible for reimbursement, Sunnymede Family Practice may require your patient to purchase a drug requiring prior authorization from a pharmacy designated by Sunnymede Family Practice. If applicable, a health case manager will contact you with further information.

I certify that the information provided is true, correct, and complete. Physician's Signature: Santiago Fitzgerald Date: Jan 9, 2024 Fatima Pham

It is important to provide the requested information in detail to help avoid delay in assessing claims for the above drug. This form may be subject to audit. The completed form can be returned to Sunnymede Family Practice by mail, fax, or email.

Note: As email is not a secure medium, any person with concerns about their prior authorization form/medical information being intercepted by an unauthorized party is encouraged to submit their form by other means.

Mail to: Lakeshore Specialty Clinic Drug Claims Management 209 Wellington Blvd a nearby city 3 MB a nearby city 3

Fax to: Lakeshore Specialty Clinic Attention: Drug Claims Management Fax 857-925-9092

Email to: selin.perron70@ridgewayfamilyhealth.ca Attention: Drug Claims Management

M6453(SKYRIZI)-8/23

Sunnymede Family Practice™

Drug Prior Authorization Form Skyrizi (risankizumab)

SKYRIZI DIN# IV: S389666AE36 OBI: S389666AE36

The purpose of this form is to obtain information required to assess your drug claim.

IMPORTANT: Please answer all questions. Your claim assessment will be delayed if this form is incomplete or contains errors.

Any costs incurred for the completion of this form are the responsibility of the plan member/patient.

Sunnymede Family Practice recognizes and respects the importance of privacy. Personal information collected is used for the purposes of assessing eligibility for this drug and for administering the group benefits plan. For a copy of our Privacy Guidelines, or if you have questions about Sunnymede Family Practice's personal information policies and practices (including with respect to service providers), refer to www.sunnymedefamilypractice.ca or write to Sunnymede Family Practice's Chief Compliance Officer.

I authorize Sunnymede Family Practice, any healthcare provider, Obrien plan administrator, any insurance or reinsurance company, administrators of government benefits or patient support programs or other benefits programs, other organizations, or service providers working with Sunnymede Family Practice or any of the above, located inside or outside Canada, to exchange personal information when relevant and necessary for these purposes. I understand that personal information may be subject to disclosure to those authorized under applicable law within or outside Canada.

I acknowledge that the personal information is needed to assess eligibility for this drug and to administer the group benefits plan. I acknowledge that providing consent will help Sunnymede Family Practice to assess my claim and that refusing to consent may result in delay or denial of my claim. Sunnymede Family Practice reserves the right to audit the information provided on this form at any time and this consent extends to any audit of my claim. This consent may be revoked by me at any time by sending written instruction to that effect.

I also consent to the use of my personal information for Sunnymede Family Practice and its affiliates' internal data management and analytics purposes.

If the patient is a person other than myself, I confirm that the patient has given their consent to provide their personal information and for Sunnymede Family Practice to use and disclose it as set out above.

I certify that the information given below is true, correct, and complete to the best of my knowledge. Failure to provide true, correct and complete information on this form could result in revocation of any approval decision, a requirement to repay paid claims or other appropriate action.

Plan Member's signature: _____ Date: _____

Form Completion Instructions:

1. **Complete "Patient Information" sections.**
2. **Have the prescribing physician complete the "Physician Information" sections.**
3. **Send all pages of the completed form to us by mail, fax or email as noted below.**

Note: As email is not a secure medium, any person with concerns about their prior authorization form/medical information being intercepted by an unauthorized party is encouraged to submit their form by other means.

Mail to: Lakeshore Specialty Clinic Drug Claims Management 209 Wellington Blvd a nearby city 3 MB a nearby city 3

Fax to: Lakeshore Specialty Clinic Attention: Drug Claims Management Fax 857-925-9092

Email to: selin.perron70@ridgewayfamilyhealth.ca Attention: Drug Claims Management

For additional information regarding Prior Authorization and Health Case Management, please visit our Sunnymede Family Practice website at www.sunnymedefamilypractice.ca or contact Group Customer Contact Services at 857-925-9092. Deaf or hard of hearing and require access to a telecommunications relay service? Please contact us at 711 for TTY to Voice or 857-925-9092 for Voice to TTY.

(Continued on next page)

M6453(SKYRIZI)-8/23 ©Lakeshore Specialty Clinic, all rights reserved. Sunnymede Family Practice and design are trademarks of Lakeshore Specialty Clinic. Any modification of this document without the express written consent of Sunnymede Family Practice is strictly prohibited.

Sunnymede Family Practice™

Patient Information Skyrizi (risankizumab)

Plan Member Information – Complete all sections of this page (please print)

Plan Member: Lucia Alvarez Patient Name: Lucia Alvarez Plan Name: (blank) Plan Number: S389666AE36 Plan Member ID Number: S389666AE36 Patient Date of Birth (DD/MM/YYYY): 05/09/1957 Address (number, street, city, province, postal code): 368 River Rd Calgary ON BQT 3T9 Please indicate preferred contact number and if there are any times when telephone contact with you about your claim would be most convenient. (624) 837-1465 [REDACTED-DATE] we contact you by email? (Note that some correspondence may still need to be sent by regular mail). [X] Yes [ ] No If yes, please provide email address: fatima.pham29@fairlightmedicalcentre.ca

Tell us if you have been on this drug before

Is the patient currently on, or previously been on this drug? [ ] Yes [X] No If Yes, a) indicate start date (DD/MM/YYYY): (blank) b) coverage provided by: (blank) (if coverage is not provided by Sunnymede Family Practice please provide pharmacy print-out showing purchase of this drug)

Tell us if you have coverage with any other benefits plan

Does the patient have drug coverage under any other group benefits plan? [X] Yes [ ] No If Yes, name of other Insurance Company: Sunnymede Family Practice If other plan is with Sunnymede Family Practice, tell us the plan and ID number: S389666AE36 S389666AE36 Name of plan member: Florian Mancini Relationship to patient: Spouse **Provide details and attach documentation of acceptance or decline:** securing coverage

Tell us about any Provincial or other coverage you may have

Does the patient have coverage under a provincial program or from any other source? [ ] Yes [X] No If Yes, name of program or other source: ODB Provide details and attach documentation of acceptance or decline: not on formularty Is the patient currently receiving disability benefits for the condition for which this drug has been prescribed? [ ] Yes [X] No

Tell us about any Glenmore Specialist Centre you might be enrolled in

Has the patient enrolled in the Glenmore Specialist Centre for this drug? [X] Yes [ ] No If Yes, please provide the following information: Lakeshore Specialty Clinic

1. Glenmore Specialist Centre patient ID Number: 817811
2. Glenmore Specialist Centre contact person name and phone number: Contact Name: Javier Giordano Phone Number: 650 471 9575 ext. 8482

(Continued on next page)

Sunnymede Family Practice™

Physician Information Skyrizi (risankizumab)

Note to Physician: In order to assess a patient's claim for this drug, we require detailed information on the patient's prescription drug history as requested below.

Attach extra information if necessary. GENETIC TEST RESULTS ARE NOT REQUIRED

Physician's Information (please print) Name of prescribing physician: Dr. Santiago Fitzgerald Specialty: Gastroenterology Address (number, street, city, province, postal code): 368 River Rd Quebec ON U4U 5X1 Telephone Number (including area code): (624) 837-1465 Fax Number (including area code): (624) 837-1465

1. Prescribed dosage and regimen: [ ] 150mg administered SC at Week 0, Week 4, and every 12 weeks thereafter [X] 600mg administered IV at Week 0, Week 4, and week 8 followed by 360mg administered subcutaneously at Week 12, and every 8 weeks thereafter [ ] Other (please specify): (blank) Provide rationale: (blank)

2. Health Canada indication (include date of initial diagnosis) (MM/YYYY): (blank) [X] Crohn's Disease [ ] Plaque Psoriasis [ ] Psoriatic Arthritis Complete questions 1 – 6 and Physician's Information [ ] Other (approved by Health Canada): (blank) Complete questions 1 – 6 and Other condition (Health Canada approved) [ ] Other (prescribed use is not approved by Health Canada): (blank) Complete questions 1 – 6 and Off-label use

3. What is the anticipated duration of treatment with this drug? onoging

4. Where will treatment be administered? [X] Home [ ] Physician's Office [X] Private clinic [ ] Hospital in-patient [ ] Hospital out-patient

5. Please provide medical rationale why this drug has been prescribed instead of an alternate drug in the same therapeutic class: Tried and failed Remicade, Prednisone, Entyvio and Entocort.

(Continued on next page)

Sunnymede Family Practice™

Physician Information Skyrizi (risankizumab)

Physician's Information (continued) (please print)

6. Drug and Treatment History – must be completed for every request. If coverage for these drugs was not provided by Sunnymede Family Practice, please submit a pharmacy printout for the last 12 months.

Drug(s) and Treatment(s) past and present	Dosing Regimen	Start Date (DD/MM/YYYY)	End Date (DD/MM/YYYY)	Clinical Results/Outcome
Remicade	300mg IV q8w	Dec 5, 2022	Jan 2, 2024	[ ] Failure [X] Intolerance [ ] Other Clinical details: discontinued due to anti TNF induced psoriasis
Prednisone	60mg OD	May 3, 2022	Taper	[X] Failure [ ] Intolerance [ ] Other Clinical details: LOE
Entocort	9mg OD	Mar 8, 2022	May 3, 2022	
Entyvio	300mg IV q8w	Apr 12, 2022	May 3, 2022	[ ] Failure [ ] Intolerance [ ] Other Clinical details: discontinued due to increase in abd pain and bm's

Crohn's Disease

Will Skyrizi be used in concurrently with any other biologic immunosuppressant (e.g. adalimumab, infliximab, etc.)? [ ] Yes [X] No

Does the patient have a diagnosis of moderate or severe Crohn's Disease? [X] Yes [ ] No

Site of disease and complications: Ileocolonic

Has the patient had a trial of at least one of the following drugs for a minimum of 12 weeks? [X] Yes [ ] No

Select the drugs: [ ] 6-mercaptopurine [ ] azathioprine [ ] methotrexate PO [ ] methotrexate IM or SC* [X] prednisone [X] other: Entocort

*Patients who experience gastrointestinal intolerance to PO methotrexate must have a trial of parenteral methotrexate (IM or SC) to be considered an adequate trial.

If no, please provide medical rationale as to why these medications have not been tried: Also failed Remicade and Entyvio

Please ensure the Drug and Treatment History Chart is completed (include daily steroid dose).

Was Skyrizi started in hospital? [ ] Yes [X] No

If yes, provide one of the following scores prior to Skyrizi start:

HBI: 4 Date determined (DD/MM/YYYY): Jan 3, 2024

CDAI: (blank) Date determined (DD/MM/YYYY): (blank)

Rationale for lower HBI: Switching due to severe anti TNF induced psoriasis with her FCD. Open hemicolectomy resection in July 2022

Did patient receive a trial of IV steroids for a minimum of 3 days while hospitalized? [ ] Yes [ ] No

---

Sunnymede Family Practice™

Physician Information Skyrizi (risankizumab)

Plaque Psoriasis

% BSA: _____

Areas of body involved: _____

Current result and date of the following scores (DD/MM/YYYY): _____ DLQI: _____ PASI: _____

Has the patient had an adequate trial of one of the following for a minimum of 12 weeks? [ ] Yes [ ] No

Select one: [ ] acitretin [ ] cyclosporine [ ] methotrexate PO [ ] methotrexate IM or SC* [ ] other: _____

*Patients who experience gastrointestinal intolerance to PO methotrexate must have a trial of parenteral methotrexate (IM or SC) to be considered an adequate trial.

If no, please provide medical rationale as to why these medications have not been tried:

Please ensure Drug and Treatment History Chart is completed.

Psoriatic Arthritis

Swollen and tender joint count: _____

Current result and date of one of the following scores (DD/MM/YYYY):_____ HAQ: _____ BASDAI: _____

Has the patient had a trial of two of the following DMARDs for 12 weeks each? [ ] Yes [ ] No

Select the drugs: [ ] hydroxychloroquine [ ] leflunomide [ ] methotrexate PO [ ] methotrexate IM or SC* [ ] sulfasalazine [ ] other: _____

*Patients who experience gastrointestinal intolerance to PO methotrexate must have a trial of parenteral methotrexate (IM or SC) to be considered an adequate trial.

If no, please provide medical rationale as to why these medications have not been tried:

Please ensure Drug and Treatment History Chart is completed.

Other condition (Health Canada approved)

Please provide any relevant information related to the disease and attach supporting documentation.

Sunnymede Family Practice™

Physician Information Skyrizi (risankizumab)

Off-label use

Questions 1 - 6 must be completed.

Date of initial diagnosis (DD/MM/YYYY): _____

Is there clinical evidence supporting the off-label use of this drug? [ ] Yes [ ] No

Provide clinical literature/studies to support the request for off-label use, such as:

- At least two Phase II or two Phase III clinical trials showing consistent results of efficacy; and
- Published recommendations in evidence-based guidelines supporting its use.

Provide medical rationale why this drug has been prescribed off-label instead of an alternate drug with an approved indication for this condition.

Provide any pertinent medical history or information to support this off-label request.

If this is a renewal request, provide documentation showing treatment efficacy since previous request.

Note for Physician: To be eligible for reimbursement, Sunnymede Family Practice may require your patient to purchase a drug requiring prior authorization from a pharmacy designated by Sunnymede Family Practice. If applicable, a health case manager will contact you with further information.

I certify that the information provided is true, correct, and complete.

Physician's Signature: Santiago Fitzgerald Date: Jan 9, 2024

Fatima Pham

It is important to provide the requested information in detail to help avoid delay in assessing claims for the above drug. This form may be subject to audit. The completed form can be returned to Sunnymede Family Practice by mail, fax, or email.

Note: As email is not a secure medium, any person with concerns about their prior authorization form/medical information being intercepted by an unauthorized party is encouraged to submit their form by other means.

Mail to: Lakeshore Specialty Clinic Drug Claims Management 209 Wellington Blvd a nearby city 3 MB a nearby city 3

Fax to: Lakeshore Specialty Clinic Attention: Drug Claims Management Fax 857-925-9092

Email to: selin.perron70@ridgewayfamilyhealth.ca Attention: Drug Claims Management

M6453(SKYRIZI)-8/23

Glenmore Specialist Centre with you™ Support Program

FOR YOUR RECORDS

Program Enrollment

SKYRIZI

TO: Dr. Santiago Fitzgerald FAX: (624) 837-1465 DATE: Jan 3, 2024 PATIENT: Lucia Alvarez PATIENT DATE OF BIRTH: Sep 5, 1957 PATIENT FILE NUMBER:

Dear Dr. Fitzgerald,

This is to confirm that Glenmore Specialist Centre has received the enrollment form for your patient Lucia Alvarez. Every Glenmore Specialist Centre patient is assigned a unique ID number. This patient's ID number is 817811.

Glenmore Specialist Centre is now working to arrange drug plan coverage for SKYRIZI for your patient. Should we experience any undue delays in this process, you will be notified immediately.

Please do not hesitate to contact me if I can be of further assistance at **463.566.5854 ext. 7812** or **857-925-9092**.

Sincerely,

Renata Bordeaux

Field Case Manager

[image] Glenmore Specialist Centre (624) 837-1465 9 AM to 5 PM, Monday through Friday

[image] www.birchwoodcareclinic.ca

[image] MEMBER OF Glenmore Specialist Centre

Glenmore Specialist Centre with you™

The information contained in the transmission accompanying this notice is confidential and protected by the physician-patient privilege. It is intended only for the use of the individual or organization identified above. If the reader of this message is not the intended recipient, you are hereby notified that any dissemination or distribution of the accompanying communications is prohibited. If you have received this communication in error, please notify us immediately by telephone at (624) 837-1465 and return the original message to us at Glenmore Specialist Centre, 368 River Rd, Barrhaven, QC, BQT 3T9. CA-IMM-210115A - November 2021

Glenmore Specialist Centre with you™ Support Program **Enrollment form for SKYRIZI**

Please fax the completed form to (624) 837-1465. For any questions, or to register by phone, please call (624) 837-1465. Please note that the only SECURE way to transfer this information is by fax or phone.

FIELD CASE MANAGER: _____ Phone: _____ Fax: _____

PATIENT INFORMATION

First name: Lucia Alvarez Last name: Alvarez Date of birth (dd/mm/yyyy): 1957 [ ] M [X] F [ ] Other Health card number: 3062663187SX Address: 368 River Rd City: Calgary Province: ON, Canada Postal code: BQT 3T9 E-mail: fatima.pham29@fairlightmedicalcentre.ca Home phone: (624) 837-1465 Allergies: None Recorded Mobile (standard SMS rates may apply): (624) 837-1465 Language preference: [X] English [ ] French [ ] Other: _____

I acknowledge that I have read the Glenmore Specialist Centre Consent Information and Disclosure (see reverse), and that I consent to the collection, use and disclosure of my personal information in accordance with these terms.

Patient signature and date required for consent to be valid. Patient signature (or legal guardian/caregiver of patient): _____ Date (dd/mm/yyyy): DD/MM/YYYY [ ] Please check here if you do not want to be contacted for market research purposes.

PHYSICIAN INFORMATION (to be completed by the physician)

Name: Santiago Fitzgerald Tariq Barnes Address: 368 River Rd City: Quebec Province: ON, Canada Postal code: U4U 5X1 Phone: (624) 837-1465 Fax: (624) 837-1465 Clinic stamp:

I hereby acknowledge that I am the patient's attending physician. I authorize Glenmore Specialist Centre to be my designated agent to forward this prescription by fax, or other mode of delivery, to the pharmacy chosen by the above named. This prescription represents the original prescription drug order. The patient's chosen pharmacy is the only intended recipient and there are no others. Physician signature: [signature] Date (dd/mm/yyyy): [REDACTED-DATE] [X] An authorized representative/legal guardian may provide consent and sign this enrollment form on behalf of my patient.

SKYRIZI Rx (check a diagnosis and dosage)

CROHN'S DISEASE

INDUCTION DOSE	MAINTENANCE DOSE
[X] **600 mg administered by intravenous infusion at Week 0, Week 4 and Week 8.**	[X] **360 mg administered by subcutaneous injection at Week 12 and every 8 weeks after.**
Other directives/notes: _____	**Refills:** x 12 months

CROHN'S DISEASE ASSESSMENT DETAILS (CDAI, SF, APS, SES-CD)

TB TEST

[X] Completed Date (dd/mm/yyyy): [REDACTED-DATE] Result: _____ [ ] Required [X] Not required

PREVIOUS TREATMENT (check all that apply)

[X] **Corticosteroids** [ ] **Immunomodulators** [X] **Biologic** — Remicade — [ ] **Other** resection July 2022

PATIENT IS MEDICALLY CLEARED TO START THERAPY [X] **Yes** [ ] **No** Notes:

CDAI: Crohn's Disease Activity Index; SF: average daily stool frequency; APS: average daily pain score; SES-CD: Simple Endoscopic Score for Crohn's disease; TB: tuberculosis.

Glenmore Specialist Centre with you™ Support Program **Enrollment form for SKYRIZI**

Please fax the completed form to (624) 837-1465. For any questions, or to register by phone, please call (624) 837-1465. Please note that the only SECURE way to transfer this information is by fax or phone.

Glenmore Specialist Centre Consent Information and Patient Disclosure

By signing this form requesting enrollment in Harbour Medical Centre Glenmore Specialist Centre (the Lakeshore Specialty Clinic), you agree that Lakeshore Specialty Clinic (Harbour Medical Centre) or its affiliated companies or service providers appointed by Harbour Medical Centre (collectively, the Program Administrators) may provide you with the Glenmore Specialist Centre services as outlined in this enrollment form and provide you with relevant information to help better support you with your new therapy.

You understand the nature of your consent and that your enrollment is voluntary. You are free to withdraw your consent and discontinue participation in the Lakeshore Specialty Clinic at any time, without giving any reason. Your medical care or legal rights will not be affected. Below we provide the key elements regarding the use of personal information by the Program Administrators.

What is the Lakeshore Specialty Clinic?

The Lakeshore Specialty Clinic is a support program for individuals prescribed an Harbour Medical Centre Immunology product which includes:

- cost reimbursement assistance;
- education and training;
- therapy administration assistance;
- limited market research (for example, conducting surveys of your experience with the Program).

The Lakeshore Specialty Clinic does not provide medical advice and does not replace the need for you to speak with your treating physician for medical-related inquiries.

What categories of personal information does Harbour Medical Centre process about you and why?

The Program Administrators will collect, process, and use your personal information for a range of different purposes.

What personal information is used?

The Program Administrators will use information gathered about you in this document as well as any additional personal information collected from you or your doctor, nurse, pharmacy or other healthcare providers, or insurers, such as:

- name, address, phone number, and other contact details;
- sensitive information, such as information regarding the use of our service and health-related information.

Why is your personal information used and by whom?

The Program Administrators may collect, use and disclose your personal information to your pharmacist, your insurer, your doctor, your nurse and other healthcare providers for the following purposes:

- administration of the Lakeshore Specialty Clinic;
- delivery of products and services;
- helping you to access your medication, treatment;
- tailoring the Lakeshore Specialty Clinic to your specific needs;
- contacting your healthcare providers and providing them with information about your Harbour Medical Centre medication and participation in the Lakeshore Specialty Clinic;
- reminding you to take your medication(s) as prescribed;
- providing you with materials relating to your medication, treatment and the Lakeshore Specialty Clinic;
- contacting you to inform you of changes in the Lakeshore Specialty Clinic and to collect your feedback on the Lakeshore Specialty Clinic;
- for safety monitoring, reporting and auditing, and responding to enquiries or issues in relation to your medication, or as otherwise may be required by law.

The Program Administrators may also use de-identified information gathered through the Program and pool your information with the information of other persons to:

- help us develop, evaluate or improve the Lakeshore Specialty Clinic, our products, services, materials and treatment; and
- to conduct research, including future scientific research and publications.

Disclosures and transfers

Harbour Medical Centre requires its service providers to process your personal information in accordance with this consent and for no other purpose.

Harbour Medical Centre may provide metrics and analytical information about the Program to its affiliated companies and/or its parent company Lakeshore Specialty Clinic regarding how the Program is working. This

information is aggregated and does not identify you individually.

Your personal information may be transferred to another company or to a third party in connection with the sale or transfer of all or a portion of the Program Administrators' respective business.

Your personal information may be stored or processed outside of Canada. If this is the case, then your information would be subject to the laws of that country where it is stored. That country may have laws that require that your personal information be disclosed to the government under different circumstances than would Canada.

What rights do you have in respect of your personal information and who can you contact for questions?

Harbour Medical Centre collects, uses, discloses and protects your personal information in accordance with its privacy policies. You have a number of rights in relation to your information. These include a right to access and to correct, restrict, transfer and erase your information. To exercise these rights or to withdraw your consent or opt out of any of the Glenmore Specialist Centre services, or the data processing activities, or, to obtain a copy of Harbour Medical Centre privacy policy, you can submit a written request to tariq.barnes98@maplehealthclinic.ca or Legal Services, 209 Wellington Blvd, a nearby city 2, a nearby city 6, a nearby city 2. Please understand that if you withdraw your consent, you may no longer be able to participate in the Lakeshore Specialty Clinic or receive certain of its services.

Harbour Medical Centre has implemented appropriate technical and organizational security measures to protect your personal information against accidental or unlawful destruction or accidental loss, alteration, unauthorized disclosure, or access. Subject to consent and notice requirements, Harbour Medical Centre reserves the right to change its policies and practices regarding personal information and its service providers.

You understand that Harbour Medical Centre reserves the right to change or terminate the Lakeshore Specialty Clinic or any of its patient support services, at any time, at Harbour Medical Centre sole discretion without notice to you.

This consent is valid for as long as you receive services from the Lakeshore Specialty Clinic and for a reasonable time thereafter. Your personal information will be kept for the duration of your participation in the Lakeshore Specialty Clinic and will thereafter be deleted in accordance with our document retention policies, subject to legal and regulatory requirements.

Glenmore Specialist Centre with you™

© Lakeshore Specialty Clinic Printed in Canada CA-SKZG-220058A / OC22 MEMBER OF Glenmore Specialist Centre

REVIEWED BY PAAB

www.fairlightmedicalcentre.ca

Skyrizi® (risankizumab) injection 2

[image] --

This task has been completed

Patient	Alvarez, Lucia	**Task Created By**	[REDACTED-STAFF-PROVIDER-NAME-OR-USERNAME]
Date Due	[REDACTED-DATE]	**Priority**	Urgent

Assigned To	[REDACTED-STAFF-PROVIDER-NAME-OR-USERNAME]	**Completed**	2024-Jan-12 by [REDACTED-STAFF-PROVIDER-NAME-OR-USERNAME]

Notes anti tnf induced psoriasis pls switch from remicade to skyrizi asap

Fitzgerald, Jan 2, 2024 10:35am Eyetf Efcgwg please see above.

noted Eyetf Efcgwg

Fitzgerald, Jan 3, 2024 1:47pm starting process and requesting to start ASAP. [REDACTED-STAFF-OR-PROVIDER-NAME] do you know of or are you able to prescribe anything that can help with this psoriasis? She advised that it's terrible and has never been this bad. Doesn't have f/up with derm until end of Feb

needs to ask her GP - perhaps they could try something in the meantime

2024-Jan-07(hwqwemu): pt went into the ER over the weekend as she could not handle the psoriasis - they have started her on a tapering course of Prednisone...starting at 40mg. She just wanted you to be aware

---

[X] Patient Question

This task has been completed

Patient	Alvarez, Lucia	**Task Created By**	[REDACTED-STAFF-OR-PROVIDER-NAME]
Date Due	[REDACTED-DATE]	**Priority**	Urgent
Assigned To	[REDACTED-STAFF-PROVIDER-NAME-OR-USERNAME]	**Completed**	2024-Jan-02 by [REDACTED-STAFF-PROVIDER-NAME-OR-USERNAME]

Notes Lucia has her Remicade today but would like to consider a change in medication after that.. her rash is worse now and is covering basically her whole body she says. She said you discussed a potential switch and she would like to maybe start the process...please advise hwqwemu

Lab Results: Generated On 2026-Apr-28

Patient	Alvarez, Lucia	**HomePhone**	496-380-7749	**WorkPhone**	
Health #	7811 918 750	**Sex**	F	**Patient ID**	817811
Age	68 years				
DOB	1957				

Accession Id: S389666AE36 (Final) Ordered By: Santiago Fitzgerald Reported By: Glenmore Specialist Centre Collection Date: 2024-Jan-01 Reviewed: 2024-Jan-02 by [REDACTED-STAFF-PROVIDER-NAME-OR-USERNAME] Service Date: 2024-Jan-01 Report Date: 2024-Jan-02 3:33 AM

CC: Santiago Fitzgerald Updated On: 2024-Jan-02 9:34 AM

	Results	**Flags**	**Ref Range**		**Test Loc**
RENALASSESSMENT==========					
CREATININE	78		50 - 100	umol/L	10
eGFR	69				
	An eGFR from 60-89 ml/min/1.73 m2 is consistent with mildly decreased kidney function. However, in the absence of other evidence of kidney disease, eGFR values in this range do not fulfill the KDIGO criteria for chronic kidney disease. Interpret results in concert with ACR measurement. 				
	Effective May 3, 2015, eGFR is calculated using the CKD-EPI 2009 equation.				

	Results	Flags	Ref Range		Test Loc
	KDIGO 2012 guidelines highlight the importance of eGFR and urine albumin creatinine ratio (ACR) in screening, diagnosis and management of CKD. Results for eGFR should be interpreted in concert with ACR.				

760 Sherwood Ave (791) 442-5889

Accession Id: S389666AE36 (Final) Ordered By: Santiago Fitzgerald Reported By: Glenmore Specialist Centre Collection Date: 2024-Jan-01 Reviewed: 2024-Jan-02 by [REDACTED-STAFF-PROVIDER-NAME-OR-USERNAME] Service Date: 2024-Jan-01 Report Date: 2024-Jan-02 3:33 AM

CC: Santiago Fitzgerald Updated On: 2024-Jan-02 9:34 AM

	Results	Flags	Ref Range		Test Loc
ROUTINE CHEMISTRY					
ASPARTATE TRANSAMINASE(AST)	32	HI	< 30	U/L	10
ALANINE TRANSAMINASE (ALT)	35		< 36	U/L	
ALKALINE PHOSPHATASE	62		35 - 120	U/L	

760 Sherwood Ave (791) 442-5889

Accession Id: S389666AE36 (Final) Ordered By: Santiago Fitzgerald Reported By: Glenmore Specialist Centre Collection Date: 2024-Jan-01 Reviewed: 2024-Jan-02 by [REDACTED-STAFF-PROVIDER-NAME-OR-USERNAME] Service Date: 2024-Jan-01 Report Date: 2024-Jan-02 3:33 AM

CC: Santiago Fitzgerald Updated On: 2024-Jan-02 9:34 AM

	Results	Flags	Ref Range		Test Loc
ROUTINE CHEMISTRY					
TOTAL BILIRUBIN	14		< 20	umol/L	10
DIRECT BILIRUBIN:CONJUGATED	4		< 7	umol/L	
IRON	10.5	LO	10.6 - 33.8	umol/L	
TRANSFERRIN	2.11		2.00 - 4.00	g/L	
TIBC	53		50 - 100	umol/L	

	Results	Flags	Ref Range		Test Loc
TRANSFERRIN SATURATION	0.20		0.13 - 0.50		

760 Sherwood Ave 857-925-9092

Accession Id: S389666AE36 (Final) Ordered By: Santiago Fitzgerald Reported By: Glenmore Specialist Centre Collection Date: 2024-Jan-01 Reviewed: 2024-Jan-02 by [REDACTED-STAFF-PROVIDER-NAME-OR-USERNAME] Service Date: 2024-Jan-01 Report Date: 2024-Jan-02 3:33 AM

CC: Santiago Fitzgerald Updated On: 2024-Jan-02 9:34 AM

	Results	Flags	Ref Range		Test Loc
ROUTINE CHEMISTRY					
ALBUMIN	46		35 - 52	g/L	10
C-REACTIVE PROTEIN	3.1		< 5.0	mg/L	
	Test method: Abbott Alinity CRP, suitable for cardiovascular disease assessment and detection of active inflammation. CRP >=2.0 mg/L is a risk-enhancing factor for cardiovascular disease, as defined in the Guidelines of the American Heart Association and the American College of Cardiology (JACC 2019; 74: e177).				

760 Sherwood Ave 857-925-9092

Accession Id: S389666AE36 (Final) Ordered By: Santiago Fitzgerald Reported By: Glenmore Specialist Centre Collection Date: 2024-Jan-01 Reviewed: 2024-Jan-02 by [REDACTED-STAFF-PROVIDER-NAME-OR-USERNAME] Service Date: 2024-Jan-01 Report Date: 2024-Jan-02 3:33 AM

CC: Santiago Fitzgerald Updated On: 2024-Jan-02 9:34 AM

	Results	Flags	Ref Range		Test Loc
CHEMISTRY					
FERRITIN	976	HI	15 - 272	ug/L	10
	<15 ug/L: diagnostic of iron deficiency 15-30 ug/L: probable iron deficiency >30 ug/L: iron deficiency unlikely >100 ug/L: normal iron stores =>600 ug/L: consider test for iron overload				

760 Sherwood Ave 857-925-9092

Accession Id: S389666AE36 (Final) Ordered By: Santiago Fitzgerald Reported By: Glenmore Specialist Centre Collection Date: 2024-Jan-01 Reviewed: 2024-Jan-02 by [REDACTED-STAFF-PROVIDER-NAME-OR-USERNAME] Service Date: 2024-Jan-01 Report Date: 2024-Jan-02 3:33 AM

CC: Santiago Fitzgerald Updated On: 2024-Jan-02 9:34 AM

	Results	Flags	Ref Range		Test Loc
HEMATOLOGY I					
WBC	5.3		4.0 - 11.0	x E9/L	10
RBC	4.65		4.00 - 5.10	x E12/L	
HEMOGLOBIN	149		120 - 160	g/L	
HEMATOCRIT	0.428		0.350 - 0.450	L/L	
MCV	92		80 - 100	fL	
MCH	32.0		27.5 - 33.0	pg	
MCHC	348		305 - 360	g/L	
RDW	12.3		11.5 - 14.5	%	
PLATELET COUNT	250		150 - 400	x E9/L	

760 Sherwood Ave 857-925-9092

Accession Id: S389666AE36 (Final) Ordered By: Santiago Fitzgerald Reported By: Glenmore Specialist Centre

---

Collection Date: 2024-Jan-01 Reviewed: 2024-Jan-02 by [REDACTED-STAFF-PROVIDER-NAME-OR-USERNAME] Service Date: 2024-Jan-01 Report Date: 2024-Jan-02 3:33 AM

CC: Santiago Fitzgerald Updated On: 2024-Jan-02 9:34 AM

	Results	Flags	Ref Range		Test Loc
HEMATOLOGY II					
NEUTROPHILS	4.0		2.0 - 7.5	x E9/L	10
LYMPHOCYTES	0.9	LO	1.0 - 3.5	x E9/L	
MONOCYTES	0.4		0.2 - 1.0	x E9/L	
EOSINOPHILS	0.1		0.0 - 0.5	x E9/L	

	Results	Flags	Ref Range		Test Loc
BASOPHILS	0.0		0.0 - 0.2	x E9/L	
IMMATURE GRANULOCYTES	0.0		0.0 - 0.1	x E9/L	
NRBC	0			/100 WBC	
	NOTE: As of JUL 3, 2023 Glenmore Specialist Centre' pediatric reference ranges have been updated to reflect the following published resource: Bohn, et al. Int J Lab Hematol. 2020;00:1-11.				

760 Sherwood Ave 857-925-9092

P-4984283129 PG-4034849540

Lakeshore Specialty Clinic®

Post-infusion Feedback Report (For referring physician's review)

1. PATIENT INFORMATION

Last Name of Patient:	First Name of Patient:	Date of birth: (DD/MM/YYYY)
Alvarez	Lucia (Hospital ID:)	05/09/1957

2. INFUSION CONFIRMATION REPORT

TO: Prescribing Physician:: Santiago Fitzgerald Fax #: (624) 837-1465

FROM: Infusion Location: Lakeshore Specialty Clinic Contact Person: Wregdm Mumbqv Fax #: (791) 442-5889 Phone #: (791) 442-5889

3. IMMUNOSUPPRESSANTS (IF APPLICABLE)

Dose: (mg, Frequency, and Route)

4. Lakeshore Specialty Clinic® CLINIC AND COORDINATOR INFORMATION

Name of Lakeshore Specialty Clinic Clinic: Lakeshore Specialty Clinic Phone #: (791) 442-5889 Lakeshore Specialty Clinic® Coordinator Name: Eyetf Efcgwg Fax #: (791) 442-5889

5. INFUSION INFORMATION

Remicade Dose Given: Weight 51.60kg /113.76 lbs 500.00 mg exact dose Induction Dose: Yes [ ] No [X]

Date of Infusion:	Lot #	Infusion Frequency:	Next Infusion Scheduled
01/01/2024	S389666AE36 exp. al-2026	q6weeks	12/02/2024
(DD/MM/YYYY)			(DD/MM/YYYY)

TDM Serum Draw Completed : Not requested

| PREMEDICATION | PRESCRIBED | ADMINISTERED | | :--- | :--- | :--- | :--- | :--- | | | **DOSE** | **ROUTE** | **DOSE** | **ROUTE** | **PATIENT REFUSED?** |

INFUSION REACTION INFORMATION

Was there an infusion reaction? : No Adverse Event Reported to Manufacturer? : Not Applicable

7. PLEASE ASK PATIENT

Last Blood Test Performed: (DD/MM/YYYY)	Last Referring Physician Visit: (DD/MM/YYYY)	Next Referring Physician Visit: (DD/MM/YYYY)
01/01/2024	Unknown	Unknown

8. INFUSION ADMINISTRATION

Name of On-Call Medical Backup Physician:	Name of Infusion Nurse:	Infusion Nurse's Signature/Date:
Dr. Fitzgerald	Wregdm Mumbqv	
		(DD/MM/YY)

This form contains confidential and personal information and is intended only for the individual or entity named in the address. If you are not the intended recipient and have received this form in error, please notify the sender and delete this form. Unauthorized use or disclosure of this form is prohibited and may be unlawful.

Remicade INFLIXIMAB / Simponi IV golimumab for infusion / Stelara ustekinumab

Patient: Lucia Alvarez PHN: 3062663187SX DOB: 1957

Sunnymede Family Practice

Glenmore Specialist Centre Laboratory Requisition Requisitioning Clinician / Practitioner

Name Dr. Santiago Fitzgerald

Address 760 Sherwood Ave

Laboratory Use Only

Clinician/Camille Cormier CPSO / Registration No.

Clinician/Practitioner's Contact Number for Urgent Results (624) 837-1465

Service Date yyyy [blank] mm [blank] dd [blank]

Check (□) one: [X] OHIP/Insured [ ] Third Party / Uninsured [ ] WSIB

Health Number: 3062663187SX Version: [blank] Sex: F Date of Birth: 1957

Additional Clinical Information (e.g. diagnosis) [ ] Fast for 12 hours [ ] Fast Overnight PLEASE DO WITH Dec 2023 INFUSION

Province: ON Other Provincial Habiba Lindgren Patient's Telephone Contact Number: (624) 837-1465

Patient's Last Name (as per OHIP Card) Alvarez

Patient's First & Middle Names (as per OHIP Card) Lucia Alvarez

[X] Copy to: Clinician/Practitioner Last Name: Fitzgerald First Name: Santiago Address: 760 Sherwood Ave

Patient's Address (including Postal Code) 368 River Rd Calgary ON BQT 3T9

Note: Separate requisitions are required for cytology, histology / pathology and tests performed by Public Health Laboratory

x	**Biochemistry**	x	**Hematology**	x	**Viral Hepatitis (check one only)**
[ ]	Glucose [ ] Random [ ] Fasting	[X]	CBC	[ ]	Acute Hepatitis
[ ]	HbA1C	[ ]	Prothrombin Time (INR)	[ ]	Chronic Hepatitis
[ ]	TSH		**Immunology**	[ ]	Immune Status / Previous Exposure
[X]	Creatinine (eGFR)	[ ]	Pregnancy test (Urine)		Specify: [ ] Hepatitis A
[ ]	Uric Acid	[ ]	Mononucleosis Screen		[ ] Hepatitis B
[ ]	Sodium	[ ]	Rubella		[ ] Hepatitis C
[ ]	Potassium	[ ]	Prenatal: ABO, RhD, Antibody Screen (titre and ident. if positive)		or order individual hepatitis tests in the "Other Tests" section below
[ ]	Chloride				**Prostate Specific Antigen (PSA)**
[ ]	CK	[ ]	Repeat Prenatal Antibodies	[ ]	Total PSA [ ] Free PSA

x	Biochemistry	x	Hematology	x	Viral Hepatitis (check one only)
[X]	ALT		**Microbiology ID & Sensitivities (if warranted)**		Specify one below:
[X]	Alk. Phosphatase	[ ]	Cervical	[ ]	Insured - Meets OHIP eligibility criteria
[X]	Bilirubin total and direct	[ ]	Vaginal	[ ]	Uninsured - Screening: Patient responsible for payment
[X]	Albumin	[ ]	Vaginal / Rectal - Group B Strep		**Vitamin D (25-Hydroxy)**
[ ]	Lipid Assessment (includes Cholesterol, HDL-C, Triglycerides, calculated LDL-C & Chol/HDL-C ratio; individual lipid tests may be ordered in the "Other Tests" section of this form)	[ ]	Chlamydia (specify source):	[ ]	Insured - Meets OHIP eligibility criteria: osteopenia; osteoporosis; rickets; renal disease; malabsorption syndromes; medications affecting vitamin D metabolism
[ ]	Vitamin B12	[ ]	GC (specify source):	[ ]	Uninsured - Patient responsible for payment
[X]	Ferritin	[ ]	Sputum		**Other Tests - one test per line**
[ ]	Albumin / Creatinine Ratio, Urine	[ ]	Throat		AST - advised by hepatologist
[ ]	Urinalysis (Chemical)	[ ]	Wound (specify source):		CRP
[ ]	Neonatal Bilirubin:	[ ]	Urine		Serum iron(IBD)
	Child's Age: [blank] days [blank] hours	[ ]	Stool Culture		Iron saturation
	Clinician/Practitioner's tel. no.	[ ]	Stool Ova & Parasites		
	Patient's 24 hr telephone no.	[ ]	Other Swabs / Pus (specify source):		
	Therapeutic Drug Monitoring:				
	Name of Drug #1		**Specimen Collection**		
	Name of Drug #2		Time [blank] Date YYYY-MMM-DD		
	Time Collected #1 [blank] hr. #2 [blank] hr.		**Fecal Occult Blood Test (FOBT) (check one)**		
	Time of Last Dose #1 [blank] hr. #2 [blank] hr.	[ ]	FOBT (non CCC)	[ ]	ColonCancerCheck FOBT (CCC) no other test can be ordered on this form

x	Biochemistry	x	Hematology	x	Viral Hepatitis (check one only)
	Time of Next Dose #1 [blank] hr. #2 [blank] hr.		**Laboratory Use Only**		

I hereby certify the tests ordered are not for registered in or out patients of a hospital.

X [signature] Clinician/Practitioner Signature

2023-Dec-03 Date

817811 (2010/09) ©Glenmore Specialist Centre, 2010 817811

[X] Follow-up Appt.

This task has been completed

Patient	Alvarez, Lucia	**Task Created By**	[REDACTED-STAFF-PROVIDER-NAME-OR-USERNAME]
Date Due	11/27/2023	**Priority**	Very Urgent
Assigned To	[REDACTED-STAFF-OR-PROVIDER-NAME]	**Completed**	2023-Nov-27 by [REDACTED-STAFF-OR-PROVIDER-NAME]
Notes	JAN/FEB 4-6 months 2023-Nov-23(hwqwemu): fitting in next week now due to rash - this [REDACTED-DATE] change... 2023-Nov-27(hwqwemu): yep, see new task		

[X] --

This task has been completed

Patient	Alvarez, Lucia	**Task Created By**	[REDACTED-STAFF-PROVIDER-NAME-OR-USERNAME]
Date Due	11/27/2023	**Priority**	Normal
Assigned To	[REDACTED-STAFF-OR-PROVIDER-NAME]	**Completed**	2023-Dec-03 by [REDACTED-STAFF-OR-PROVIDER-NAME]
Notes	ibd labs including iron sat and ferritin at next infusion f/u [REDACTED-DATE] 2023-Dec-03(hwqwemu): booked March 20th with pt, req taken next door for her next infusion, she is aware		

Patient: Mrs. Lucia Alvarez Appointment Date: 2023-Nov-27 Title: Chart Notes Provider: Fitzgerald, Santiago Referred By: Fitzgerald, Santiago Lucia was seen for reassessment and ongoing management of her Crohn's disease.

Past medical history:

1. Crohn's disease - Dx in 2001 - presented with SBO, but did not required surgery upfront. Was on 5-ASA and one course of steroids, no prior biologics until starting Entyvio . Presented to Glenmore Specialist Centre and admitted in [REDACTED-DATE] for RLQ abscess and what looks like an enterocutaneous and enterovesicular fistula. Underwent open right hemicolectomy for enteral enteral and enterocutaneous fistula with Dr. Fitzgerald July 2022. The pathology was consistent with severe Crohn's disease. No dysplasia identified. A total of 28 cm of small bowel was removed and 4 cm of colon. Fistula noted between distal TI, bladder, and abdominal wall. Infliximab started Nov 2022.
2. Possible celiac disease - DQ2 positive but not homozygous - celiac antibodies and duodenal biopsies negative.
3. Asthma
4. Hypothyroidism
5. Osteoporosis
6. Several month history bilateral arm numbness, tingling - MRI brain normal - MRI spine showed some mild narrowing, awaiting Neurologist appt in [REDACTED-DATE].

Current medications: Infliximab 500mg q6weeks (previously was 300mg q8weeks, low levels <1), Colestid 1g PO BID, Atrovent, Prolia, Vitamin D 2000 IU daily

Allergies: None.

Social history: Non-smoker, rare EtoH, no illicit drugs.

Family history: 2 children with celiac disease.

History of presenting illness: Lucia has had some ongoing issues with pruritic rashes over her ears, upper back, arm extensors over the last couple of months. She has already been referred to dermatology.

I saw some of the previous pictures and it certainly has the appearance of a psoriatic rash and I suspect it is anti-TNF induced psoriasis. She has had no change in her bowel habit or blood in the stools. No extraintestinal manifestations of IBD. Review of systems otherwise unremarkable.

Head and neck exam unremarkable. Abdomen soft, nondistended, nontender. No palpable masses, organomegaly, or stigmata of chronic liver disease. No leg swelling or erythema bilaterally.

Labs: 2023-Oct-03 - HgB 133 g/L, WBC 5.0 x E9/L, Platelets 221 x E9/L, ALT 32 U/L, AST 25 U/L, ALP 67 U/L, Bilirubin 8 umol/L, Creatinine 82 umol/L, CRP 1.3 mg/L, Iron Saturation 0.24, Ferritin 795 ug/L, Albumin 44 g/L

Previous abscess grew Klebsiella pneumo and B fragilis - sensitive to Cipro.

TDM: Infliximab TDM standard care Jul 6, 2023 was 0.89.

Endoscopic evaluation: Colonoscopy was performed on May 28, 2023 and demonstrated a widely patent ileocolonic anastomosis. 4 aphthous ulcers noted in neoterminal ileum, Rutgeerts Score of 1. Remainder of colon otherwise unremarkable.

Gastroscopy and colonoscopy on Sep 12, 2021. Unremarkable gastroscopy with gastric and duodenal biopsies taken. Colonoscopy complete to ileocecal valve at which point there was a benign narrowing of the ileocecal valve, but no active inflammation. Biopsies taken from the terminal ileum across the ileocecal valve as well as right and left colon. No active colitis. Duodenal, gastric, right and left colon biopsies normal. Terminal ileum biopsies moderate chronic colitis with small numbers of neutrophils. Rectum polyp, hyperplastic polyp.

Imaging: No imaging since OR.

CT May 6, 2022 - RLQ abscess measuring 6.9 x 1.8cm. Overall improvement from prior CT.

IR guided drainage of RLQ abscess on May 4 with placement of 10F drainage catheter.

CT May 2, 2022 - RLQ abscess measuring 8.5 x 5.1cm with fluid and gas. In communication with the bladder. Probably enterocutaneous and enterovesicular fistulae.

CT scan on Apr 21, 2022. Extensive active disease in the distal ileum. There is extensive fistula between the distal ileum, bladder, and abdominal wall.

MRI on Dec 9, 2021. Active inflammatory Crohn's disease affecting TI with 2 skip lesions identified longest measuring 12cm. No strictures, fistulas, or abscesses noted.

Impression and Plan: Lucia has what looks like mild drug-induced psoriasis and interestingly her kids have psoriasis so there may be somewhat of a genetic component as well. For now, her symptoms are quite mild and she would like to continue on infliximab but I certainly explained to her that if the symptoms should worsen or become more bothersome then certainly we could switch her to another drug in the drug of choice would probably be Skyrizi or Stelara. She has follow-up with dermatology in the next couple of months and I will follow-up with her in early spring for ongoing management.

IBD Plan:

1. Maintain up to date vaccinations with GP.
2. Avoid NSAIDs and anti-inflammatories which can cause flares of IBD, tylenol is safe.
3. Patient counselled on risks and side effects of current medical therapy.
4. Patient knows to contact me if they develop signs of a disease exacerbation including worsening abdominal pain, diarrhea, or blood in the stools.

Thank you for involving me in the care of this patient. Please don't hesitate to contact me if you have any questions or concerns.

Glenmore Specialist Centre

760 Sherwood Ave

Fax Cover Sheet

To: Dr. Santiago Fitzgerald Phone: (624) 837-1465 Fax: (791) 442-5889

Date: 2023-Nov-27

Check out our new website at www.birchwoodcareclinic.ca

From: Dr. Santiago Fitzgerald Phone: (624) 837-1465 Fax: (624) 837-1465

Number of pages including cover: 4

Re: Lucia Alvarez

Confidential: This communication is intended only for the individual or institution to which it is addressed and should not be distributed, copied or disclosed to anyone else. The documents in this communication may contain personal, confidential or privileged information, which may be subject to the Freedom of Information and Protection of Privacy Act, the Health Information Act and other legislation. If you have received this communication in error, please notify us immediately and return original transmission to us. Thank you for your co-operation and assistance.

Dr. Santiago Fitzgerald Glenmore Specialist Centre 760 Sherwood Ave Phone: (624) 837-1465 Fax: (624) 837-1465

2023-Nov-27

Dr. Santiago Fitzgerald 760 Sherwood Ave

Patient: Mrs. Lucia Alvarez PHN: 9187508760-FM Birthdate: 1957 Phone Number: (624) 837-1465, Work: (791) 442-5889 Cell: (624) 837-1465 Address: 368 River Rd, Calgary, ON BQT 3T9 Boris Halvorsen

Dear Dr. Fitzgerald,

Lucia was seen for reassessment and ongoing management of her Crohn's disease.

Past medical history:

1. Crohn's disease - Dx in 2001 - presented with SBO, but did not required surgery upfront. Was on 5-ASA and one course of steroids, no prior biologics until starting Entyvio . Presented to Glenmore Specialist Centre and admitted in [REDACTED-DATE] for RLQ abscess and what looks like an enterocutaneous and enterovesicular fistula. Underwent open right hemicolectomy for enteral enteral and enterocutaneous fistula with Dr. Fitzgerald July 2022. The pathology was consistent with severe Crohn's disease. No dysplasia identified. A total of 28 cm of small bowel was removed and 4 cm of colon. Fistula noted between distal TI, bladder, and abdominal wall. Infliximab started Nov 2022.
2. Possible celiac disease - DQ2 positive but not homozygous - celiac antibodies and duodenal biopsies negative.
3. Asthma
4. Hypothyroidism
5. Osteoporosis
6. Several month history bilateral arm numbness, tingling - MRI brain normal - MRI spine showed some mild narrowing, awaiting Neurologist appt in [REDACTED-DATE].

Current medications: Infliximab 500mg q6weeks (previously was 300mg q8weeks, low levels <1), Colestid 1g PO BID, Atrovent, Prolia, Vitamin D 2000 IU daily

Allergies: None.

Social history: Non-smoker, rare EtoH, no illicit drugs.

Family history: 2 children with celiac disease.

History of presenting illness: Lucia has had some ongoing issues with pruritic rashes over her ears, upper back, arm extensors over the last couple of months. She has already been referred to dermatology.

I saw some of the previous pictures and it certainly has the appearance of a psoriatic rash and I suspect it is anti-TNF induced psoriasis. She has had no change in her bowel habit or blood in the

---

stools. No extraintestinal manifestations of IBD. Review of systems otherwise unremarkable.

Head and neck exam unremarkable. Abdomen soft, nondistended, nontender. No palpable masses, organomegaly, or stigmata of chronic liver disease. No leg swelling or erythema bilaterally.

Labs: 2023-Oct-03 - HgB 133 g/L, WBC 5.0 x E9/L, Platelets 221 x E9/L, ALT 32 U/L, AST 25 U/L, ALP 67 U/L, Bilirubin 8 umol/L, Creatinine 82 umol/L, CRP 1.3 mg/L, Iron Saturation 0.24, Ferritin 795 ug/L, Albumin 44 g/L

Previous abscess grew Klebsiella pneumo and B fragilis - sensitive to Cipro.

TDM: Infliximab TDM standard care Jul 6, 2023 was 0.89.

Endoscopic evaluation: Colonoscopy was performed on May 28, 2023 and demonstrated a widely patent ileocolonic anastomosis. 4 aphthous ulcers noted in neoterminal ileum, Rutgeerts Score of 1. Remainder of colon otherwise unremarkable.

Gastroscopy and colonoscopy on Sep 12, 2021. Unremarkable gastroscopy with gastric and duodenal biopsies taken. Colonoscopy complete to ileocecal valve at which point there was a benign narrowing of the ileocecal valve, but no active inflammation. Biopsies taken from the terminal ileum across the ileocecal valve as well as right and left colon. No active colitis. Duodenal, gastric, right and left colon biopsies normal. Terminal ileum biopsies moderate chronic colitis with small numbers of neutrophils. Rectum polyp, hyperplastic polyp.

Imaging: No imaging since OR.

CT May 6, 2022 - RLQ abscess measuring 6.9 x 1.8cm. Overall improvement from prior CT.

IR guided drainage of RLQ abscess on May 4 with placement of 10F drainage catheter.

CT May 2, 2022 - RLQ abscess measuring 8.5 x 5.1cm with fluid and gas. In communication with the bladder. Probably enterocutaneous and enterovesicular fistulae.

CT scan on Apr 21, 2022. Extensive active disease in the distal ileum. There is extensive fistula between the distal ileum, bladder, and abdominal wall.

MRI on Dec 9, 2021. Active inflammatory Crohn's disease affecting TI with 2 skip lesions identified longest measuring 12cm. No strictures, fistulas, or abscesses noted.

Impression and Plan: Lucia has what looks like mild drug-induced psoriasis and interestingly her kids have psoriasis so there may be somewhat of a genetic component as well. For now, her symptoms are quite mild and she would like to continue on infliximab but I certainly explained to her that if the symptoms should worsen or become more bothersome then certainly we could switch her to another drug in the drug of choice would probably be Skyrizi or Stelara. She has follow-up with dermatology in the next couple of months and I will follow-up with her in early spring for ongoing management.

IBD Plan:

1. Maintain up to date vaccinations with GP.
2. Avoid NSAIDs and anti-inflammatories which can cause flares of IBD, tylenol is safe.
3. Patient counselled on risks and side effects of current medical therapy.
4. Patient knows to contact me if they develop signs of a disease exacerbation including worsening abdominal pain, diarrhea, or blood in the stools.

Patient: Lucia Alvarez PHN: 3062663187SX DOB: 1957

Thank you for involving me in the care of this patient. Please don't hesitate to contact me if you have any questions or concerns.

Sincerely,

[image]

Santiago Fitzgerald **Electronically Reviewed to Expedite Delivery**

Patient: Lucia Alvarez PHN: 3062663187SX DOB: 1957

[X] Patient Question

This task has been completed

Patient	Alvarez, Lucia	**Task Created By**	[REDACTED-STAFF-GIVEN-NAME-USERNAME]
Date Due	11/20/2023	**Priority**	Very Urgent
Assigned To	[REDACTED-STAFF-OR-PROVIDER-NAME]	**Completed**	2023-Nov-21 by [REDACTED-STAFF-OR-PROVIDER-NAME]
Notes	\ \ \ 2023-Nov-20(XG): patient called, she developed a itchy rash 1-2 weeks after remicade increase in the summer, rash on back of neck, in ears, armpit, leg, rash is worsening. GP referred to derm but no appt until end of [REDACTED-DATE]. Was seen in the infusion clinic today and nurse (Wregdm Mumbqv) advised she been seen by you. pls ask her to take some pics of the rash in case it goes away and come to see me next week one day when im on call.. maybe tues am? 2023-Nov-21(hwqwemu): pt advised, she will come in Tues AM		

D-4474057291 W-7602451830

Lakeshore Specialty Clinic

Post-infusion Feedback Report (For referring physician's review)

1. PATIENT INFORMATION

Last Name of Patient:	First Name of Patient:	Date of birth: (DD/MM/YYYY)
Alvarez	Lucia (Hospital ID:)	05/09/1957

2. INFUSION CONFIRMATION REPORT

TO: Prescribing Physician:: Santiago Fitzgerald Fax #: (624) 837-1465

FROM: Infusion Location: Lakeshore Specialty Clinic Contact Person: Wregdm Mumbqv Fax #: (791) 442-5889 Phone #: (791) 442-5889

3. IMMUNOSUPPRESSANTS (IF APPLICABLE)

Dose: (blank) (mg, Frequency, and Route)

4. Lakeshore Specialty Clinic® CLINIC AND COORDINATOR INFORMATION

Name of Lakeshore Specialty Clinic Clinic: Lakeshore Specialty Clinic Phone #: (791) 442-5889 Lakeshore Specialty Clinic® Coordinator Name: Eyetf Efcgwg Fax #: (791) 442-5889

5. INFUSION INFORMATION

Remicade Dose Given: Weight 52.50kg / 115.74 lbs 500.00 mg exact dose Induction Dose: Yes [ ] No [X]

Date of Infusion:	Lot #	Infusion Frequency:	Next Infusion Scheduled
20/11/2023	W-7602451830 exp. [REDACTED-DATE]	q6weeks	01/01/2024
(DD/MM/YYYY)			(DD/MM/YYYY)

TDM Serum Draw Completed : Not requested

PREMEDICATION	PRESCRIBED	ADMINISTERED
	DOSE	ROUTE

INFUSION REACTION INFORMATION

Was there an infusion reaction? : No Adverse Event Reported to Manufacturer? : Yes

7. PLEASE ASK PATIENT

Last Blood Test Performed: (DD/MM/YYYY)	Last Referring Physician Visit: (DD/MM/YYYY)	Next Referring Physician Visit: (DD/MM/YYYY)
Unknown	Unknown	Unknown

8. INFUSION ADMINISTRATION

Name of On-Call Medical Backup Physician:	Name of Infusion Nurse:	Infusion Nurse's Signature/Date:
Dr. Fitzgerald	Wregdm Mumbqv	(blank)
		(DD/MM/YY)

This form contains confidential and personal information and is intended only for the individual or entity named in the address. If you are not the intended recipient and have received this form in error, please notify the sender and delete this form. Unauthorized use or disclosure of this form is prohibited and may be unlawful.

[image] Remicade [image] Simponi Aria [image] Stelara Sunnymede Family Practice 210 Glenarm Ave | Calgary, ON Page 1 of 1 w www.stonebridgehealthclinic.ca Patient: Lucia Alvarez PHN: 3062663187SX DOB: 1957 **Sunnymede Family Practice** [image]

Ref ID: W-7602451830 Submitted by: wren.weaver26@stonebridgehealthclinic.ca Company or Vendor Name: Sunnymede Family Practice

Complaint

Vendor Number	
Is this a possible Adverse Event or Special Situation?	Yes
Is this a possible Product Quality Complaint?	No
Was this complaint reported from a J&J program?	No

Vendor Number	
When was J&J first notified of this complaint?	Nov 20, 2023
Provide the narrative or additional information here	Patient arrived for their scheduled infusion. Patient reports experiencing a rash. Patient reports that the rash began "2 weeks after my remicade dose increase in the summer". Patient reports an itchy rash on both arms, legs, and upper back. Patient states that these rashes "Seem to appear after each infusion". Rash appears as small, red circular spots. Patient states that the spots don't go away once they appear. Patient states they have been in contact with their GP and prescribed antihistamine + cortisone cream PRN. GP also referred patient for dermatology consult in January 2024. Patient states that she hasn't informed her GI MD about this yet. Writer informed patient that a copy of this report will go to the MD but writer encouraged patient to also call GI MD in case patient wants to have further discussions about it with MD. Patient received infusion today with no concerns.

Reporter Details

Details about the person who informed you of this complaint 1

Select the person who informed you of this complaint	**Patient**
Has the Patient provided permission to contact the physician or treating HCP?	No
Is the physician or treating HCP aware of the complaint?	
Title	
First Name	Asked but Unknown
Last Name	Asked but Unknown
Facility Name	
Address Line 1	
Address Line 2	
City	
County	
State	
Postal Code	
Country	CANADA
Telephone	
Fax	
Email Address	
Did the reporter administer the product?	Yes
Does J&J have permission to contact the reporter?	No

Select the person who informed you of this complaint	Patient
Did the reporter send this report to the FDA?	

Suspect Products

Page 1 of 6 Date of Report 20-Nov-2023 20:16 Patient: Lucia Alvarez PHN: 3062663187SX DOB: 1957 Page 1 of 6

Ref ID : W-7602451830 Submitted by : wren.weaver26@stonebridgehealthclinic.ca

Products 1(Primary Suspect Product)

J&J Product Name	REMICADE [Drug] [Solution for infusion]
Product purchased in	CANADA
Vaccine Anatomical Approach Site	
Was the product stored in appropriate temperature conditions? and was it properly stored from receipt to administration? If not, please explain (ex: delay in cold storage, temperature excursions, etc .)	
Please Explain	
If a multidose vial, how many times, and for how long (cumulative), was the vaccine removed from storage?	
What was the formulation?	Solution for infusion
Indication	
What was the route of administration?	
What action was taken in response to the complaint?	
Was this part of the CAR-T therapy pathway (e.g. Apheresis, bridging therapy) ?	No
When did the patient take or use the product? - Start	
When did the patient take or use the product? - End	
Is the product lot number available?	Yes
Provide the lot number of the product	W-7602451830
Provide the product expiration date	Feb 28, 2026
Is the product sample available?	No
Provide the reason why sample is not available	Discarded
Specify Other	
Number of units involved in this Complaint	
What was the dose?	
What was the strength?	

J&J Product Name	REMICADE [Drug] [Solution for infusion]
What was the frequency?	
What was the frequency time?	
Where was the product purchased?	
Contact Phone Number for where product was purchased	
Place where product was administered	
Who administered the product?	
Provide the controlled substance number (for controlled substances only)	
Provide the GTIN number	
Provide the NDC number	

Date of Report 20-Nov-2023 20:16 Patient: Lucia Alvarez PHN: 3062663187SX DOB: 1957

Ref ID : W-7602451830 Submitted by : wren.weaver26@stonebridgehealthclinic.ca

Provide the UDI number	
Provide the Serial number	
EEA system alert number	
EEA system alert description	
Provide the Prescription number	
Is the complaint related to a specific part used to administer the product?	
Describe which specific part of the device or device component was involved	
When did the problem occur?	
Did the patient experience harm from the product problem?	
Describe the harm the patient experienced from the product problem	
Were the product instructions for use followed?	
Describe why the instructions were not followed	
Who was using the device(operator of the device)	
Was single use device reprocessed and reused?	
Usage of device	
Complaint Description	Rash
According to the reporter, is this complaint related to J&J product?	
Did the complaint abate after user stopped or the dose reduced?	
Did the complaint reappear after reintroduction?	

Provide the UDI number	
Complaint Description	Itchiness
According to the reporter, is this complaint related to J&J product?	
Did the complaint abate after user stopped or the dose reduced?	
Did the complaint reappear after reintroduction?	

Concomitant Product(s)

| Provide details if concomitant medication was used | Unknown |

Complaint Description

Complaint Description 1

| What is the complaint (e.g. adverse event, special situation or product quality complaint)? | Rash | | When did this complaint start? | | | What is the outcome of the complaint? | | | Provide the date the complaint was resolved | | | Death | |

Date of Report 20-Nov-2023 20:16 Patient: Lucia Alvarez PHN: 3062663187SX DOB: 1957

Ref ID : W-7602451830 Submitted by : wren.weaver26@stonebridgehealthclinic.ca

Permanent/Significant Disability	
Life Threatening	
Congential Anomaly/Birth Defect	
Hospitalization	
Other Serious	
Emergency room/department or Urgent care	
Doctor/healthcare professional office	
Serious Injury/Death by device	
Requires medical or surgical intervention to prevent permanent damage	
Non Serious	

Complaint Description 2

What is the complaint (e.g. adverse event, special situation or product quality complaint)?	**Itchiness**
When did this complaint start?	
What is the outcome of the complaint?	
Provide the date the complaint was resolved	
Death	

What is the complaint (e.g. adverse event, special situation or product quality complaint)?	Itchiness
Permanent/Significant Disability	
Life Threatening	
Congential Anomaly/Birth Defect	
Hospitalization	
Other Serious	
Emergency room/department or Urgent care	
Doctor/healthcare professional office	
Serious Injury/Death by device	
Requires medical or surgical intervention to prevent permanent damage	
Non Serious	

Date of Death	
What was the cause of death?	
Was autopsy performed?	
Provide the results of autopsy	
Hospital admission date	
Hospital discharge date	
Number of Days	
Hospital Name	
Hospital City	
Hospital State	

Patient

Date of Report 20-Nov-2023 20:16 Patient: Lucia Alvarez PHN: 3062663187SX DOB: 1957

Ref ID : W-7602451830 Submitted by : wren.weaver26@stonebridgehealthclinic.ca

Is the reporter the patient?	Yes
Provide the patient initials	UNK
What is the gender/sex of the patient?	Female
Is the patient pregnant?	No
What is the expected due date?	
What is the last menstrual date?	
What is the gestational period of the patient	

What is the date of birth of the patient?	
What was the age of the patient at the time the complaint first occurred?	
What is the age group of the patient?	
What is the height of the patient?	
What was the weight of the patient at the time Complaint first occurred?	
Patient Race	
What is the ethnicity of the patient?	
Consent to contact the patient?	
Did the patient take the product as directed	
Provide details why the patient did not take the product as directed	

Medical History

Provide the medical history of the patient	
Does the patient have any allergies?	
Provide details of the allergies	
Was there drug abuse or illicit drug usage?	
Provide details drug abuse or illicit drug usage	
Does the patient consume alcohol?	
Provide the details(indicate consumption per day, week, month)	
Does the patient smoke?	
Provide details of cigarettes(indicate consumption per day, week, month)	

Product History

Provide details if patient has product history	Unknown

Lab Investigations

Is the patient diagnostic data available?	Unknown

Lab Test Details 1

Provide the lab test details(including Lakeshore Specialty Clinic 5, ECG, Biopsy, etc.)	

Ref ID : W-7602451830 Submitted by : wren.weaver26@stonebridgehealthclinic.ca

Date on which the lab test was conducted	
Provide results of the lab test	

Date of Report 20-Nov-2023 20:16 Patient: Lucia Alvarez PHN: 3062663187SX DOB: 1957

D-4474057291 W-7602451830

Sunnymede Family Practice BIO ADVANCE®

Post-infusion Feedback Report (For referring physician's review)

1. PATIENT INFORMATION

Last Name of Patient:	**First Name of Patient:**	**Date of birth: (DD/MM/YYYY)**
Alvarez	Lucia (Hospital ID:)	05/09/1957

2. INFUSION CONFIRMATION REPORT

TO:	**FROM:**
Prescribing Physician:: Santiago Fitzgerald Fax #: (624) 837-1465	Infusion Location: Lakeshore Specialty Clinic Contact Person: Q. Bqthtx JJ Fax #: (791) 442-5889 Phone #: (791) 442-5889

3. IMMUNOSUPPRESSANTS (IF APPLICABLE)

Dose: (mg, Frequency, and Route)

4. Lakeshore Specialty Clinic® CLINIC AND COORDINATOR INFORMATION

Name of Lakeshore Specialty Clinic Clinic: Lakeshore Specialty Clinic Phone #: (791) 442-5889	**Lakeshore Specialty Clinic® Coordinator Name: Eyetf Efcgwg Fax #: (791) 442-5889**

5. INFUSION INFORMATION

Remicade Dose Given: Weight 54.00kg /119.05 lbs 500.00 mg exact dose Induction Dose: Yes [ ] No [X]	**Date of Infusion: 09/10/2023 (DD/MM/YYYY)**	**Lot # W-7602451830 exsp [REDACTED-DATE]**	**Infusion Frequency: Q6W**	**Next Infusion Scheduled 20/11/2023 (DD/MM/YYYY)**

TDM Serum Draw Completed : Not requested

PREMEDICATION	PRESCRIBED	ADMINISTERED	PATIENT REFUSED?
	DOSE	ROUTE	DOSE

6. INFUSION REACTION INFORMATION

Was there an infusion reaction? : No Adverse Event Reported to Manufacturer? : Not Applicable

7. PLEASE ASK PATIENT

Last Blood Test Performed: (DD/MM/YYYY)	Last Referring Physician Visit: (DD/MM/YYYY)	Next Referring Physician Visit: (DD/MM/YYYY)
Unknown	Unknown	Unknown

8. INFUSION ADMINISTRATION

Name of On-Call Medical Backup Physician: Dr. Fitzgerald	Name of Infusion Nurse: Q. Bqthtx JJ	Infusion Nurse's Signature/Date: _____ (DD/MM/YY)

[image] Remicade INFLIXIMAB [image] Simponi Aria IV golimumab for infusion [image] Stelara ustekinumab

Sunnymede Family Practice 210 Glenarm Ave | Calgary, ON | S8G 4E6 | www.stonebridgehealthclinic.ca © 2016 Sunnymede Family Practice | All trademarks used under license | [illegible]

Sunnymede Family Practice [image]

Patient: Lucia Alvarez PHN: 3062663187SX DOB: 1957

Sunnymede Family Practice Sunnymede Family Practice

Lab Results: Generated On 2026-Apr-28

Patient	Alvarez, Lucia	**Tmbeykz Hkyvts Dxafav**	**Telephone**
Date of Birth	1957	W-7602451830 Sunnymede Family Practice	(791) 442-5889
Age (Time of Observation)	66 years	**Ontario Health Number**	(Primary Residence Number)
Sex	F	7811 918 750	
Address			

Lab Order #	**Ordering Practitioner**	**Primary Performing Lab**

W-7602451830 Sunnymede Family Practice	Fitzgerald, Santiago	Glenmore Specialist Centre
	(W-7602451830)	(Westbrook Medical Associates)
Last Updated in Highpark Health Centre 2	**Address**	**Address**
2023-Oct-04 11:31:46 AM EDT	a nearby city 4	368 River Rd
Specimen Received Date/Time	Quebec ON U4U 5X1	Calgary S8G 4E6 ON
2023-10-03 1:52:00 PM EDT	(Firm/Business)	(Firm/Business)
		Primary Reporting Lab
		Glenmore Specialist Centre
		(Westbrook Medical Associates)
		Address
		368 River Rd
		Calgary S8G 4E6 ON
		(Firm/Business)

Hematology

Specimen Type	Collection Date	Specimen Collected By
WHOLE BLOOD	2023-Oct-03 1:47:00 PM EDT	Sunnymede Family Practice

	Flags	Results	Reference Range	Units
Complete Blood Count				
Leukocytes; Blood		5.0	4.0 - 11.0	x E9/L
Erythrocytes; Blood		4.14	4.00 - 5.10	x E12/L
Hemoglobin; Blood		133	120 - 160	g/L
Hematocrit; Blood		0.380	0.350 - 0.450	L/L
Mean Corpuscular Volume; RBC		92	80 - 100	fL
Mean Corpuscular Hemoglobin; RBC		32.1	27.5 - 33.0	pg
Mean Corpuscular Hemoglobin Concentration; RBC		350	305 - 360	g/L
Erythrocyte Distribution Width; RBC		12.2	11.5 - 14.5	%
Platelets; Blood		221	150 - 400	x E9/L
Neutrophils; Blood		3.5	2.0 - 7.5	x E9/L
Lymphocytes; Blood		1.0	1.0 - 3.5	x E9/L
Monocytes; Blood		0.5	0.2 - 1.0	x E9/L

	Flags	Results	Reference Range	Units
Eosinophils; Blood		0.1	0.0 - 0.5	x E9/L
Basophils; Blood		0.0	0.0 - 0.2	x E9/L
Granulocytes Immature		0.0	0.0 - 0.1	x E9/L
Erythrocytes Nucleated/100 Leukocytes; Blood		0		/100 WBC

NOTE: As of JUL 3, 2023 Glenmore Specialist Centre' pediatric reference ranges have been updated to reflect the following published resource: Bohn, et al. Int J Lab Hematol. 2020;00:1-11. Glenmore Specialist Centre(Westbrook Medical Associates)

Chemistry

Collection Date	Specimen Collected By
2023-Oct-03 1:47:00 PM EDT	Sunnymede Family Practice

Iron Iron Result: Serum IRON not performed.

When both serum iron and ferritin are ordered together without a stated clinical diagnosis, only serum ferritin will be tested. Accepted clinical diagnoses include chronic inflammation, chronic kidney failure, iron overload, iron excess, hemochromatosis, hemosiderosis.

Specimen Type	Collection Date	Specimen Collected By
SERUM	2023-Oct-03 1:47:00 PM EDT	Glenmore Specialist Centre

CONFIDENTIAL - report contains Personal Health Information Generated from Highpark Health Centre 2 on 2026-04-28 13:45:35 EDT by user Pvetxd Czcxtqawts Patient: Lucia Alvarez PHN: 3062663187SX DOB: 1957

(Westbrook Medical Associates)

Transferrin Transferrin 2.10 2.00 - 4.00 g/L

Specimen Type	Collection Date	Specimen Collected By
SERUM	2023-Oct-03 1:47:00 PM EDT	Glenmore Specialist Centre
		(Westbrook Medical Associates)

Cobalamins Vitamin B12 564 138 - 652 pmol/L

> 220 pmol/L: Normal, deficiency unlikely 150-220 pmol/L: Borderline, deficiency is possible <150 pmol/L: Low, consistent with deficiency Glenmore Specialist Centre(Westbrook Medical Associates)

Specimen Type	Collection Date	Specimen Collected By
SERUM	2023-Oct-03 1:47:00 PM EDT	Glenmore Specialist Centre

Specimen Type	Collection Date	Specimen Collected By
		(Westbrook Medical Associates)

Ferritin Ferritin H 795 15 - 272 ug/L

<15 ug/L: diagnostic of iron deficiency 15-30 ug/L: probable iron deficiency

30 ug/L: iron deficiency unlikely 100 ug/L: normal iron stores =>600 ug/L: consider test for iron overload Glenmore Specialist Centre(Westbrook Medical Associates)

Specimen Type	Collection Date	Specimen Collected By
SERUM	2023-Oct-03 1:47:00 PM EDT	Glenmore Specialist Centre
		(Westbrook Medical Associates)

Creatinine Creatinine 82 50 - 100 umol/L Glomerular Filtration Rate Predicted 65

An eGFR from 60-89 ml/min/1.73 m2 is consistent with mildly decreased kidney function. However, in the absence of other evidence of kidney disease, eGFR values in this range do not fulfill the KDIGO criteria for chronic kidney disease. Interpret results in concert with ACR measurement.

Effective May 3, 2015, eGFR is calculated using the CKD-EPI 2009 equation.

KDIGO 2012 guidelines highlight the importance of eGFR and urine albumin creatinine ratio (ACR) in screening, diagnosis and management of CKD. Results for eGFR should be interpreted in concert with ACR. Glenmore Specialist Centre(Westbrook Medical Associates)

Specimen Type	Collection Date	Specimen Collected By
SERUM	2023-Oct-03 1:47:00 PM EDT	Glenmore Specialist Centre
		(Westbrook Medical Associates)

Thyrotropin Thyroid Stimulating Hormone [TSH] 2.15 0.32 - 4.00 mIU/L

CC List Fitzgerald, Santiago (W-7602451830)

Ordering Facility Sunnymede Family Practice

Address 368 River Rd Calgary S8G 4E6 ON (Firm/Business)

CONFIDENTIAL - report contains Personal Health Information Generated from Highpark Health Centre 2 on 2026-04-28 13:45:35 EDT by user Pvetxd Czcxtqawts Patient: Lucia Alvarez PHN: 3062663187SX DOB: 1957

Patient: Mrs. Lucia Alvarez Appointment Date: 2023-Aug-30 Title: Chart Notes Provider: Fitzgerald, Santiago Referred By: Fitzgerald, Santiago

Lucia was seen for reassessment and ongoing management of her Crohn's disease.

As per current public health recommendations the patient was given an option for in person or virtual visit and prefers a virtual visit by phone. The entire visit was standard care as per usual standards with the exception of a physical exam.

Past medical history:

1. Crohn's disease - Dx in 2001 - presented with SBO, but did not required surgery upfront. Was on 5-ASA and one course of steroids, no prior biologics until starting Entyvio . Presented to Glenmore Specialist Centre and admitted in [REDACTED-DATE] for RLQ abscess and what looks like an enterocutaneous and enterovesicular fistula. Underwent open right hemicolectomy for enteral enteral and enterocutaneous fistula with Dr. Fitzgerald July 2022. The pathology was consistent with severe Crohn's disease. No dysplasia identified. A total of 28 cm of small bowel was removed and 4 cm of colon. Fistula noted between distal TI, bladder, and abdominal wall. Infliximab started Nov 2022.
2. Possible celiac disease - DQ2 positive but not homozygous - celiac antibodies and duodenal biopsies negative.
3. Asthma
4. Hypothyroidism
5. Osteoporosis
6. Several month history bilateral arm numbness, tingling - MRI brain normal - MRI spine showed some mild narrowing, awaiting Neurologist appt in [REDACTED-DATE].

Current medications: Infliximab 500mg q6weeks (previously was 300mg q8weeks, low levels <1), Colestid 1g PO BID, Atrovent, Prolia, Vitamin D 2000 IU daily

Allergies: None.

Social history: Non-smoker, rare EtoH, no illicit drugs.

Family history: 2 children with celiac disease.

History of presenting illness: Feels well. Having 1 BM/day, no blood, no urgency, no tenesmus. No abdominal pain. No obstructive symptoms. Appetite, energy, and weight stable. No extraintestinal manifestations of IBD. Review of systems otherwise unremarkable.

Labs: 2022-Dec-05 - HgB 141 g/L, WBC 5.9 x E9/L, Platelets 279 x E9/L, ALT 32 U/L, AST 25 U/L, ALP 67 U/L, Bilirubin 8 umol/L, Creatinine 71 umol/L, CRP 1.3 mg/L, Iron Saturation 0.24, Ferritin 110 ug/L, Albumin 44 g/L

Previous abscess grew Klebsiella pneumo and B fragilis - sensitive to Cipro.

TDM: Infliximab TDM standard care Jul 6, 2023 was 0.89.

Endoscopic evaluation: Colonoscopy was performed on May 28, 2023 and demonstrated a widely patent ileocolonic anastomosis. 4 aphthous ulcers noted in neoterminal ileum, Rutgeerts Score of 1. Remainder of colon otherwise unremarkable.

Gastroscopy and colonoscopy on Sep 12, 2021. Unremarkable gastroscopy with gastric and duodenal biopsies taken. Colonoscopy complete to ileocecal valve at which point there was a benign narrowing of the ileocecal valve, but no active inflammation. Biopsies taken from the terminal ileum

---

across the ileocecal valve as well as right and left colon. No active colitis. Duodenal, gastric, right and left colon biopsies normal. Terminal ileum biopsies moderate chronic colitis with small numbers of neutrophils.

Rectum polyp, hyperplastic polyp.

Imaging: No imaging since OR.

CT May 6, 2022 - RLQ abscess measuring 6.9 x 1.8cm. Overall improvement from prior CT.

IR guided drainage of RLQ abscess on May 4 with placement of 10F drainage catheter.

CT May 2, 2022 - RLQ abscess measuring 8.5 x 5.1cm with fluid and gas. In communication with the bladder. Probably enterocutaneous and enterovesicular fistulae.

CT scan on Apr 21, 2022. Extensive active disease in the distal ileum. There is extensive fistula between the distal ileum, bladder, and abdominal wall.

MRI on Dec 9, 2021. Active inflammatory Crohn's disease affecting TI with 2 skip lesions identified longest measuring 12cm. No strictures, fistulas, or abscesses noted.

Impression and Plan: Alvarez is doing very well. She had mild endoscopic recurrence at her postoperative endoscopy and she remains on infliximab but we optimized her drug dosing and interval due to low levels. We will plan for repeat TDM in the next couple of months and optimize further as needed. I would likely plan for repeat colonoscopy in 12-18 months for restaging. I will see her back in 4 to 6 months for reassessment.

IBD Plan:

1. Maintain up to date vaccinations with GP.
2. Avoid NSAIDs and anti-inflammatories which can cause flares of IBD, tylenol is safe.
3. Patient counselled on risks and side effects of current medical therapy.
4. Patient knows to contact me if they develop signs of a disease exacerbatIon including worsening abdominal pain, diarrhea, or blood in the stools.

Thank you for involving me in the care of this patient. Please don't hesitate to contact me if you have any questions or concerns.

Glenmore Specialist Centre

760 Sherwood Ave

Fax Cover Sheet

To: Dr. Santiago Fitzgerald Phone: (624) 837-1465 Fax: (791) 442-5889

Date: 2023-Aug-30

Check out our new website at www.birchwoodcareclinic.ca

From: Dr. Santiago Fitzgerald Phone: (624) 837-1465 Fax: (624) 837-1465

Number of pages including cover: 3

Re: Lucia Alvarez

Confidential: This communication is intended only for the individual or institution to which it is addressed and should not be distributed, copied or disclosed to anyone else. The documents in this communication may contain personal, confidential or privileged information, which may be subject to the Freedom of Information and Protection of Privacy Act, the Health Information Act and other legislation. If you have received this communication in error, please notify us immediately and return original transmission to us. Thank you for your co-operation and assistance.

2023-Aug-30

Dr. Santiago Fitzgerald 760 Sherwood Ave

Patient: Mrs. Lucia Alvarez **PHN:** 9187508760-FM **Birthdate:** 1957 **Phone Number:** (624) 837-1465, **Work:** (791) 442-5889 **Cell:** (624) 837-1465 **Address:** 760 Sherwood Ave **Provider Billing No.:** 817811

Dear Dr. Fitzgerald,

Lucia was seen for reassessment and ongoing management of her Crohn's disease.

As per current public health recommendations the patient was given an option for in person or virtual visit and prefers a virtual visit by phone. The entire visit was standard care as per usual standards with the exception of a physical exam.

Past medical history:

1. Crohn's disease - Dx in 2001 - presented with SBO, but did not required surgery upfront. Was on 5-ASA and one course of steroids, no prior biologics until starting Entyvio . Presented to Glenmore Specialist Centre and admitted in [REDACTED-DATE] for RLQ abscess and what looks like an enterocutaneous and enterovesicular fistula. Underwent open right hemicolectomy for enteral enteral and enterocutaneous fistula with Dr. Fitzgerald July 2022. The pathology was consistent with severe Crohn's disease. No dysplasia identified. A total of 28 cm of small bowel was removed and 4 cm of colon. Fistula noted between distal TI, bladder, and abdominal wall. Infliximab started Nov 2022.
2. Possible celiac disease - DQ2 positive but not homozygous - celiac antibodies and duodenal biopsies negative.
3. Asthma
4. Hypothyroidism
5. Osteoporosis
6. Several month history bilateral arm numbness, tingling - MRI brain normal - MRI spine showed some mild narrowing, awaiting Neurologist appt in [REDACTED-DATE].

Current medications: Infliximab 500mg q6weeks (previously was 300mg q8weeks, low levels <1), Colestid 1g PO BID, Atrovent, Prolia, Vitamin D 2000 IU daily

Allergies: None.

Social history: Non-smoker, rare EtoH, no illicit drugs.

Family history: 2 children with celiac disease.

History of presenting illness: Feels well. Having 1 BM/day, no blood, no urgency, no tenesmus. No abdominal pain. No obstructive symptoms. Appetite, energy, and weight stable. No extraintestinal manifestations of IBD. Review of systems otherwise unremarkable.

Labs: 2022-Dec-05 - HgB 141 g/L, WBC 5.9 x E9/L, Platelets 279 x E9/L, ALT 32 U/L, AST 25 U/L, ALP 67 U/L, Bilirubin 8 umol/L, Creatinine 71 umol/L, CRP 1.3 mg/L, Iron Saturation 0.24, Ferritin 110 ug/L, Albumin 44 g/L

Patient: Lucia Alvarez PHN: 3062663187SX DOB: 1957

Previous abscess grew Klebsiella pneumo and B fragilis - sensitive to Cipro.

TDM: Infliximab TDM standard care Jul 6, 2023 was 0.89.

Endoscopic evaluation: Colonoscopy was performed on May 28, 2023 and demonstrated a widely patent ileocolonic anastomosis. 4 aphthous ulcers noted in neoterminal ileum, Rutgeerts Score of 1. Remainder of colon otherwise unremarkable.

Gastroscopy and colonoscopy on Sep 12, 2021. Unremarkable gastroscopy with gastric and duodenal biopsies taken. Colonoscopy complete to ileocecal valve at which point there was a benign narrowing of the ileocecal valve, but no active inflammation. Biopsies taken from the terminal ileum across the ileocecal valve as well as right and left colon. No active colitis. Duodenal, gastric, right and left colon biopsies normal. Terminal ileum biopsies moderate chronic colitis with small numbers of neutrophils. Rectum polyp, hyperplastic polyp.

Imaging: No imaging since OR.

CT May 6, 2022 - RLQ abscess measuring 6.9 x 1.8cm. Overall improvement from prior CT.

IR guided drainage of RLQ abscess on May 4 with placement of 10F drainage catheter.

CT May 2, 2022 - RLQ abscess measuring 8.5 x 5.1cm with fluid and gas. In communication with the bladder. Probably enterocutaneous and enterovesicular fistulae.

CT scan on Apr 21, 2022. Extensive active disease in the distal ileum. There is extensive fistula between the distal ileum, bladder, and abdominal wall.

MRI on Dec 9, 2021. Active inflammatory Crohn's disease affecting TI with 2 skip lesions identified longest measuring 12cm. No strictures, fistulas, or abscesses noted.

Impression and Plan: Alvarez is doing very well. She had mild endoscopic recurrence at her postoperative endoscopy and she remains on infliximab but we optimized her drug dosing and interval due to low levels. We will plan for repeat TDM in the next couple of months and optimize further as needed. I would likely plan for repeat colonoscopy in 12-18 months for restaging. I will see her back in 4 to 6 months for reassessment.

IBD Plan:

1. Maintain up to date vaccinations with GP.
2. Avoid NSAIDs and anti-inflammatories which can cause flares of IBD, tylenol is safe.
3. Patient counselled on risks and side effects of current medical therapy.
4. Patient knows to contact me if they develop signs of a disease exacerbation including worsening abdominal pain, diarrhea, or blood in the stools.

Thank you for involving me in the care of this patient. Please don't hesitate to contact me if you have any questions or concerns.

D-4474057291 W-7602451830

Lakeshore Specialty Clinic®

Post-infusion Feedback Report (For referring physician's review)

1. PATIENT INFORMATION

Last Name of Patient:	First Name of Patient:	Date of birth: (DD/MM/YYYY)
Alvarez	Lucia	05/09/1957
	(Hospital ID:)	

2. INFUSION CONFIRMATION REPORT

TO: Prescribing Physician:: Santiago Fitzgerald Fax #: (624) 837-1465

FROM: Infusion Location: Lakeshore Specialty Clinic Contact Person: Q. Bqthtx JJ Fax #: (791) 442-5889 Phone #: (791) 442-5889

3. IMMUNOSUPPRESSANTS (IF APPLICABLE)

Dose: (mg, Frequency, and Route)

4. Lakeshore Specialty Clinic® CLINIC AND COORDINATOR INFORMATION

Name of Lakeshore Specialty Clinic Clinic: Lakeshore Specialty Clinic Phone #: (791) 442-5889

Lakeshore Specialty Clinic® Coordinator Name: Eyetf Efcgwg Fax #: (791) 442-5889

5. INFUSION INFORMATION

Remicade Dose Given: Weight 53.00kg /116.84 lbs 500.00 mg exact dose Induction Dose: Yes [ ] No [X]

Date of Infusion: 28/08/2023 (DD/MM/YYYY)

Lot # W-7602451830 exsp. [REDACTED-DATE]

Infusion Frequency: Q6W

Next Infusion Scheduled 09/10/2023 (DD/MM/YYYY)

TDM Serum Draw Completed : Not requested

PREMEDICATION	PRESCRIBED	ADMINISTERED
	DOSE	ROUTE

6. INFUSION REACTION INFORMATION

Was there an infusion reaction? : No Adverse Event Reported to Manufacturer? : Not Applicable

7. PLEASE ASK PATIENT

Last Blood Test Performed: (DD/MM/YYYY) Unknown Last Referring Physician Visit: (DD/MM/YYYY) Unknown Next Referring Physician Visit: (DD/MM/YYYY) Unknown

8. INFUSION ADMINISTRATION

Name of On-Call Medical Backup Physician: Dr. Fitzgerald Name of Infusion Nurse: Q. Bqthtx JJ Infusion Nurse's Signature/Date: (DD/MM/YYYY)

Remicade INFLIXIMAB / Simponi IV golimumab for infusion / Stelara ustekinumab

Sunnymede Family Practice 210 Glenarm Ave | Calgary, ON | S8G 4E6 | www.stonebridgehealthclinic.ca © 2016 Sunnymede Family Practice | All trademarks used under license | (illegible)

Sunnymede Family Practice

Patient: Lucia Alvarez PHN: 3062663187SX DOB: 1957

D-4474057291	**W-7602451830**

Lakeshore Specialty Clinic®

Post-infusion Feedback Report

(For referring physician's review)

1. PATIENT INFORMATION

Last Name of Patient:	First Name of Patient:	Date of birth: (DD/MM/YYYY)
Alvarez	Lucia	05/09/1957
	(Hospital ID:)	

2. INFUSION CONFIRMATION REPORT

TO: Prescribing Physician:: Santiago Fitzgerald Fax #: (624) 837-1465

FROM: Infusion Location: Lakeshore Specialty Clinic Contact Person: Santiago Fitzgerald Fax #: (791) 442-5889 Phone #: (791) 442-5889

3. IMMUNOSUPPRESSANTS (IF APPLICABLE)

Dose: (mg, Frequency, and Route)

4. Lakeshore Specialty Clinic® CLINIC AND COORDINATOR INFORMATION

Name of Lakeshore Specialty Clinic Clinic: Lakeshore Specialty Clinic Phone #: (791) 442-5889

Lakeshore Specialty Clinic® Coordinator Name: Eyetf Efcgwg Fax #: (791) 442-5889

5. INFUSION INFORMATION

Remicade Dose Given: Weight 52.50kg / 115.74 lbs 500.00 mg exact dose Induction Dose: Yes [ ] No [X]

Date of Infusion: 20/07/2023 (DD/MM/YYYY)

Lot # W-7602451830 No 2025

Infusion Frequency: Stat dose

Next Infusion Scheduled 28/08/2023 (DD/MM/YYYY)

TDM Serum Draw Completed : Not requested

PREMEDICATION	PRESCRIBED	ADMINISTERED
	DOSE	ROUTE

6. INFUSION REACTION INFORMATION

Was there an infusion reaction? : No Adverse Event Reported to Manufacturer? : Not Applicable

7. PLEASE ASK PATIENT

Last Blood Test Performed: (DD/MM/YYYY)	Last Referring Physician Visit: (DD/MM/YYYY)	Next Referring Physician Visit: (DD/MM/YYYY)
Unknown	Unknown	Unknown

8. INFUSION ADMINISTRATION

Name of On-Call Medical Backup Physician:	Name of Infusion Nurse:	Infusion Nurse's Signature/Date:
Dr. Fitzgerald	Santiago Fitzgerald	[illegible]
		(DD/MM/YY)

REMICADE® (DIN: 02244016) Order Form Lakeshore Specialty Clinic®

PATIENT INFORMATION: Name: Lucia Alvarez (Patient ID: D-4474057291) Preferred Name: Lucia Address: 368 River Rd, Calgary, ON, Canada BQT 3T9 Tel: (624) 837-1465 Date of Birth (DD/MM/YYYY): 05/09/1957 Gender: Female Allergies: NKDA Indication: Crohn's (Fistulizing) Secondary Indication: Weight (KG): 50.60 Date of Wt (DD/MM/YYYY): 17/07/2023 Hospital ID:

PRESCRIBING PHYSICIAN INFORMATION: Name: Dr. Santiago Fitzgerald Licence Number: Address: 368 River Rd, Quebec, ON U4U 5X1 Tel: (624) 837-1465 Pager: Fax: (624) 837-1465 Ref: W-7602451830 Pharmacy Name: Sunnymede Family Practice Fax: (624) 837-1465

PRESCRIBING PHYSICIAN SECTION

Schedule	Starting Week #	Administration	Drug	DIN	Dose	Precision	Frequency	Repeats
Stat	2	Infusion	Remicade	02244016	500 mg	Exactly		
Maintenance	8	Infusion	Remicade	02244016	500 mg	Exactly	Every 6 Week(s)	

DURATION: 52 Weeks This is: [ ] first REMICADE order for this patient [ ] OR a renewal [X] OR a change in prescription No substitutions [X] Utilize the Recommended Standard Protocol to infuse REMICADE over no less than 2 hours or as tolerated, and manage infusion reactions as applicable [ ] If my patient has received the last three 2-hour infusions without any type of infusion reaction, initiate the following order: Utilize the Shortened Infusion Protocol to infuse REMICADE over no less than 1 hour, or as tolerated, and manage reactions as applicable. Adult patients eligible for shortened infusion: Rheumatoid Arthritis, Crohn's Disease (dose < 10 mg/kg) or Ulcerative Colitis (dose < 10 mg/kg) [ ] Other:

PRETREATMENT ORDER Option 1 [X] No pre-medications required **Option 2** Please Check desired pretreatment medication(s) administered prior to infusion at clinic (indicate dose/route) [ ] Diphenhydramine (e.g. Benadryl) ___ mg [ ] Acetaminophen ___ mg [ ] Hydrocortisone ___ mg [ ] Dimenhydrinate (e.g., Gravol) ___ mg [ ] Desloratadine ___ mg [ ] Other: ___

RELEVANT MEDICAL/SURGICAL HISTORY, MEDICATION(S) AND NOTES: entero-bladder fistula, hospitalized with drain Apr 2022, open right hemicolectomy July 2022

TB Test [ ] Not required **OR** Date Completed: 11/03/2022 Result: Negative **CXR** [ ] Not required **OR** Date Completed: [REDACTED-DATE] Result: Normal **Hep B** [ ] Not required **OR** Date Completed: [REDACTED-DATE] Result: Immune

PRESCRIBER CERTIFICATION I certify that this prescription is an original prescription and will not be reused. Physician Signature: Santiago Fitzgerald Date: 17/07/2023 *Effective date.

Fax order to: Eyetf Efcgwg Fax: (791) 442-5889

210 Glenarm Ave | Calgary, Ontario | S8G 4E6 | www.stonebridgehealthclinic.ca © 2014 Sunnymede Family Practice | All trademarks used under license. All other third party trademarks are the property of their respective owner(s)

[image] --

This task has been completed

Patient	Alvarez, Lucia	**Task Created By**	[REDACTED-STAFF-PROVIDER-NAME-OR-USERNAME]
Date Due	07/16/2023	**Priority**	Urgent
Assigned To	Eyetf Efcgwg	**Completed**	2023-Jul-17 by Eyetf Efcgwg

Notes very low tdm
pls give extra dose in next couple weeks of 500mg x1 and then continue 500mg q6 weeks and repeat tdm and fecal cal in 2-3 more infusions
noted Eyetf Efcgwg

[image] -- Follow-up Appt.

This task has been completed

Patient	Alvarez, Lucia	**Task Created By**	[REDACTED-STAFF-PROVIDER-NAME-OR-USERNAME]
Date Due	07/16/2023	**Priority**	Normal
Assigned To	[REDACTED-STAFF-OR-PROVIDER-NAME]	**Completed**	2023-Aug-02 by [REDACTED-STAFF-OR-PROVIDER-NAME]

Notes 4-6 weeks 2023-Aug-02(hwqwemu): booked Aug 30th, letting Sunnymede Family Practice make contact

---

D-4474057291 W-7602451830

Lakeshore Specialty Clinic®

Post-infusion Feedback Report (For referring physician's review)

1. PATIENT INFORMATION

Last Name of Patient:	First Name of Patient:	Date of birth: (DD/MM/YYYY)
Alvarez	Lucia (Hospital ID:)	05/09/1957

2. INFUSION CONFIRMATION REPORT

TO: Prescribing Physician:: Santiago Fitzgerald Fax #: (624) 837-1465

FROM: Infusion Location: Lakeshore Specialty Clinic Contact Person: HBSFR SKDWU Fax #: (791) 442-5889 Phone #: (791) 442-5889

3. IMMUNOSUPPRESSANTS (IF APPLICABLE)

Dose: (mg, Frequency, and Route)

4. Lakeshore Specialty Clinic® CLINIC AND COORDINATOR INFORMATION

Name of Lakeshore Specialty Clinic Clinic: Lakeshore Specialty Clinic Phone #: (791) 442-5889 Lakeshore Specialty Clinic® Coordinator Name: Eyetf Efcgwg Fax #: (791) 442-5889

5. INFUSION INFORMATION

Remicade Dose Given: Weight 50.60kg /111.55 lbs 300.00 mg exact dose Induction Dose: Yes [ ] No [X]

Date of Infusion: 03/07/2023 (DD/MM/YYYY)

Lot # W-7602451830 NO-2025

Infusion Frequency: Q 8 WEEKS

Next Infusion Scheduled 28/08/2023 (DD/MM/YYYY)

TDM Serum Draw Completed : Yes

| PREMEDICATION | PRESCRIBED | ADMINISTERED | | :--- | :--- | :--- | :--- | :--- | | | **DOSE** | **ROUTE** | **DOSE** | **ROUTE** | **PATIENT REFUSED?** |

6. INFUSION REACTION INFORMATION

Was there an infusion reaction? : No Adverse Event Reported to Manufacturer? : Not Applicable

7. PLEASE ASK PATIENT

Last Blood Test Performed: (DD/MM/YYYY)	Last Referring Physician Visit: (DD/MM/YYYY)	Next Referring Physician Visit: (DD/MM/YYYY)
03/07/2023	Unknown	Unknown

8. INFUSION ADMINISTRATION

Name of On-Call Medical Backup Physician:	Name of Infusion Nurse:	Infusion Nurse's Signature/Date:
Santiago Fitzgerald	HBSFR SKDWU	(DD/MM/YY)

(R)Remicade INFLIXIMAB (R)Simponi IV golimumab for infusion (R)Stelara ustekinumab

Sunnymede Family Practice 210 Glenarm Ave | Calgary, ON | S8G 4E6 | www.stonebridgehealthclinic.ca © 2016 Sunnymede Family Practice | All trademarks used under license | [illegible]

Sunnymede Family Practice

Lab Results: Sunnymede Family Practice Generated On 2026-Apr-28

Patient	**Alvarez, Lucia**	**HomePhone**		**WorkPhone**	
Health #	7811 918 750	Sex	F	Patient ID	817811
Age	68 years				
DOB	1957				

Lab Order #: W-7602451830 Ordered By: Santiago Fitzgerald Collection Date: 2023-Jul-03 Reported Date: 2023-Jul-06 3:45 PM Updated On: 2023-Jul-16 9:07 PM Reported By: Sunnymede Family Practice Reviewed: 2023-Jul-16 by [REDACTED-STAFF-PROVIDER-NAME-OR-USERNAME]

	Flags	**Results**	**Ref Range**	**Units**
Infliximab Drug Level*				
Infliximab Drug Level* Biochemistry (F)		0.890		ug/mL
Interpretation:				
Subtherapeutic level				

Anti-Infliximab antibodies will not be tested

Note: *Infliximab testing procedure (Reflex Testing): Infliximab drug levels and antibodies are tested using a stepwise, reflex procedure. Infliximab drug levels are tested initially and reported. If the Infliximab drug level is undetectable (<= 0.035 ug/mL) then anti-Infliximab antibody levels will be tested and reported.

Method: Reference cut-points defined by a consensus of gastroenterologists, applicable in the context of inflammatory bowel diseases:

Subtherapeutic level: < 3 ug/mL Therapeutic level: 3 - 7 ug/mL Supratherapeutic level: > 7 ug/mL

Infliximab therapy is indicated for a number of inflammatory diseases like rheumatoid arthritis and IBD including Crohn Disease and Ulcerative Colitis.

[X] --

This task has been completed

Patient	Alvarez, Lucia	**Task Created By**	[REDACTED-STAFF-PROVIDER-NAME-OR-USERNAME]
Date Due	05/30/2023	**Priority**	Normal

Assigned To	Eyetf Efcgwg	**Completed**	2023-May-30 by Eyetf Efcgwg
Notes	pls get tdm and fecal cal thx vbbyxtg noted Eyetf Efcgwg		

Hospital Report

Patient	Alvarez, Lucia	**HomePhone**	(624) 837-1465	**WorkPhone**	
Health #	3062663187SX	**Sex**	F	**Patient ID**	817811
Age	68 years				
DOB	1957				

Facility Report #:	W-7602451830		
Sent to:	Fitzgerald, Santiago	Reported By:	Westbrook Medical Associates 2
Collection Date:	2023-May-28	Reviewed:	2023-May-30 by [REDACTED-STAFF-PROVIDER-NAME-OR-USERNAME]
Message Unique ID:	W-7602451830		
Source Author:	817811^[REDACTED-STAFF-PROVIDER-NAME-OR-USERNAME]^[REDACTED-STAFF-OR-PROVIDER-NAME]^[REDACTED-STAFF-OR-PROVIDER-NAME]^MD		
Updated On:	2023-May-30 4:54 PM		

	Flags	**Results**	**Ref Range**
MEDICAL RECORDS (S)			
Sunnymede Family Practice Operative Report		See Below	

Glenmore Specialist Centre 368 River Rd Quebec, ON U4U 5X1 (624) 837-1465

Sunnymede Family Practice Operative Report

Patient: Alvarez, Lucia DOB/Age/Sex: 05/09/1957 / 65 / F HCN: 9187508760-FM Address: 368 River Rd Calgary, ON BQT 3T9 Phone Number: (624) 837-1465 FWS: F529685831 Wnrq: MJ1726876/49 Visit Date: 28/05/2023 Report Number: W-7602451830 Patient Location: W-7602451830 Patient Rm/Bed:

Attending Provider: Santiago Fitzgerald Primary Care Provider: Santiago Fitzgerald Copies To: Santiago Fitzgerald; Santiago Fitzgerald

Provider Note Clinic Note Procedure: Colonoscopy

Pre-procedure Diagnosis: Crohn's disease status post ileocolic resection Apr 2022 on infliximab.

Post-procedure Diagnosis: Widely patent ileocolic anastomosis. 4 aphthous ulcers noted in neoterminal ileum, Rutgers Score of 1. Remainder of colon otherwise unremarkable. Continue current management with infliximab and will plan for TDM and fecal Cal in the next few months and optimize as needed.

Clinical history: Please see prior clinical notes for full details. As you know Lucia is well-known to me with a history of Crohn's disease status post ileocolic resection with extensive small bowel resection back in July 2022 when she presented with a right lower quadrant abscess. She was started on infliximab shortly thereafter and has been doing well. She has had no change in her bowel habit no blood in the stools. No abdominal pain or obstructive symptoms. No extraintestinal manifestations of IBD. Appetite, energy, weight are stable.

Physical exam: Head and neck exam was unremarkable. Abdominal exam revealed a soft non-distended, non-tender abdomen with no appreciable organomegaly or stigmata of chronic liver disease. There was no swelling or erythema of the lower extremities.

Informed Consent: We discussed the benefits, risks, and alternatives to the procedure including the risks of sedation, aspiration, bleeding, infection, perforation, and missed lesions. Written informed consent was obtained. All questions were answered and patient was brought into the endoscopy suite in stable condition.

Procedure: The patient was placed in left lateral decubitus position and intravenous sedation was provided. A digital rectal examination was performed and there were no abnormalities. An adult colonoscope was advanced through the anal verge all the way to the neo-terminal ileum without difficulty. The Boston bowel prep was 2,2,2 requiring minimal suctioning of liquid stool contents throughout. The total withdrawal time was appropriately 8 minutes. I carefully inspected the entire

---

colon including the right colon twice in forward flexion. The findings are as follows.

Findings: Within the distal 10 cm of neoterminal ileum there were 4 aphthous ulcers consistent with Rutgers score of 1. The anastomosis was widely patent. The remainder the colon was unremarkable with no evidence of Crohn's disease.

Rectal retroflexion was performed and was unremarkable. The scope was removed after decompressing the bowel. The patient tolerated the procedure well without complication. The patient will be monitored in the recovery room and discharged home post procedure.

Impression and Plan: Lucia has mild endoscopic recurrence and remains on infliximab. I will check her TDM and fecal Cal and ensure she is well optimized and follow-up with her in a few months for ongoing management.

Thanks for involving me in this patients care and please don't hesitate to contact me if you have any questions or concerns.

Dr. Santiago Fitzgerald Gastroenterologist and Advanced Endoscopist

Report Status: Signed Dictated By: Fitzgerald, Santiago

<Electronically signed by Santiago Fitzgerald>

Dictated Date/Time: [REDACTED-DATE] Transcribed Date/Time: [REDACTED-DATE]

This report may have been generated using speech recognition software. If there are any concerns regarding the contents, please notify us immediately. LAB results are captured at the point in time of report dictation, please review Highpark Health Centre 2 for current LAB results.

NOTE: This report is confidential under the Personal Health Information Protection Act, 2004 (PHIPA) and is intended for authorized individuals and the above named recipient(s). If you have received this in error, please notify the sender by FAX at (Sunnymede Family Practice (791) 442-5889, Sunnymede Family Practice (791) 442-5889, Sunnymede Family Practice (791) 442-5889, Glenmore Specialist Centre (791) 442-5889) and destroy any copies you have. Any unauthorized distribution, disclosure or use of this document is strictly prohibited. Principal Author: Fitzgerald, Santiago

---

[image]

[image]

[image]

[image]

[image]

[X] Review

This task has been completed

Patient	Alvarez, Lucia	**Task Created By**	[REDACTED-STAFF-OR-PROVIDER-NAME]
Date Due	05/24/2023	**Priority**	Normal
Assigned To	Eyetf Efcgwg	**Completed**	2023-May-25 by Eyetf Efcgwg

Notes Hello, Lucia advises her insurance coverage is changing, she does not have coverage for Remicade now and needs to switch over to a biosimilar by end of [REDACTED-DATE]...she seems fine with this :) hwqwemu

Fitzgerald, May 24, 2023 3:39pm Eyetf Efcgwg, not sure if you are already aware. [REDACTED-STAFF-OR-PROVIDER-NAME], any biosim preference? you ok with inflectra (trying to rotate between inflectra and renflexis)?

2023-May-24(Eyetf Efcgwg): Actually when i called pt, their plan is switching to Sunnymede Family Practice from Sunnymede Family Practice but we do not know for sure that they will not approve Remicade. I will apply to them first and then if they insist on a biosimilar, then i will let you know. :)

Fitzgerald, May 25, 2023 11:25am thank you Eyetf Efcgwg !

D-4474057291 W-7602451830

Post-infusion Feedback Report Lakeshore Specialty Clinic (For referring physician's review)

1. PATIENT INFORMATION

Last Name of Patient:	First Name of Patient:	Date of birth: (DD/MM/YYYY)
Alvarez	Lucia (Hospital ID:)	05/09/1957

2. INFUSION CONFIRMATION REPORT

TO: Prescribing Physician: Santiago Fitzgerald Fax #: (624) 837-1465

FROM: Infusion Location: Lakeshore Specialty Clinic Contact Person: Sxgm Esrt JA Fax #: (791) 442-5889 Phone #: (791) 442-5889

3. IMMUNOSUPPRESSANTS (IF APPLICABLE)

Dose: (blank) (mg, Frequency, and Route)

4. Lakeshore Specialty Clinic® CLINIC AND COORDINATOR INFORMATION

Name of Lakeshore Specialty Clinic Clinic: Lakeshore Specialty Clinic Phone #: (791) 442-5889 Lakeshore Specialty Clinic® Coordinator Name: Eyetf Efcgwg Fax #: (791) 442-5889

5. INFUSION INFORMATION

Remicade Dose Given: Weight 52.50kg /115.74 lbs 300.00 mg exact dose Induction Dose: Yes [ ] No [X]

Date of Infusion:	Lot #	Infusion Frequency:	Next Infusion Scheduled
08/05/2023	W-7602451830 [REDACTED-DATE] x3	Q8weeks	03/07/2023
(DD/MM/YYYY)			(DD/MM/YYYY)

TDM Serum Draw Completed: Not requested

PREMEDICATION	PRESCRIBED	ADMINISTERED	PATIENT REFUSED?
	DOSE	ROUTE	DOSE

6. INFUSION REACTION INFORMATION

Was there an infusion reaction? : No Adverse Event Reported to Manufacturer? : Not Applicable

7. PLEASE ASK PATIENT

Last Blood Test Performed: (DD/MM/YYYY)	Last Referring Physician Visit: (DD/MM/YYYY)	Next Referring Physician Visit: (DD/MM/YYYY)
Unknown	Unknown	Unknown

8. INFUSION ADMINISTRATION

Name of On-Call Medical Backup Physician: Dr. Fitzgerald Name of Infusion Nurse: Sxgm Esrt JA Infusion Nurse's Signature/Date:

(DD/MM/YY)

Remicade INFLIXIMAB Simponi IV golimumab for infusion Stelara ustekinumab

Sunnymede Family Practice 210 Glenarm Ave | Calgary, ON | S8G 4E6 | www.stonebridgehealthclinic.ca © 2016 Sunnymede Family Practice | All trademarks used under license | [illegible]

Sunnymede Family Practice

Patient: Lucia Alvarez PHN: 3062663187SX DOB: 1957

D-4474057291 W-7602451830

Lakeshore Specialty Clinic®

Post-infusion Feedback Report (For referring physician's review)

1. PATIENT INFORMATION

Last Name of Patient:	First Name of Patient:	Date of birth: (DD/MM/YYYY)
Alvarez	Lucia (Hospital ID:)	05/09/1957

2. INFUSION CONFIRMATION REPORT

TO: Prescribing Physician:: Santiago Fitzgerald Fax #: (624) 837-1465

FROM: Infusion Location: Sunnymede Family Practice Contact Person: Sxgm Esrt JA Fax #: (791) 442-5889 Phone #: (791) 442-5889

3. IMMUNOSUPPRESSANTS (IF APPLICABLE)

Dose: (blank) (mg, Frequency, and Route)

4. Lakeshore Specialty Clinic® CLINIC AND COORDINATOR INFORMATION

Name of Lakeshore Specialty Clinic Clinic: Sunnymede Family Practice Phone #: (791) 442-5889 Lakeshore Specialty Clinic® Coordinator Name: Eyetf Efcgwg Fax #: (791) 442-5889

5. INFUSION INFORMATION

Remicade Dose Given: Weight 53.00kg /116.84 lbs 300.00 mg exact dose Induction Dose: Yes [ ] No [X]

Date of Infusion:	**Lot #**	**Infusion Frequency:**	**Next Infusion Scheduled**
13/03/2023	W-7602451830 [REDACTED-DATE] x 3	Q8weeks	08/05/2023
(DD/MM/YYYY)			(DD/MM/YYYY)

TDM Serum Draw Completed: Not requested

PREMEDICATION	**PRESCRIBED**	**ADMINISTERED**	**PATIENT REFUSED?**
	DOSE	**ROUTE**	**DOSE**

6. INFUSION REACTION INFORMATION

Was there an infusion reaction? : No Adverse Event Reported to Manufacturer? : Not Applicable

7. PLEASE ASK PATIENT

Last Blood Test Performed: (DD/MM/YYYY)	**Last Referring Physician Visit: (DD/MM/YYYY)**	**Next Referring Physician Visit: (DD/MM/YYYY)**
Unknown	Unknown	Unknown

8. INFUSION ADMINISTRATION

Name of On-Call Medical Backup Physician: Dr. Fitzgerald Name of Infusion Nurse: Sxgm Esrt JA Infusion Nurse's Signature/Date: _____ (DD/MM/YY)

Remicade INFLIXIMAB Simponi IV golimumab for infusion Stelara ustekinumab

Sunnymede Family Practice 210 Glenarm Ave | Calgary, ON | S8G 4E6 | www.stonebridgehealthclinic.ca © 2016 Sunnymede Family Practice | All trademarks used under license | [illegible]

Sunnymede Family Practice

Patient: Lucia Alvarez PHN: 3062663187SX DOB: 1957

D-4474057291 W-7602451830

Lakeshore Specialty Clinic®

Post-infusion Feedback Report (For referring physician's review)

1. PATIENT INFORMATION

Last Name of Patient:	First Name of Patient:	Date of birth: (DD/MM/YYYY)
Alvarez	Lucia (Hospital ID:)	05/09/1957

2. INFUSION CONFIRMATION REPORT

TO: Prescribing Physician:: Santiago Fitzgerald Fax #: (624) 837-1465

FROM: Infusion Location: Sunnymede Family Practice Contact Person: HBSFR SKDWU Fax #: (791) 442-5889 Phone #: (791) 442-5889

3. IMMUNOSUPPRESSANTS (IF APPLICABLE)

Dose: (blank) (mg, Frequency, and Route)

4. Lakeshore Specialty Clinic® CLINIC AND COORDINATOR INFORMATION

Name of Lakeshore Specialty Clinic Clinic: Sunnymede Family Practice Phone #: (791) 442-5889 Lakeshore Specialty Clinic® Coordinator Name: Eyetf Efcgwg Fax #: (791) 442-5889

5. INFUSION INFORMATION

Remicade Dose Given: Weight 53.00kg /116.84 lbs 300.00 mg exact dose Induction Dose: Yes [ ] No [X]

Date of Infusion:	Lot #	Infusion Frequency:	Next Infusion Scheduled
16/01/2023	W-7602451830 [REDACTED-DATE]	Q 8 WEEKS	13/03/2023
(DD/MM/YYYY)			(DD/MM/YYYY)

TDM Serum Draw Completed : Not requested

PREMEDICATION	PRESCRIBED	ADMINISTERED	PATIENT REFUSED?
	DOSE	ROUTE	DOSE

6. INFUSION REACTION INFORMATION

Was there an infusion reaction? : No Adverse Event Reported to Manufacturer? : Not Applicable

7. PLEASE ASK PATIENT

Last Blood Test Performed: (DD/MM/YYYY)	Last Referring Physician Visit: (DD/MM/YYYY)	Next Referring Physician Visit: (DD/MM/YYYY)
Unknown	Unknown	Unknown

8. INFUSION ADMINISTRATION

Name of On-Call Medical Backup Physician:	Name of Infusion Nurse:	Infusion Nurse's Signature/Date:
Santiago Fitzgerald	HBSFR SKDWU	
		(DD/MM/YY)

Remicade INFLIXIMAB Simponi IV golimumab for infusion Stelara ustekinumab

Sunnymede Family Practice 210 Glenarm Ave | Calgary, ON | S8G 4E6 | www.stonebridgehealthclinic.ca © 2016 Sunnymede Family Practice | All trademarks used under license | [illegible]

Sunnymede Family Practice

Patient: Lucia Alvarez PHN: 3062663187SX DOB: 1957

D-4474057291 W-7602451830

Lakeshore Specialty Clinic®

Post-infusion Feedback Report (For referring physician's review)

1. PATIENT INFORMATION

Last Name of Patient:	First Name of Patient:	Date of birth: (DD/MM/YYYY)
Alvarez	Lucia (Hospital ID:)	05/09/1957

2. INFUSION CONFIRMATION REPORT

TO: Prescribing Physician:: Santiago Fitzgerald Fax #: (624) 837-1465

FROM: Infusion Location: Sunnymede Family Practice Contact Person: HBSFR SKDWU Fax #: (791) 442-5889 Phone #: (791) 442-5889

3. IMMUNOSUPPRESSANTS (IF APPLICABLE)

Dose:	(mg, Frequency, and Route)

4. Lakeshore Specialty Clinic® CLINIC AND COORDINATOR INFORMATION

Name of Lakeshore Specialty Clinic Clinic: Sunnymede Family Practice Phone #: (791) 442-5889 Lakeshore Specialty Clinic® Coordinator Name: Eyetf Efcgwg Fax #: (791) 442-5889

5. INFUSION INFORMATION

Remicade Dose Given: Weight 53.00kg / 116.84 lbs 300.00 mg exact dose Induction Dose: Yes [ ] No [X]

Date of Infusion:	Lot #	Infusion Frequency:	Next Infusion Scheduled
19/12/2022	W-7602451830 [REDACTED-DATE]	LD3 THEN Q 8 WEEKS	16/01/2023
(DD/MM/YYYY)			(DD/MM/YYYY)

TDM Serum Draw Completed : Not requested

PREMEDICATION	PRESCRIBED	ADMINISTERED	PATIENT REFUSED?
	DOSE	ROUTE	DOSE

6. INFUSION REACTION INFORMATION

Was there an infusion reaction? : No Adverse Event Reported to Manufacturer? : Not Applicable

7. PLEASE ASK PATIENT

Last Blood Test Performed: (DD/MM/YYYY)	Last Referring Physician Visit: (DD/MM/YYYY)	Next Referring Physician Visit: (DD/MM/YYYY)
Unknown	Unknown	Unknown

8. INFUSION ADMINISTRATION

Name of On-Call Medical Backup Physician:	Name of Infusion Nurse:	Infusion Nurse's Signature/Date:
Santiago Fitzgerald	HBSFR SKDWU	_____
		(DD/MM/YY)

(R) Remicade® INFLIXIMAB | Simponi® IV golimumab for infusion | Stelara® ustekinumab

---

Lab Results: Generated On 2026-Apr-28

Patient	Alvarez, Lucia	HomePhone	496-380-7749	WorkPhone	
Health #	7811 918 750	Sex	F	Patient ID	817811
Age	68 years				
DOB	1957				

Accession Id: W-7602451830 (Final) Ordered By: Santiago Fitzgerald Reported By: Glenmore Specialist Centre Collection Date: 2022-Dec-06 Reviewed: 2022-Dec-08 by [REDACTED-STAFF-PROVIDER-NAME-OR-USERNAME] Service Date: 2022-Dec-06 Report Date: 2022-Dec-07 3:30 PM

CC: Santiago Fitzgerald Updated On: 2022-Dec-08 3:42 PM

	Results	Flags	Ref Range		Test Loc
CHEMISTRY V					
C-REACTIVE PROTEIN	1.3		< 5.0	mg/L	10
	Test method: Maple Health Clinic Cobas CRP, suitable for cardiovascular disease assessment and detection of active inflammation. CRP >= 2.0 mg/L is a risk-enhancing factor for cardiovascular disease, as defined in the Guidelines of the American Heart Association and the American College of Cardiology (JACC 2019; 74: e177).				

760 Sherwood Ave (791) 442-5889

Accession Id: W-7602451830 (Final) Ordered By: Santiago Fitzgerald Reported By: Glenmore Specialist Centre Collection Date: 2022-Dec-05 Reviewed: 2022-Dec-08 by [REDACTED-STAFF-PROVIDER-NAME-OR-USERNAME] Service Date: 2022-Dec-06 Report Date: 2022-Dec-07 3:30 PM

CC: Santiago Fitzgerald Updated On: 2022-Dec-08 3:42 PM

	Results	Flags	Ref Range		Test Loc
ROUTINE CHEMISTRY I					
REFERENCE INTERVAL NOTE:	Please note change in methodologies for routine immunochemistry. Unless otherwise indicated, results are equivalent and reference intervals remain unchanged.				10
	For a complete list of tests which have been changed, please visit https:\www.stonebridgehealthclinic.ca				
CREATININE	71		50 - 100	umol/L	
eGFR	77				

	Results	Flags	Ref Range		Test Loc
	An eGFR from 60-89 ml/min/1.73 m2 is consistent with mildly decreased kidney function. However, in the absence of other evidence of kidney disease, eGFR values in this range do not fulfill the KDIGO criteria for chronic kidney disease. Interpret results in concert with ACR measurement.				
	For patients of African descent, the reported eGFR must be multiplied by 1.15.				
	Effective May 3, 2015, eGFR is calculated using the CKD-EPI 2009 equation.				
	KDIGO 2012 guidelines highlight the importance of eGFR and urine albumin creatinine ratio (ACR) in screening, diagnosis and management of CKD. Results for eGFR should be interpreted in concert with ACR.				
TOTAL BILIRUBIN	8		< 20	umol/L	
DIRECT BILIRUBIN:CONJUGATED	3		< 7	umol/L	
ASPARTATE TRANSAMINASE(AST)	25		< 30	U/L	
ALANINE TRANSAMINASE (ALT)	32		< 36	U/L	
ALKALINE PHOSPHATASE	67		35 - 120	U/L	
IRON	13		11 - 34	umol/L	
TRANSFERRIN	2.16		2.00 - 4.00	g/L	
TIBC	54		50 - 100	umol/L	

TRANSFERRIN SATURATION 0.24 0.13 - 0.50 760 Sherwood Ave (791) 442-5889

Accession Id: W-7602451830 (Final) Ordered By: Santiago Fitzgerald Reported By: Glenmore Specialist Centre Collection Date: 2022-Dec-05 Reviewed: 2022-Dec-08 by [REDACTED-STAFF-PROVIDER-NAME-OR-USERNAME] Service Date: 2022-Dec-06 Report Date: 2022-Dec-07 3:30 PM

CC: Santiago Fitzgerald Updated On: 2022-Dec-08 3:42 PM

	Results	Flags	Ref Range		Test Loc
ROUTINE CHEMISTRY II					
CALCIUM	2.47		2.15 - 2.60	mmol/L	10
ALBUMIN	44		35 - 52	g/L	

760 Sherwood Ave (791) 442-5889

Accession Id: W-7602451830 (Final) Ordered By: Santiago Fitzgerald Reported By: Glenmore Specialist Centre Collection Date: 2022-Dec-05 Reviewed: 2022-Dec-08 by [REDACTED-STAFF-PROVIDER-NAME-OR-USERNAME] Service Date: 2022-Dec-06 Report Date: 2022-Dec-07 3:30 PM

CC: Santiago Fitzgerald Updated On: 2022-Dec-08 3:42 PM

	Results	Flags	Ref Range		Test Loc
SPECIAL CHEMISTRY II					
25-HYDROXY VITAMIN D	85.1		75.0 - 250.0	nmol/L	10
VITAMIN B12	332		138 - 652	pmol/L	
	>220 pmol/L: Normal, deficiency unlikely				
	150-220 pmol/L: Borderline, deficiency is possible				
	<150 pmol/L: Low, consistent with deficiency				

760 Sherwood Ave (791) 442-5889

Accession Id: W-7602451830 (Final) Ordered By: Santiago Fitzgerald Reported By: Glenmore Specialist Centre Collection Date: 2022-Dec-05 Reviewed: 2022-Dec-08 by [REDACTED-STAFF-PROVIDER-NAME-OR-USERNAME] Service Date: 2022-Dec-06 Report Date: 2022-Dec-07 3:30 PM

CC: Santiago Fitzgerald Updated On: 2022-Dec-08 3:42 PM

	Results	Flags	Ref Range		Test Loc
HEMATOLOGY I					
WBC	5.9		4.0 - 11.0	x E9/L	10
RBC	4.41		4.00 - 5.10	x E12/L	
HEMOGLOBIN	141		120 - 160	g/L	
HEMATOCRIT	0.395		0.350 - 0.450	L/L	
MCV	90		80 - 100	fL	

	Results	Flags	Ref Range		Test Loc
MCH	32.0		27.5 - 33.0	pg	
MCHC	357		305 - 360	g/L	
RDW	12.9		11.5 - 14.5	%	
PLATELET COUNT	279		150 - 400	x E9/L	

760 Sherwood Ave (791) 442-5889

Accession Id: W-7602451830 (Final) Ordered By: Santiago Fitzgerald Reported By: Glenmore Specialist Centre Collection Date: 2022-Dec-05 Reviewed: 2022-Dec-08 by [REDACTED-STAFF-PROVIDER-NAME-OR-USERNAME] Service Date: 2022-Dec-06 Report Date: 2022-Dec-07 3:30 PM

CC: Santiago Fitzgerald

Updated On: 2022-Dec-08 3:42 PM

	Results	Flags	Ref Range		Test Loc
HEMATOLOGY II					
NEUTROPHILS	4.1		2.0 - 7.5	x E9/L	10
LYMPHOCYTES	1.2		1.0 - 3.5	x E9/L	
MONOCYTES	0.5		0.2 - 1.0	x E9/L	
EOSINOPHILS	0.1		0.0 - 0.5	x E9/L	
BASOPHILS	0.0		0.0 - 0.2	x E9/L	
IMMATURE GRANULOCYTES	0.0		0.0 - 0.1	x E9/L	
NRBC	0			/100 WBC	

760 Sherwood Ave (791) 442-5889

D-4474057291 W-7602451830

Lakeshore Specialty Clinic

Post-infusion Feedback Report (For referring physician's review)

1. PATIENT INFORMATION

Last Name of Patient:	First Name of Patient:	Date of birth: (DD/MM/YYYY)
Alvarez	Lucia	05/09/1957
	(Hospital ID:)	

2. INFUSION CONFIRMATION REPORT

TO: Prescribing Physician:: Santiago Fitzgerald Fax #: (624) 837-1465

FROM: Infusion Location: Sunnymede Family Practice Contact Person: HBSFR SKDWU Fax #: (791) 442-5889 Phone #: (791) 442-5889

3. IMMUNOSUPPRESSANTS (IF APPLICABLE)

Dose: (blank) (mg, Frequency, and Route)

4. Lakeshore Specialty Clinic® CLINIC AND COORDINATOR INFORMATION

Name of Lakeshore Specialty Clinic Clinic: Sunnymede Family Practice Phone #: (791) 442-5889

Lakeshore Specialty Clinic® Coordinator Name: Eyetf Efcgwg Fax #: (791) 442-5889

5. INFUSION INFORMATION

Remicade Dose Given:	Date of Infusion:	Lot #	Infusion Frequency:	Next Infusion Scheduled
Weight 52.00kg /114.64 lbs	05/12/2022	W-7602451830 [REDACTED-DATE]	vbbyxtg 0,2,6 THEN Q 8 W	19/12/2022
300.00 mg exact dose				
Induction Dose: Yes [ ] No [X]	(DD/MM/YYYY)			(DD/MM/YYYY)

TDM Serum Draw Completed : Not requested

PREMEDICATION	**PRESCRIBED**	**ADMINISTERED**		
	DOSE	**ROUTE**	**DOSE**	**ROUTE**

6. INFUSION REACTION INFORMATION

Was there an infusion reaction? : No Adverse Event Reported to Manufacturer? : Not Applicable

7. PLEASE ASK PATIENT

Last Blood Test Performed: (DD/MM/YYYY)	**Last Referring Physician Visit: (DD/MM/YYYY) Unknown**	**Next Referring Physician Visit: (DD/MM/YYYY) Unknown**
05/12/2022		

8. INFUSION ADMINISTRATION

Name of On-Call Medical Backup Physician:	**Name of Infusion Nurse:**	**Infusion Nurse's Signature/Date:**
Santiago Fitzgerald	HBSFR SKDWU	
		_____
		(DD/MM/YY)

(R) Remicade INFLIXIMAB Simponi IV golimumab for infusion Stelara ustekinumab

Sunnymede Family Practice 210 Glenarm Ave | Calgary, ON | S8G 4E6 | www.stonebridgehealthclinic.ca © 2016 Sunnymede Family Practice | All trademarks used under license | JANS... |

Sunnymede Family Practice Patient: Lucia Alvarez PHN: 3062663187SX DOB: 1957

[image] --

This task has been completed

Patient	Alvarez, Lucia	**Task Created By**	[REDACTED-STAFF-PROVIDER-NAME-OR-USERNAME]
Date Due	[REDACTED-DATE]	**Priority**	Urgent
Assigned To	Eyetf Efcgwg	**Completed**	2022-Nov-30 by Eyetf Efcgwg
Notes	start remicade standard dosing - tdm prior to second maintenance dose thx, vbbyxtg. Noted Eyetf Efcgwg		

[image] --

This task has been completed

Patient	Alvarez, Lucia	**Task Created By**	[REDACTED-STAFF-PROVIDER-NAME-OR-USERNAME]
Date Due	[REDACTED-DATE]	**Priority**	Urgent
Assigned To	[REDACTED-STAFF-OR-PROVIDER-NAME]	**Completed**	2022-Nov-30 by [REDACTED-STAFF-OR-PROVIDER-NAME]

Notes	IBD labs including B12 level - to be standard care at next remicade infusion -t hx vbbyxtg. 2022-Nov-30(hwqwemu): spoke with pt, she goes next door, unsure of date. Req taken over today		

[X] Colon B

This task has been completed

Patient	Alvarez, Lucia	**Task Created By**	[REDACTED-STAFF-PROVIDER-NAME-OR-USERNAME]
Date Due	[REDACTED-DATE]	**Priority**	Normal
Assigned To	CjrkL	**Completed**	2022-Dec-01 by CjrkL
Notes	colon 6-9 months - consider bendo -t hx vbbyxtg.		

Patient: Mrs. Lucia Alvarez Appointment Date: 2022-Nov-30 Title: Chart Notes Provider: Fitzgerald, Santiago Referred By: Fitzgerald, Santiago Alvarez was seen today to follow up with regards to her Crohn's disease.

As per current public health recommendations the patient was given an option for in person or virtual visit and prefers a virtual visit by phone. The entire visit was standard care as per usual standards with the exception of a physical exam.

Past medical history:

1. Crohn's disease - Dx in 2001 - presented with SBO, but did not required surgery upfront. Was on 5-ASA and one course of steroids, no prior biologics until starting Entyvio recently. Presented to Glenmore Specialist Centre and admitted in [REDACTED-DATE] for RLQ abscess and what looks like an enterocutaneous and enterovesicular fistula. Underwent open right hemicolectomy for enteral enteral and enterocutaneous fistula with Dr. Fitzgerald July 2022. The pathology was consistent with severe Crohn's disease. No dysplasia identified. A total of 28 cm of small bowel was removed and 4 cm of colon. Fistula noted between distal TI, bladder, and abdominal wall.
2. Possible celiac disease - DQ2 positive but not homozygous - celiac antibodies and duodenal biopsies negative.
3. Asthma
4. Hypothyroidism
5. Osteoporosis
6. Several month history bilateral arm numbness, tingling - MRI brain normal - MRI spine showed some mild narrowing, awaiting Neurologist appt in [REDACTED-DATE].

Current medications: Colestid 1g PO BID, Atrovent, Prolia, Vitamin D 2000 IU daily

Allergies: None.

Social history: Non-smoker, rare EtoH, no illicit drugs.

Family history: 2 children with celiac disease.

History of presenting illness: Having some mild ongoing numbness and tingling of her legs and arms - going for PT.

Feels well. Having 1 BM/day, no blood, no urgency, no tenesmus. No abdominal pain. No obstructive symptoms. Appetite, energy, and weight stable. No extraintestinal manifestations of IBD. Review of systems otherwise unremarkable.

Labs: 2022-Aug-21 - HgB 105 g/L, WBC 6.48 x10 9/L, Platelets 320 x10 9/L, ALT 13 U/L, AST 15 U/L, ALP 73 U/L, Bilirubin 7 umol/L, Creatinine 42 umol/L, CRP 31.9 mg/L, Iron Saturation 0.09, Ferritin 110 ug/L, Albumin 42 g/L

Previous abscess grew Klebsiella pneumo and B fragilis - sensitive to Cipro.

Endoscopic evaluation: Gastroscopy and colonoscopy on Sep 12, 2021. Unremarkable gastroscopy with gastric and duodenal biopsies taken. Colonoscopy complete to ileocecal valve at which point there was a benign narrowing of the ileocecal valve, but no active inflammation. Biopsies taken from the terminal ileum across the ileocecal valve as well as right and left colon. No active colitis. Duodenal, gastric, right and left colon biopsies normal. Terminal ileum biopsies moderate chronic colitis with small numbers of neutrophils. Rectum polyp, hyperplastic polyp.

Imaging: MRI spine standard care Oct 10, 2022 revealed 2cm benign hemangioma T3 and mild DDD along with minimal stenosis at various levels.

CT May 6, 2022 - RLQ abscess measuring 6.9 x 1.8cm. Overall improvement from prior CT.

IR guided drainage of RLQ abscess on May 4 with placement of 10F drainage catheter.

CT May 2, 2022 - RLQ abscess measuring 8.5 x 5.1cm with fluid and gas. In communication with the bladder. Probably enterocutaneous and enterovesicular fistulae.

CT scan on Apr 21, 2022. Extensive active disease in the distal ileum. There is extensive fistula between the distal ileum, bladder, and abdominal wall.

MRI on Dec 9, 2021. Active inflammatory Crohn's disease affecting TI with 2 skip lesions identified longest measuring 12cm. No strictures, fistulas, or abscesses noted.

Impression and Plan: Lucia is doing very well. She still has some arm and leg tingling and we have ordered a complete blood work including a B12 level to look for other potential causes. Given her history of fistulizing Crohn's disease requiring an extensive small bowel resection we will plan to start infliximab and plan for colonoscopy in about 6 months for disease restaging. There was a question as to whether her neurological symptoms could be related to multiple sclerosis which would be a relative contraindication with regards to anti-TNF but her MRI had was normal and so she has been told that it is not multiple sclerosis and as such we will go ahead with infliximab which is the treatment of choice given her fistulizing Crohn's. I look forward to seeing her at her colonoscopy.

IBD Plan:

1. Maintain up to date vaccinations with GP.
2. Avoid NSAIDs and anti-inflammatories which can cause flares of IBD, tylenol is safe.
3. Patient counselled on risks and side effects of current medical therapy.

4. Patient knows to contact me if they develop signs of a disease exacerbation including worsening abdominal pain, diarrhea, or blood in the stools.

Thank you for involving me in the care of this patient. Please don't hesitate to contact me if you have any questions or concerns.

BIO ADVANCE® REMICADE® (DIN: 02244016) Order Form

PATIENT INFORMATION: Name: Lucia Alvarez (Patient ID: D-4474057291) Preferred Name: Lucia Address: 368 River Rd, Calgary, ON, Canada BQT 3T9 Tel: (624) 837-1465 Date of Birth (DD/MM/YYYY): 05/09/1957 Gender: Female Allergies: NKDA Indication: Crohn's (Fistulizing) Secondary Indication: Weight (KG): 52.00 Date of Wt (DD/MM/YYYY): [REDACTED-DATE] Hospital ID:

PRESCRIBING PHYSICIAN INFORMATION: Name: Dr. Santiago Fitzgerald Licence Number: Address: 368 River Rd, Quebec, ON U4U 5X1 Tel: (624) 837-1465 Pager: Fax: (624) 837-1465 Ref: W-7602451830 Pharmacy Name: Sunnymede Family Practice Fax: (624) 837-1465

PRESCRIBING PHYSICIAN SECTION

Schedule	Starting Week #	Administration	Drug	DIN	Dose	Precision	Frequency	Repeats
Induction	0	Infusion	Remicade	02244016	300 mg	Exactly		
Induction	2	Infusion	Remicade	02244016	300 mg	Exactly		
Induction	6	Infusion	Remicade	02244016	300 mg	Exactly		
Maintenance	14	Infusion	Remicade	02244016	300 mg	Exactly	Every 8 Week(s)	

DURATION: 52 Weeks This is: [X] first REMICADE order for this patient [ ] OR a renewal [ ] OR a change in prescription No substitutions [X] Utilize the Recommended Standard Protocol to infuse REMICADE over no less than 2 hours or as tolerated, and manage infusion reactions as applicable [ ] If my patient has received the last three 2-hour infusions without any type of infusion reaction, initiate the following order: Utilize the Shortened Infusion Protocol to infuse REMICADE over no less than 1 hour, or as tolerated, and manage reactions as applicable. Adult patients eligible for shortened infusion: Rheumatoid Arthritis, Crohn's Disease (dose < 10 mg/kg) or Ulcerative Colitis (dose < 10 mg/kg) [ ] Other:

PRETREATMENT ORDER Option 1 [X] No pre-medications required Option 2 [ ] Please Check desired pretreatment medication(s) administered prior to infusion at clinic (indicate dose/route) [ ] Diphenhydramine (e.g., Benadryl) ___ mg [ ] Acetaminophen ___ mg [ ] Hydrocortisone ___ mg [ ] Dimenhydrinate (e.g., Gravol) ___ mg [ ] Desloratadine ___ mg [ ] Other: ___

RELEVANT MEDICAL/SURGICAL HISTORY, MEDICATION(S) AND NOTES: entero-bladder fistula, hospitalized with drain Apr 2022. open right hemicolectomy July 2022 TB Test [ ] Not required OR Date Completed: 11/03/2022 Result: Negative CXR [ ] Not required OR Date Completed: [REDACTED-DATE] Result: Normal Hep B [ ] Not required OR Date Completed: [REDACTED-DATE] Result: Immune

PRESCRIBER CERTIFICATION I certify that this prescription is an original prescription and will not be reused. Physician Signature: [signature: Santiago Fitzgerald] Date: Nov 30, 2022 *Effective date.

Fax order to: Eyetf Efcgwg Fax: (791) 442-5889 210 Glenarm Ave | Calgary, Ontario | S8G 4E6 | www.stonebridgehealthclinic.ca © 2014 Sunnymede Family Practice | All trademarks used under license. All other third party trademarks are the property of their respective owner(s)

Ontario | Sunnymede Family Practice | Laboratory Requisition Requisitioning Clinician / Practitioner

Name Dr. Santiago Fitzgerald

Address 760 Sherwood Ave

Clinician/Practitioner Number	CPSO / Registration No.
817811	

Laboratory Use Only

Clinician/Practitioner's Contact Number for Urgent Results (624) 837-1465

Service Date yyyy [blank] mm [blank] dd [blank]

Health Number	Version	Sex	Date of Birth
3062663187SX		F	1957

Check (□) one: [X] OHIP/Insured [ ] Third Party / Uninsured [ ] WSIB

Province ON

Other Provincial Habiba Lindgren

Patient's Telephone Contact Number (624) 837-1465

Additional Clinical Information (e.g. diagnosis) [ ] Fast for 12 hours [ ] Fast Overnight

Patient's Last Name (as per OHIP Card) Alvarez

Patient's First & Middle Names (as per OHIP Card) Lucia Alvarez

[X] Copy to: Clinician/Practitioner Last Name First Name Santiago Fitzgerald Address 760 Sherwood Ave

Patient's Address (including Postal Code) 368 River Rd Calgary ON BQT 3T9

Note: Separate requisitions are required for cytology, histology / pathology and tests performed by Public Health Laboratory

x	Biochemistry	x	Hematology	x	Viral Hepatitis (check one only)
[ ]	Glucose [ ] Random [ ] Fasting	[X]	CBC	[ ]	Acute Hepatitis

x	Biochemistry	x	Hematology	x	Viral Hepatitis (check one only)
[ ]	HbA1C	[ ]	Prothrombin Time (INR)	[ ]	Chronic Hepatitis
[ ]	TSH		**Immunology**	[ ]	Immune Status / Previous Exposure
[X]	Creatinine (eGFR)	[ ]	Pregnancy test (Urine)		Specify: [ ] Hepatitis A
[ ]	Uric Acid	[ ]	Mononucleosis Screen		[ ] Hepatitis B
[ ]	Sodium	[ ]	Rubella		[ ] Hepatitis C
[ ]	Potassium	[ ]	Prenatal: ABO, RhD, Antibody Screen (titre and ident. if positive)		or order individual hepatitis tests in the "Other Tests" section below
[ ]	Chloride				**Prostate Specific Antigen (PSA)**
[ ]	CK	[ ]	Repeat Prenatal Antibodies	[ ]	Total PSA [ ] Free PSA
[X]	ALT		**Microbiology ID & Sensitivities (if warranted)**		Specify one below:
[X]	Alk. Phosphatase	[ ]	Cervical	[ ]	Insured - Meets OHIP eligibility criteria
[X]	Bilirubin total and direct	[ ]	Vaginal	[ ]	Uninsured - Screening: Patient responsible for payment
[X]	Albumin	[ ]	Vaginal / Rectal - Group B Strep		**Vitamin D (25-Hydroxy)**
[ ]	Lipid Assessment (includes Cholesterol, HDL-C, Triglycerides, calculated LDL-C & Chol/HDL-C ratio; individual lipid tests may be ordered in the "Other Tests" section of this form)	[ ]	Chlamydia (specify source):	[ ]	Insured - Meets OHIP eligibility criteria: osteopenia; osteoporosis; rickets; renal disease; malabsorption syndromes; medications affecting vitamin D metabolism
[X]	Vitamin B12	[ ]	GC (specify source):	[ ]	Uninsured - Patient responsible for payment
[ ]	Ferritin	[ ]	Sputum		**Other Tests - one test per line**
[ ]	Albumin / Creatinine Ratio, Urine	[ ]	Throat		AST - advised by hepatologist
[ ]	Urinalysis (Chemical)	[ ]	Wound (specify source):		CRP
[ ]	Neonatal Bilirubin:	[ ]	Urine		Serum iron(IBD)

x	Biochemistry	x	Hematology	x	Viral Hepatitis (check one only)
	Child's Age: days [blank] hours [blank]	[ ]	Stool Culture		Iron saturation
	Clinician/Practitioner's tel. no.	[ ]	Stool Ova & Parasites		
	Patient's 24 hr telephone no.	[ ]	Other Swabs / Pus (specify source):		
	Therapeutic Drug Monitoring:				
	Name of Drug #1		**Specimen Collection**		
	Name of Drug #2		Time [blank] Date YYYY-MMM-DD		
[ ]	Time Collected #1 hr. [blank] #2 hr. [blank]				
[ ]	Time of Last Dose #1 hr. [blank] #2 hr. [blank]		**Fecal Occult Blood Test (FOBT) (check one)**		
[ ]	Time of Next Dose #1 hr. [blank] #2 hr. [blank]	[ ]	FOBT (non CCC)	[ ]	ColonCancerCheck FOBT (CCC) no other test can be ordered on this form

I hereby certify the tests ordered are not for registered in or out patients of a hospital. [signature: Santiago Fitzgerald] X Clinician/Practitioner Signature 2022-Nov-30 Date

Laboratory Use Only

817811 (2010/09) © Glenmore Specialist Centre, 2010 817811

Glenmore Specialist Centre

760 Sherwood Ave

Fax Cover Sheet

To: Dr. Santiago Fitzgerald Phone:(624) 837-1465 Fax: (791) 442-5889

Date: 2022-Nov-30

Check out our new website at www.birchwoodcareclinic.ca

From: Dr. Santiago Fitzgerald Phone: (624) 837-1465 Fax: (624) 837-1465

Number of pages including cover: 4

Re: Lucia Alvarez

Confidential: This communication is intended only for the individual or institution to which it is addressed and should not be distributed, copied or disclosed to anyone else. The documents in this communication may contain personal, confidential or privileged information, which may be subject to the Freedom of information and Protection of Privacy Act, the Health Information Act and other legislation. If you have received this communication in error, please notify us immediately and return original transmission to us. Thank you for your co-operation and assistance.

Dr. Santiago Fitzgerald Glenmore Specialist Centre 760 Sherwood Ave Phone: (624) 837-1465 Fax: (624) 837-1465

2022-Nov-30

Dr. Santiago Fitzgerald 760 Sherwood Ave

Patient: Mrs. Lucia Alvarez **PHN:** 9187508760-FM **Birthdate:** 1957 **Phone Number:** (624) 837-1465, **Work:** (791) 442-5889 **Cell:** (624) 837-1465 **Address:** 368 River Rd, Calgary, ON BQT 3T9 **Provider Billing No.:** 817811

Dear Dr. Fitzgerald,

Alvarez was seen today to follow up with regards to her Crohn's disease.

As per current public health recommendations the patient was given an option for in person or virtual visit and prefers a virtual visit by phone. The entire visit was standard care as per usual standards with the exception of a physical exam.

Past medical history:

1. Crohn's disease - Dx in 2001 - presented with SBO, but did not required surgery upfront. Was on 5-ASA and one course of steroids, no prior biologics until starting Entyvio recently. Presented to Glenmore Specialist Centre and admitted in [REDACTED-DATE] for RLQ abscess and what looks like an enterocutaneous and enterovesicular fistula. Underwent open right hemicolectomy for enteral enteral and enterocutaneous fistula with Dr. Fitzgerald July 2022. The pathology was consistent with severe Crohn's disease. No dysplasia identified. A total of 28 cm of small bowel was removed and 4 cm of colon. Fistula noted between distal TI, bladder, and abdominal wall.
2. Possible celiac disease - DQ2 positive but not homozygous - celiac antibodies and duodenal biopsies negative.
3. Asthma
4. Hypothyroidism
5. Osteoporosis
6. Several month history bilateral arm numbness, tingling - MRI brain normal - MRI spine showed some mild narrowing, awaiting Neurologist appt in [REDACTED-DATE].

Current medications: Colestid 1g PO BID, Atrovent, Prolia, Vitamin D 2000 IU daily

Allergies: None.

Social history: Non-smoker, rare EtoH, no illicit drugs.

Family history: 2 children with celiac disease.

History of presenting illness: Having some mild ongoing numbness and tingling of her legs and arms - going for PT.

Patient: Lucia Alvarez PHN: 3062663187SX DOB: 1957

Feels well. Having 1 BM/day, no blood, no urgency, no tenesmus. No abdominal pain. No obstructive symptoms. Appetite, energy, and weight stable. No extraintestinal manifestations of IBD. Review of systems otherwise unremarkable.

Labs: 2022-Aug-21 - HgB 105 g/L, WBC 6.48 x10 9/L, Platelets 320 x10 9/L, ALT 13 U/L, AST 15 U/L, ALP 73 U/L, Bilirubin 7 umol/L, Creatinine 42 umol/L, CRP 31.9 mg/L, Iron Saturation 0.09, Ferritin 110 ug/L, Albumin 42 g/L

Previous abscess grew Klebsiella pneumo and B fragilis - sensitive to Cipro.

Endoscopic evaluation: Gastroscopy and colonoscopy on Sep 12, 2021. Unremarkable gastroscopy with gastric and duodenal biopsies taken. Colonoscopy complete to ileocecal valve at which point there was a benign narrowing of the ileocecal valve, but no active inflammation. Biopsies taken from the terminal ileum across the ileocecal valve as well as right and left colon. No active colitis. Duodenal, gastric, right and left colon biopsies normal. Terminal ileum biopsies moderate chronic colitis with small numbers of neutrophils. Rectum polyp, hyperplastic polyp.

Imaging: MRI spine standard care Oct 10, 2022 revealed 2cm benign hemangioma T3 and mild DDD along with minimal stenosis at various levels.

CT May 6, 2022 - RLQ abscess measuring 6.9 x 1.8cm. Overall improvement from prior CT.

IR guided drainage of RLQ abscess on May 4 with placement of 10F drainage catheter.

CT May 2, 2022 - RLQ abscess measuring 8.5 x 5.1cm with fluid and gas. In communication with the bladder. Probably enterocutaneous and enterovesicular fistulae.

CT scan on Apr 21, 2022. Extensive active disease in the distal ileum. There is extensive fistula between the distal ileum, bladder, and abdominal wall.

MRI on Dec 9, 2021. Active inflammatory Crohn's disease affecting TI with 2 skip lesions identified longest measuring 12cm. No strictures, fistulas, or abscesses noted.

Impression and Plan: Lucia is doing very well. She still has some arm and leg tingling and we have ordered a complete blood work including a B12 level to look for other potential causes. Given her history of fistulizing Crohn's disease requiring an extensive small bowel resection we will plan to start infliximab and plan for colonoscopy in about 6 months for disease restaging. There was a question as to whether her neurological symptoms could be related to multiple sclerosis which would be a relative contraindication with regards to anti-TNF but her MRI had was normal and so she has been told that it is not multiple sclerosis and as such we will go ahead with infliximab which is the treatment of choice given her fistulizing Crohn's. I look forward to seeing her at her colonoscopy.

IBD Plan:

1. Maintain up to date vaccinations with GP.
2. Avoid NSAIDs and anti-inflammatories which can cause flares of IBD, tylenol is safe.
3. Patient counselled on risks and side effects of current medical therapy.

4. Patient knows to contact me if they develop signs of a disease exacerbation including worsening abdominal pain, diarrhea, or blood in the stools.

Thank you for involving me in the care of this patient. Please don't hesitate to contact me if you have any questions or concerns.

Sincerely,

Patient: Lucia Alvarez PHN: 3062663187SX DOB: 1957

Santiago Fitzgerald Electronically Reviewed to Expedite Delivery

Patient: Lucia Alvarez PHN: 3062663187SX DOB: 1957

Hospital Report

Patient	Alvarez, Lucia	**HomePhone**	(624) 837-1465	**WorkPhone**	
Health #	3062663187SX	**Sex**	F	**Patient ID**	817811
Age	68 years				
DOB	1957				

Facility Report #:	057291		
Sent to:	Fitzgerald, Santiago	Reported By:	Westbrook Medical Associates 2
Collection Date:	2022-Oct-10	Reviewed:	2022-Oct-14 by [REDACTED-STAFF-PROVIDER-NAME-OR-USERNAME]
Message Unique ID:	057291		
Source Author:	057291		
Updated On:	2022-Oct-14 1:16 AM		

Flags Results Ref Range Lakeshore Specialty Clinic 5 (S) MRI See Below

Glenmore Specialist Centre

Alberta Quebec, ON BQT 3T9 930-216-8546

Medical Imaging Report

Patient: Alvarez, Lucia FWS: F529685831 DOB/Age/Sex: 05/09/1957 / 65 / F Twds: BL2546578/12 HCN: 9187508760-FM Visit Date: [REDACTED-DATE] Address: 368 River Rd Report Number: 057291 Calgary, ON BQT 3T9 Patient Location: 057291 Phone Number: (624) 837-1465 Patient Rm/Bed:

Ordering Provider: Fitzgerald, Santiago Primary Care Provider: Santiago Fitzgerald Copies To: Santiago Fitzgerald; Santiago Fitzgerald

Procedure(s): MRI Spine Cervical 4 REP 3D Procedure Date/Time (DD/MM/YY): [REDACTED-DATE] 0355 Accession Number(s): 057291

TECHNIQUE: MRI Spine Cervical 4 REP 3D

Req number: 057291

COMPARISON: None available.

HISTORY: 3 month history of numbness along both arms with mild weakness

FINDINGS: There is imaging from the posterior fossa/base the skull down to the super endplate of T4. There is no evidence of malalignment or loss of vertebral body height however mild multilevel mid cervical DDD and spondylosis is seen.

There is a 2 cm diameter benign hemangioma within the left lateral T3 vertebra

C0-C4: No significant abdomen identified

C4/C6: Mild osteochondral bars are identified with minimal central spinal canal stenosis. There is mild to moderate right C5/6 neural foraminal stenosis. No left-sided Significant neuroforaminal stenosis is seen.

C6-T3: No significant abdomen identified.

Report Status: Signed

Dictated By: Fitzgerald, Santiago Electronically Signed By: Fitzgerald, Santiago Dictated Date/Time (DD/MM/YY): [REDACTED-DATE] Transcribed Date/Time (DD/MM/YY): [REDACTED-DATE]

This report may have been generated using speech recognition software. If there are any concerns regarding the contents, please notify us immediately. LAB results are captured at the point in time of report dictation, please review Highpark Health Centre 2 for current LAB results.

NOTE: This report is confidential under the Personal Health Information Protection Act, 2004 (PHIPA) and is intended for authorized individuals and the above named recipient(s). If you have received this in error, please notify the sender at (Sunnymede Family Practice (791) 442-5889, Sunnymede Family Practice (791) 442-5889, Sunnymede Family Practice (791) 442-5889, Glenmore Specialist Centre (791) 442-5889) and destroy any copies you have. Any unauthorized distribution, disclosure or use of this document is strictly prohibited.

MRI Spine Cervical 4 REP 3D - 2022-Oct-10 3:55 AM

Principal Author: Fitzgerald, Santiago

[image] --

This task has been completed

Patient	Alvarez, Lucia	**Task Created By**	[REDACTED-STAFF-PROVIDER-NAME-OR-USERNAME]
Date Due	[REDACTED-DATE]	**Priority**	Urgent
Assigned To	[REDACTED-STAFF-OR-PROVIDER-NAME]	**Completed**	2022-Oct-03 by [REDACTED-STAFF-OR-PROVIDER-NAME]
Notes	f/u 8 weeks - thx, vbbyxtg. 2022-Oct-03(hwqwemu): booked Nov 30th, letting Glenmore Specialist Centre make contact		

Patient: Mrs. Lucia Alvarez **Appointment Date:** 2022-Oct-02 **Title:** Chart Notes **Provider:** Fitzgerald, Santiago **Referred By:** Fitzgerald, Santiago Alvarez was seen today to follow up with regards to her Crohn's disease.

As per current public health recommendations the patient was given an option for in person or virtual visit and prefers a virtual visit by phone. The entire visit was standard care as per usual standards with the exception of a physical exam.

Past medical history:

1. Crohn's disease - Dx in 2001 - presented with SBO, but did not required surgery upfront. Was on 5-ASA and one course of steroids, no prior biologics until starting Entyvio recently. Presented to Glenmore Specialist Centre and admitted in [REDACTED-DATE] for RLQ abscess and what looks like an enterocutaneous and enterovesicular fistula.Underwent open right hemicolectomy for enteral enteral and enterocutaneous fistula with Dr. Fitzgerald July 2022. The pathology was consistent with severe Crohn's disease. No dysplasia identified. A total of 28 cm of small bowel was removed and 4 cm of colon. Fistula noted between distal TI, bladder, and abdominal wall.
2. Possible celiac disease - DQ2 positive but not homozygous - celiac antibodies and duodenal biopsies negative.
3. Asthma
4. Hypothyroidism
5. Osteoporosis

Current medications: Atrovent, Prolia, Vitamin D 2000 IU daily

Allergies: None.

Social history: Non-smoker, rare EtoH, no illicit drugs.

Family history: Non-contributory.

History of presenting illness: Having some issues with neuropathic pain - awaiting appt with neurologist. Numbness and tingling of hands, feet, lower legs.

Feels well from GI perspective. Having 2-3 loose BM/day, no blood, no urgency, no tenesmus. No abdominal pain. No obstructive symptoms. Incisions healing well. Appetite, energy, and weight stable. No extraintestinal manifestations of IBD. Review of systems otherwise unremarkable.

Labs: May 6, 2022 - HgB 104, WBC 9, Plt 497, Cr 48, liver enzymes and bili normal.

Abscess grew Klebsiella pneumo and B fragilis - sensitive to Cipro.

Endoscopic evaluation: Gastroscopy and colonoscopy on Sep 12, 2021. Unremarkable gastroscopy with gastric and duodenal biopsies taken. Colonoscopy complete to ileocecal valve at which point there was a benign narrowing of the ileocecal valve, but no active inflammation. Biopsies taken from the terminal ileum across the ileocecal valve as well as right and left colon. No active colitis. Duodenal, gastric, right and left colon biopsies normal. Terminal ileum biopsies moderate chronic colitis with small numbers of neutrophils. Rectum polyp, hyperplastic polyp.

Imaging: CT May 6, 2022 - RLQ abscess measuring 6.9 x 1.8cm. Overall improvement from prior CT.

IR guided drainage of RLQ abscess on May 4 with placement of 10F drainage catheter.

CT May 2, 2022 - RLQ abscess measuring 8.5 x 5.1cm with fluid and gas. In communication with the bladder. Probably enterocutaneous and enterovesicular fistulae.

CT scan on Apr 21, 2022. Extensive active disease in the distal ileum. There is extensive fistula between the distal ileum, bladder, and abdominal wall.

MRI on Dec 9, 2021. Active inflammatory Crohn's disease affecting TI with 2 skip lesions identified longest measuring 12cm. No strictures, fistulas, or abscesses noted.

Impression and Plan: Lucia is doing very well since her surgery. The main issue is with regards to some neurologic symptoms such as numbness and tingling in her legs, hands, and feet. My 1 concern with starting infliximab is whether she could have multiple sclerosis which would be a relative contraindication and I would probably consider going back on Entyvio or considering Stelara instead. I think it would be best if the GP could arrange an urgent MRI of her head in addition to an MRI of her cervical spine which she has arranged apparently for [REDACTED-DATE]. So long as the MRIs did not show any evidence of demyelination I think we would probably be safe to go ahead and start an anti-TNF medication. Ideally she would have a neurologic consultation in the interim to help guide management. There is ultimately no rush to starting the infliximab but I would not want to delay her too much. I will see her back in 8 weeks for reassessment.

IBD Plan:

1. Maintain up to date vaccinations with GP.
2. Avoid NSAIDs and anti-inflammatories which can cause flares of IBD, tylenol is safe.
3. Patient counselled on risks and side effects of current medical therapy.
4. Patient knows to contact me if they develop signs of a disease exacerbation including worsening abdominal pain, diarrhea, or blood in the stools.

Thank you for involving me in the care of this patient. Please don't hesitate to contact me if you have any questions or concerns.

Glenmore Specialist Centre

760 Sherwood Ave

Fax Cover Sheet

To: Dr. Santiago Fitzgerald Phone: (624) 837-1465 Fax: (791) 442-5889

Date: 2022-Oct-02

Check out our new website at www.birchwoodcareclinic.ca

From: Dr. Santiago Fitzgerald Phone: (624) 837-1465 Fax: (624) 837-1465

Number of pages including cover: 4

Re: Lucia Alvarez

Confidential: This communication is intended only for the individual or institution to which it is addressed and should not be distributed, copied or disclosed to anyone else. The documents in this communication may contain personal, confidential or privileged information, which may be subject to the Freedom of Information and Protection of Privacy Act, the Health Information Act and other legislation. If you have received this communication in error, please notify us immediately and return original transmission to us. Thank you for your co-operation and assistance.

Dr. Santiago Fitzgerald

Glenmore Specialist Centre 760 Sherwood Ave Phone: (624) 837-1465 Fax: (624) 837-1465

2022-Oct-02

Dr. Santiago Fitzgerald 760 Sherwood Ave

Patient: Mrs. Lucia Alvarez **PHN:** 9187508760-FM **Birthdate:** 1957 **Phone Number:** (624) 837-1465, **Work:** (791) 442-5889 **Cell:** (624) 837-1465 **Address:** 760 Sherwood Ave **Provider Billing No.:** 817811

Dear Dr. Fitzgerald,

Alvarez was seen today to follow up with regards to her Crohn's disease.

As per current public health recommendations the patient was given an option for in person or virtual visit and prefers a virtual visit by phone. The entire visit was standard care as per usual standards with the exception of a physical exam.

Past medical history:

1. Crohn's disease - Dx in 2001 - presented with SBO, but did not required surgery upfront. Was on 5-ASA and one course of steroids, no prior biologics until starting Entyvio recently. Presented to Glenmore Specialist Centre and admitted in [REDACTED-DATE] for RLQ abscess and what looks like an enterocutaneous and enterovesicular fistula.Underwent open right hemicolectomy for enteral enteral and enterocutaneous fistula with Dr. Fitzgerald July 2022. The pathology was consistent with severe Crohn's disease. No dysplasia identified. A total of 28 cm of small bowel was removed and 4 cm of colon. Fistula noted between distal TI, bladder, and abdominal wall.

2. Possible celiac disease - DQ2 positive but not homozygous - celiac antibodies and duodenal biopsies negative.
3. Asthma
4. Hypothyroidism
5. Osteoporosis

Current medications: Atrovent, Prolia, Vitamin D 2000 IU daily

Allergies: None.

Social history: Non-smoker, rare EtoH, no illicit drugs.

Family history: Non-contributory.

History of presenting illness: Having some issues with neuropathic pain - awaiting appt with neurologist. Numbness and tingling of hands, feet, lower legs.

Feels well from GI perspective. Having 2-3 loose BM/day, no blood, no urgency, no tenesmus. No abdominal pain. No obstructive symptoms. Incisions healing well. Appetite, energy, and weight stable.

Patient: Lucia Alvarez PHN: 3062663187SX DOB: 1957

No extraintestinal manifestations of IBD. Review of systems otherwise unremarkable.

Labs: May 6, 2022 - HgB 104, WBC 9, Plt 497, Cr 48, liver enzymes and bili normal.

Abscess grew Klebsiella pneumo and B fragilis - sensitive to Cipro.

Endoscopic evaluation: Gastroscopy and colonoscopy on Sep 12, 2021. Unremarkable gastroscopy with gastric and duodenal biopsies taken. Colonoscopy complete to ileocecal valve at which point there was a benign narrowing of the ileocecal valve, but no active inflammation. Biopsies taken from the terminal ileum across the ileocecal valve as well as right and left colon. No active colitis. Duodenal, gastric, right and left colon biopsies normal. Terminal ileum biopsies moderate chronic colitis with small numbers of neutrophils. Rectum polyp, hyperplastic polyp.

Imaging: CT May 6, 2022 - RLQ abscess measuring 6.9 x 1.8cm. Overall improvement from prior CT.

IR guided drainage of RLQ abscess on May 4 with placement of 10F drainage catheter.

CT May 2, 2022 - RLQ abscess measuring 8.5 x 5.1cm with fluid and gas. In communication with the bladder. Probably enterocutaneous and enterovesicular fistulae.

CT scan on Apr 21, 2022. Extensive active disease in the distal ileum. There is extensive fistula between the distal ileum, bladder, and abdominal wall.

MRI on Dec 9, 2021. Active inflammatory Crohn's disease affecting TI with 2 skip lesions identified longest measuring 12cm. No strictures, fistulas, or abscesses noted.

Impression and Plan: Lucia is doing very well since her surgery. The main issue is with regards to some neurologic symptoms such as numbness and tingling in her legs, hands, and feet. My 1 concern with starting infliximab is whether she could have multiple sclerosis which would be a relative contraindication and I would probably consider going back on Entyvio or considering Stelara instead. I think it would be best if the GP could arrange an urgent MRI of her head in addition to an MRI of her cervical spine which she has arranged

apparently for [REDACTED-DATE]. So long as the MRIs did not show any evidence of demyelination I think we would probably be safe to go ahead and start an anti-TNF medication. Ideally she would have a neurologic consultation in the interim to help guide management. There is ultimately no rush to starting the infliximab but I would not want to delay her too much. I will see her back in 8 weeks for reassessment.

IBD Plan:

1. Maintain up to date vaccinations with GP.
2. Avoid NSAIDs and anti-inflammatories which can cause flares of IBD, tylenol is safe.
3. Patient counselled on risks and side effects of current medical therapy.
4. Patient knows to contact me if they develop signs of a disease exacerbation including worsening abdominal pain, diarrhea, or blood in the stools.

Thank you for involving me in the care of this patient. Please don't hesitate to contact me if you have any questions or concerns.

Sincerely,

[image]

Patient: Lucia Alvarez PHN: 3062663187SX DOB: 1957

Santiago Fitzgerald **Electronically Reviewed to Expedite Delivery**

Patient: Lucia Alvarez PHN: 3062663187SX DOB: 1957

Dr. Javier Giordano 202 Juniper Rd 202 Juniper Rd Quebec, Ontario U4U 5X1 (733) 332-2040

Sep 20, 2022

Dr. Santiago Fitzgerald 552 Glenarm Ave 202 Juniper Rd Quebec, ON Phone: 496-380-7749 Fax: 930-216-8546

Dear Dr. Santiago Fitzgerald:

Re: Lucia Alvarez Sep 5, 1957 Age: 65 yr HN: 057291 (791) 442-5889 (H) (791) 442-5889 (M)

I saw this pleasant 65-year-old woman who has history of Crohn's disease and severe ileocolic disease. She is now postop from a ileocolic resection and doing well. Her bowels are moving she her energy appetite and bowel function are slowly returning to normal.

Her incisions are healing well with no signs of infection. Pathology was consistent with Crohn's disease.

No obvious follow-up has been arranged but if there is any concerns she can contact my office.

Yours truly,

[image]

Dr. Javier Giordano

cc: Dr. Santiago Fitzgerald

Sunnymede Family Practice Sunnymede Family Practice

Hospital Report

Patient	Alvarez, Lucia	**Ontario Health Number**	**Telephone**
Date of Birth	1957	7811 918 750	(791) 442-5889
Age (Time of Observation)	64 years		(Primary Residence Number)
Sex	F		**Email Address**
Address	368 River Rd		fatima.pham29@fairlightmedicalcentre.ca
	Calgary ON BQT 3T9		
	(Home)		

Facility Report #:	057291		
Sent to:	Fitzgerald, Santiago	Reported By:	Westbrook Medical Associates 2
Collection Date:	2022-Aug-18	Reviewed:	2022-Aug-18 by [REDACTED-STAFF-PROVIDER-NAME-OR-USERNAME]
Message Unique ID:	057291		
Source Author:	057291		
Updated On:	2022-Nov-29 10:38 PM		

	Flags	**Results**	**Ref Range**
MEDICAL RECORDS (S)			
Operative Report		See Below	

Glenmore Specialist Centre

Alberta Quebec, ON BQT 3T9 930-216-8546

Operative Report

Patient: Alvarez, Lucia DOB/Age/Sex: 05/09/1957 / 64 / F HCN: 9187508760-FM Address: 368 River Rd Calgary, ON BQT 3T9 Phone Number: (624) 837-1465 FWS: F529685831 Pqtp: CY8112101/95 Visit Date: Report Number: 057291 Patient Location: 057291 Patient Rm/Bed: 057291

Attending Provider: Javier Giordano Primary Care Provider: Santiago Fitzgerald Copies To: Javier Giordano; Santiago Fitzgerald; Santiago Fitzgerald

Operative Report Surgeon Javier Giordano

Details of Procedure Preoperative diagnosis - Crohn's disease with associated entero-enteral fistula and enterocutaneous fistula

Postoperative diagnosis same

Procedure: Open right Hemicolectomy for fistulizing and obstructive Crohn's disease

Operative note: This pleasant patient was brought to the operating room under general anesthesia prepped and draped appropriately in the supine position.

Preoperative checklist and consent was obtained. Risks of the procedure including infection, bleeding, conversion to open as well as risk of injuries to adjacent tissues were discussed in great detail.

We started by making a midline laparotomy incision using electrocautery dissection was carried to separate history during the abdominal cavity and direct visualization.

A Bookwalter retractor was placed. The tumor was visualized in the hepatic flexure.

I mobilized the right colon along the line of Toldt separating the retroperitoneal structures off the right colon mesentery.

The vascular pedicle was visualized and came around the hepatic flexure.

At this point the proximal and distal resection margins were visualized well away from diseased segment and divided using a GIA 80 stapler.

I used the LigaSure impact device to take the mesentery approximately 20 cm of small bowel was resected which was hyperemic thickened and had evidence of creeping fat.

There is also an additional segment of small bowel stuck to this adjacent to the disease segment which was divided.

2 burns were made on the stay side and 1 distally before transecting it. the duodenum was well visualized and stayed away from our dissection field the entire case.

At this point the specimen was completely removed and sent off to pathology.

I then fashioned a side-to-side stapled anastomosis.

2 enterotomies were made a GIA 80 stapler was inserted and anastomosis was fashioned the enterotomy was closed using an additional firing of the GIA 80 stapler.

The overlying staple line was closed using a running 3-0 PDS suture.

A crotch stitch 2-0 Vicryl suture was also placed the midline was then closed using a running #1 PDS suture x2 skin was closed with skin staples dressings were applied and patient was extubated taken recovery in stable condition.

I opened up the previous drain site and cutaneous fistula tract.

Patient was extubated and taken to recovery in stable condition. No immediate complications were noted, estimated blood loss was minimal. All sponge and instrument counts were correct at the end of the case.

Case Staff

Operation Date: [REDACTED-DATE] Anesthesia Type General + Epidural

Case Staff Anesthesiologist: Farrow, Ethan

Report Status: Signed Dictated By: Sacco, Alina

<Electronically signed by Javier Giordano>

Dictated Date/Time: [REDACTED-DATE] Transcribed Date/Time: [REDACTED-DATE]

This report may have been generated using speech recognition software. If there are any concerns regarding the contents, please notify us immediately. LAB results are captured at the point in time of report dictation, please review Highpark Health Centre 2 for current LAB results.

NOTE: This report is confidential under the Personal Health Information Protection Act, 2004 (PHIPA) and is intended for authorized individuals and the above named recipient(s). If you have received this in error, please notify the sender at (Sunnymede Family Practice 930-216-8546, Sunnymede Family Practice 930-216-8546, Sunnymede Family Practice 930-216-8546, Glenmore Specialist Centre (624) 837-1465) and destroy any copies you have. Any unauthorized distribution, disclosure or use of this document is strictly prohibited.

Principal Author: Giordano, Javier

CC List	**Admitting Provider**

Fitzgerald, Santiago	Giordano, Javier

(W-7602451830)

(Camille Cormier)

Attending Provider Giordano, Javier (Camille Cormier)

Lab Order # 057291 Maple Health Clinic 3

Last Updated in Highpark Health Centre 2 2022-Aug-21 5:47:44 AM EDT

Specimen Received Date/Time 2022-08-21 5:35:00 AM EDT

Ordering Practitioner Giordano, Javier (Camille Cormier)

Address 202 Juniper Rd Quebec ON U4U 5X1 Highpark Health Centre (Firm/Business)

Primary Performing Lab Maple Health Clinic 3

Address Alberta Quebec BQT 3T9 ON (Firm/Business)

Primary Reporting Lab Maple Health Clinic 3

Address Alberta Quebec BQT 3T9 ON (Firm/Business)

Hematology

Specimen Type Whole blood

Collection Date 2022-Aug-21 5:11:00 AM EDT

Specimen Collected By Maple Health Clinic 3

Complete Blood Count	Flags	Results	Reference Range	Units
Leukocytes		6.48	4.0 - 11.0	x10 9/L
Erythrocytes; Blood (Reference Range Specific to Age)	L	3.64	4.00 - 5.50	x10 12/L
Hemoglobin; Blood (Reference Range Specific to Age)	L	105	115 - 160	g/L
Hematocrit; Blood (Reference Range Specific to Age)	L	0.328	0.350 - 0.470	L/L
Mean Corpuscular Volume; RBC		90.1	80 - 95	fL
Mean Corpuscular Hemoglobin; RBC		28.8	27.0 - 33.0	pg
Mean Corpuscular Hemoglobin Concentration; RBC		320	310 - 360	g/L
Erythrocyte Distribution Width; RBC		14.5	12.0 - 14.9	%
Platelets; Blood		320	150 - 400	x10 9/L

Complete Blood Count	Flags	Results	Reference Range	Units
Mean Platelet Volume; Blood		9.8	7.0 - 11.0	fL
Differential Cell Count Method		Complete		
Neutrophils; Blood		4.86	2.00 - 7.50	x10 9/L
Lymphocytes; Blood (Reference Range Specific to Age)	L	0.82	1.00 - 3.50	x10 9/L
Monocytes; Blood		0.56	0.00 - 1.20	x10 9/L
Eosinophils; Blood		0.19	0.00 - 0.50	x10 9/L
Basophils; Blood		0.03	0.00 - 0.20	x10 9/L
Granulocytes Immature		0.02	0.00	x10 9/L
Erythrocytes Nucleated; Blood		0.00	0.00	x10 9/L

CC List Fitzgerald, Santiago (W-7602451830)

Admitting Provider Giordano, Javier (Camille Cormier)

Attending Provider Giordano, Javier (Camille Cormier)

Lab Order # 057291 Maple Health Clinic 3

Last Updated in Highpark Health Centre 2 2022-Aug-21 6:08:42 AM EDT

Specimen Received Date/Time 2022-08-21 5:35:00 AM EDT

Ordering Practitioner Giordano, Javier (Camille Cormier)

Address 202 Juniper Rd Quebec ON U4U 5X1 Highpark Health Centre (Firm/Business)

Primary Performing Lab Maple Health Clinic 3

Address Alberta Quebec BQT 3T9 ON (Firm/Business)

Primary Reporting Lab Maple Health Clinic 3

Address Alberta Quebec BQT 3T9 ON (Firm/Business)

Chemistry

Specimen Type Plasma

Collection Date 2022-Aug-21 5:11:00 AM EDT

Specimen Collected By Maple Health Clinic 3

Chemistry Panel	Flags	Results	Reference Range	Units
Glucose		5.0	4.0 - 7.8	mmol/L
Creatinine (Reference Range Specific to Sex)	L	42	49 - 90	umol/L
GFR/1.73 sq M.Predicted; CKD-EPI		104		mL/min

The 2009 CKD-EPI equation (units = mL/min/1.73 m2) was used for this eGFR calculation. This modified equation has been endorsed by KDIGO, by the Canadian Society of Nephrology (CSN), and the Ontario Renal Network (ORN).

Invalid for drug dosing, pregnancy, muscle mass extremes.

Normal eGFR.

For patients of African descent, the reported eGFR must be multiplied by 1.159 Maple Health Clinic 3(Crestwood Medical Group)

Sodium		142	132 - 146	mmol/L
Potassium		3.5	3.5 - 5.5	mmol/L
Chloride		108	96 - 109	mmol/L
Carbon Dioxide [CO2]		29	21 - 32	mmol/L
Anion Gap		5	5 - 15	mmol/L

CC List Fitzgerald, Santiago (W-7602451830)

Admitting Provider Giordano, Javier (Camille Cormier)

Attending Provider Giordano, Javier (Camille Cormier)

[X] Follow-up Appt.

This task has been completed

Patient	Alvarez, Lucia	**Task Created By**	[REDACTED-STAFF-PROVIDER-NAME-OR-USERNAME]
Date Due	08/18/2022	**Priority**	Urgent
Assigned To	[REDACTED-STAFF-OR-PROVIDER-NAME]	**Completed**	2022-Sep-06 by [REDACTED-STAFF-OR-PROVIDER-NAME]

Notes f/u 2-3 months - thx vbbyxtg. 2022-Sep-01(hwqwemu): Lucia left me a msg - she wonders when to restart her Remicade post surgery? The OR note makes no mention of this (it also mentions a tumour at the hepatic flexure which is odd, isn't it?) Also she wonders again about the numbness in her legs which she is still having, even though she has discontinued the Cipro. Do you have any ideas about what would be causing this? hwqwemu

shoudl see her GP regarding leg numbness - no idea what would cause this. let me speak to her in the next 3-4 weeks and then we can discuss starting Infliximab - thx vbbyxtg 2022-Sep-06(hwqwemu): all details on V/M as above, given Sept 28th date

---

Sunnymede Family Practice Sunnymede Family Practice

Hospital Report

Patient Alvarez, Lucia **Date of Birth** 1957 **Age (Time of Observation)** 64 years **Sex** F **Address** 368 River Rd Calgary ON BQT 3T9 (Home)

Ontario Health Number 7811 918 750

Telephone (791) 442-5889 (Primary Residence Number)

Email Address fatima.pham29@fairlightmedicalcentre.ca

Comments Vantage Label Y Specimen A Cold Ischemic Time Calculation (mins) 1 Date Specimen Removed From Body [REDACTED-DATE] Date Specimen in Fixative [REDACTED-DATE] Pre-op & Clinical HX: chrons [REDACTED-APPOINTMENT-PROCEDURE-TIME] [REDACTED-APPOINTMENT-PROCEDURE-TIME] Maple Health Clinic 3(Crestwood Medical Group)

Facility Report #:	057291		
Sent to:	Fitzgerald, Santiago	**Reported By:**	Westbrook Medical Associates 2
Collection Date:	2022-Aug-12	**Reviewed:**	2022-Aug-13 by [REDACTED-STAFF-PROVIDER-NAME-OR-USERNAME]
Message Unique ID:	057291		
Source Author:	057291		
Updated On:	2022-Aug-13 4:53 PM		

MEDICAL RECORDS (S)

Flags	Results	Ref Range
Emergency Department Report	See Below	

Glenmore Specialist Centre Alberta Quebec, ON BQT 3T9 930-216-8546

Emergency Department Report

Patient: Alvarez, Lucia DOB/Age/Sex: 05/09/1957 / 64 / F HCN: 9187508760-FM Address: 368 River Rd Calgary, ON BQT 3T9 Phone Number: (624) 837-1465

FWS: F529685831 Vjvu: PQ6646704/63 Visit Date: [REDACTED-DATE] Report Number: 057291 Patient Location: 057291 Patient Rm/Bed:

Attending Provider: Primary Care Provider: Santiago Fitzgerald Copies To: Javier Giordano; Santiago Fitzgerald; Santiago Fitzgerald; Santiago Fitzgerald

Physician Initial Assessment (PIA) Time Time Seen by Provider: [REDACTED-DATE]

Assessment ID: 64 F PC: Sent by Anesthesia (Dr. Fitzgerald) for progressive neuropathy NYD

PMH: Mild hypothyroid, Crohn's disease, Anemia, Nephrolithiasis Medications: Cipro, Flagyl, Prolia, Lorazepam PRN, Budesonide, awaiting laparotomy/bowel resection with Dr. Fitzgerald August 18th

HPI: Patinet was at pre-admission clinic today for her anesthesia assessment 1 month history of progressive numbness/paresthesias to bilateral lower extremities Over the last 1 week has noted feet feel cold and has noted numbness to hands as well Feet occasionally feel painful No pain to back/neck No fevers Has been on Cipro/Flagyl x 3 months (UptoDate - Cipro can cause peripheral neuropathy, risk factors = male, age >60, duration of therapy, T1DM, History of peripheral neuropathy; Flagyl can cause peripheral neuropathy)

O/E: Traige vitals - 36.0, 99, 18, 100%, 119/83 Patient looks well, no distress No midline spinal tenderness Abdo soft, non-tender Lower extremities demonstrate weak DP pulses bilaterally Feet are cool to touch Normal power Decreased sensation to mid shin bilaterally Upper extremities - normal power, sensation slightly decreased in hands, normal reflexes

Impression/Plan: 64 F with peripheral neuropathy. She has been on extended courses of Cipro/Flagyl, both of which can cause neuropathy. She has no weakness in the legs or features concerning for GBS. I discussed with Dr. Fitzgerald from Radiology and due to the global contrast dye shortage we can not get a vascular CT however he has agreed that the pateitn can return on Monday for arterial dopplers (they will not be able to be performed tonight). The patient is happy with this plan. I have asked her to follow up with her family doctor for these results. If there is anything emergent I will contact her.

Discharge Plan Discharge Most Responsible Diagnosis: Peripheral neuropathy

Prescriptions: No Action metronidazole 500 mg capsule 500 mg PO BID RF: 0 lorazepam 1 mg Tablet 1 mg PO BEDTIME PRN (Reason: Sleep) RF: 0 Prolia 60 mg/mL Syringe 60 mg SUBCUT Q6M RF: 0 ciprofloxacin HCl 500 mg Tablet 500 mg PO BID 28 Days Qty: 56 RF: 0

Interventions: ED Discharge Assessment Last standard care: [REDACTED-DATE]

Disposition (Nurse Responsibility): Home (Private) No Support

Discharge Date/Time: [REDACTED-DATE]

Report Status: Signed

Dictated By: Fitzgerald, Santiago

<Electronically signed by Santiago Fitzgerald>

Dictated Date/Time: [REDACTED-DATE] Transcribed Date/Time: [REDACTED-DATE]

This report may have been generated using speech recognition software. If there are any concerns regarding the contents, please notify us immediately. LAB results are captured at the point in time of report dictation, please review Highpark Health Centre 2 for current LAB results.

NOTE: This report is confidential under the Personal Health Information Protection Act, 2004 (PHIPA) and is intended for authorized individuals and the above named recipient(s). If you have received this in error, please notify the sender at (Sunnymede Family Practice 930-216-8546, Sunnymede Family Practice 930-216-8546, Sunnymede Family Practice 930-216-8546, Glenmore Specialist Centre (624) 837-1465) and destroy any copies you have. Any unauthorized distribution,

---

disclosure or use of this document is strictly prohibited.

Principal Author: Fitzgerald, Santiago

Facility Report #: 057291 Sent to: Fitzgerald, Santiago Reported By: Westbrook Medical Associates 2 Collection Date: 2022-Aug-11 Reviewed: 2022-Aug-13 by [REDACTED-STAFF-PROVIDER-NAME-OR-USERNAME] Message Unique ID: 057291 Source Author: 057291 Updated On: 2022-Aug-13 4:53 PM

	Flags	Results	Ref Range
CARDIO-RESPIRATORY (S)			
ECG		See Below	

Glenmore Specialist Centre

Alberta Quebec, ON BQT 3T9 930-216-8546

Electrocardiogram Report

Patient: Alvarez, Lucia FWS: F529685831 DOB/Age/Sex: 05/09/1957 / 64 / F Vyqs: RA1369438/46 HCN: 9187508760-FM Visit Date: [REDACTED-DATE] Address: 368 River Rd Report Number: 057291 Calgary, ON BQT 3T9 Patient Location: 057291 Phone Number: (624) 837-1465 Patient Rm/Bed:

Ordering Provider: Fitzgerald, Santiago Primary Care Provider: Santiago Fitzgerald Copies To: Javier Giordano; Santiago Fitzgerald; Santiago Fitzgerald; Santiago Fitzgerald

Procedure(s): ECG 12 Lead Procedure Date/Time (DD/MM/YY): [REDACTED-DATE] Accession Number(s): 057291

HEART RATE: 94 bpm P-R Interval: 158 ms P Front Axis: 41 deg QRSD Interval: 85 ms QT Interval: 358 ms QTcB: 448 ms QRS Axis: -74 deg T Wave Axis: -47 deg Interpretation:

Sinus rhythm Inferior infarct, age indeterminate

Report Status: Signed

Dictated By: Fitzgerald, Santiago Electronically Signed By: Fitzgerald, Santiago Dictated Date/Time (DD/MM/YY): [REDACTED-DATE] Transcribed Date/Time (DD/MM/YY): [REDACTED-DATE]

This report may have been generated using speech recognition software. If there are any concerns regarding the contents, please notify us immediately. LAB results are captured at the point in time of report dictation, please review Highpark Health Centre 2 for current LAB results.

NOTE: This report is confidential under the Personal Health Information Protection Act, 2004 (PHIPA) and is intended for authorized individuals and the above named recipient(s). If you have received this in error, please

notify the sender at (Sunnymede Family Practice 930-216-8546, Sunnymede Family Practice 930-216-8546, Sunnymede Family Practice 930-216-8546, Glenmore Specialist Centre (624) 837-1465) and destroy any copies you have. Any unauthorized distribution, disclosure or use of this document is strictly prohibited.

ECG 12 Lead - 2022-Aug-11 11:44 AM

Principal Author: Fitzgerald, Santiago

Facility Report #: 057291 Sent to: Fitzgerald, Santiago Reported By: Westbrook Medical Associates 2 Collection Date: 2022-Aug-11 Reviewed: 2022-Aug-13 by [REDACTED-STAFF-PROVIDER-NAME-OR-USERNAME]

Message Unique ID: 057291 Source Author: 057291 Updated On: 2022-Aug-13 4:53 PM

	Flags	Results	Ref Range
MEDICAL RECORDS (S)			
Anesthesiology Consultation		See Below	

Glenmore Specialist Centre

Alberta Quebec, ON BQT 3T9 930-216-8546

Anesthesiology Consultation

Patient: Alvarez, Lucia FWS: F529685831 DOB/Age/Sex: 05/09/1957 / 64 / F Vyqs: RA1369438/46 HCN: 9187508760-FM Visit Date: [REDACTED-DATE] Address: 368 River Rd Report Number: 057291 Calgary, ON BQT 3T9 Patient Location: 057291 Phone Number: (624) 837-1465 Patient Rm/Bed:

Attending Provider: Javier Giordano Primary Care Provider: Santiago Fitzgerald Copies To: Javier Giordano; Ethan Farrow; Santiago Fitzgerald; Santiago Fitzgerald

Consult Note Anesthesiology Consult Note

I saw Lucia in the preadmission clinic at Glenmore Specialist Centre on August 11 catheter in preparation for their upcoming laparotomy, bowel resection currently scheduled for Aug 18, 2022. Their anesthesiologist on that day will be Dr. Farrow..?

The patient presents with the following medical issues: 1.? Ex-smoker with a 20-year pack history having quit in 2001 2.? Underactive thyroid which appears to be mild in nature for which the patient is on no treatment 3.? Advanced Crohn's disease with current enterocutaneous fistula and abdominal drain in situ 4.? Anemia for which the patient received an iron transfusion in May 2022 5. Nephrolithiasis 6. Peripheral neuropathy which is in a stocking and glove distribution which began at some point in [REDACTED-DATE] and has been progressive in nature. Her symptoms initially began with tingling in her great toe on the right and her 5th toe on the left, however this is progressed significantly over the last few weeks and she now has overt numbness in that distribution. This is also now associated with a dusky coloring to her lower extremities bilaterally which has been worsening over the last few days. As a result of her numbness she had a mechanical fall yesterday and does have a laceration to both her upper and lower lip. She did have a CT head which was normal. In the emergency department she was referred for blood work for consideration for nutritional reasons for her peripheral neuropathy however there is still no explanation for this.

REVIEW OF SYSTEMS: Patient denies known history of ischemic heart disease, cardiac valvular abnormalities, cardiac arrhythmias, or heart failure. They do not have asthma or COPD and they are a ex-smoker.?They have

> 4 METS activity.?They have never had a seizure or a stroke, and have no history of diabetes. There is no known blood, hepatic or renal disease.

MEDICATIONS: 1.? Ciprofloxacin 2.? Flagyl 3.? Prolia 4.? Lorazepam as needed 5.? Budesonide

ALLERGIES: Nil

ANESTHETIC HISTORY: They have had previous general anesthesia with no issues.? There are no family members that have had life-threatening genetic reactions anesthesia.

PHYSICAL EXAMINATION: General appearance: No apparent distress.? Vitals: Blood pressure 115/73, heart rate 113 bpm and regular, SpO2 99% on room air Airway examination: Mallampati class 3, normal range of motion cervical spine, normal thyroid mental distance.? Full upper and lower dentures. There is a scab to both her upper and lower lips. Precordium: Normal S1-S2 with no extra heart sounds, including no evidence of S3/S4 or murmurs. Respiratory: Good air entry bilaterally with no crackles nor wheezes. Neurologic: Easily palpable spinous processes of lumbar spine. Power is 5/5 in bilateral lower extremities and upper extremities. She does have reduced sensation to approximately her knee bilaterally and does have some numbness to her fingertips on both hands.

Her feet are cold and dusky in appearance, I am able to appreciate dorsalis pedis pulses bilaterally.

INVESTIGATIONS: Hemoglobin 148, platelets 375.? Sodium 137, potassium 3.4, creatinine 67 with eGFR 83, blood glucose 2.2.? ECG shows normal sinus rhythm with no acute conduction delays or deficits.

ASSESSMENT and PLAN: At this point time I do not have an explanation for the patient's progressive peripheral neuropathy nor the progressive dusky nature of her skin in the lower extremities. She was seen in the emergency department yesterday following mechanical fall as a result of this and she was sent for blood work including B12 and folate which have since come back normal. In fact her blood work is largely normal. Given that the patient is now having difficulty with ambulation, has suffered a recent fall, and does have very obvious dusky and cold lower extremities, I do think it is reasonable she be seen in the emergency department again to rule out any possible vascular etiology and to facilitate access to internal medicine. I do not wish to delay her surgery date if at all possible, and therefore I will ask that she attend the emergency department today.

In anticipation of her upcoming OR I did provide medication instructions the patient will take all of her medications as usual and the day of surgery. I also reviewed the n.p.o. guidelines with her and answered all questions.She would benefit from thoracic epidural placement and enrollment in the acute pain service. I discussed with the patient the conduct of general anesthesia including LMA and ETT placement and associated risk of dental and soft tissue damage. I discussed with the patient the conduct of spinal anesthesia including the risks of bleeding, nerve damage, infection, hypotension and PDPH. I assured the patient that sedation may be provided by their attending anesthesiologist on the day of surgery if safe to do so.

The patient should have a telephone consult with anesthesia prior to her or date next week.

Sincerely,

Alina Sacco

Report Status: Signed Dictated By: Fitzgerald, Santiago

<Electronically signed by Santiago Fitzgerald>

Dictated Date/Time: [REDACTED-DATE] Transcribed Date/Time: [REDACTED-DATE]

This report may have been generated using speech recognition software. If there are any concerns regarding the contents, please notify us immediately. LAB results are captured at the point in time of report dictation, please review Highpark Health Centre 2 for current LAB results.

NOTE: This report is confidential under the Personal Health Information Protection Act, 2004 (PHIPA) and is intended for authorized individuals and the above named recipient(s). If you have received this in error, please notify the sender at (Sunnymede Family Practice (791) 442-5889, Sunnymede Family Practice (791) 442-5889, Sunnymede Family Practice (791) 442-5889, Glenmore Specialist Centre (791) 442-5889) and destroy any copies you have. Any unauthorized distribution, disclosure or use of this document is strictly prohibited.

Principal Author: Fitzgerald, Santiago

CC List Fitzgerald, Santiago (W-7602451830)

Admitting Provider Giordano, Javier (Camille Cormier)

Attending Provider Giordano, Javier (Camille Cormier)

Lab Order # 057291 Maple Health Clinic 3

Ordering Practitioner Giordano, Javier (Camille Cormier)

Primary Performing Lab Maple Health Clinic 3

Last Updated in Highpark Health Centre 2 2022-Aug-25 1:23:27 PM EDT

Address 202 Juniper Rd Quebec ON U4U 5X1 Highpark Health Centre (Firm/Business)

Address Alberta Quebec BQT 3T9 ON (Firm/Business)

Specimen Received Date/Time 2022-08-18 3:19:00 PM EDT

Primary Reporting Lab Maple Health Clinic 3

Address Alberta Quebec BQT 3T9 ON (Firm/Business)

Pathology

Specimen Type: Tissue Site Modifier: Surgical Pathology Collection Date: 2022-Aug-18 1:09:00 PM EDT Specimen Collected By: Maple Health Clinic 3

Flags	Results	Reference Range	Units
	Surgical Pathology		
	Site Of Origin		
	Result: A: Colon, ILEOCOLIC		
	B: Body Tissue Any Site, ADDITIONAL ILEOCOLIC		
	Relevant History		
	Result: CROHN'S		
	Gross Description		
	Result: The specimen is received in 2 parts.		
	A. The specimen, received in formalin, labeled with the patient's identification, Vantage tag and "A ileocolic", consists of:		
	Procedure: Colon resection		
	Dimensions and description:		
	Small bowel (Length 28.0 cm, Proximal circumference 4.8 cm-stapled) with attached mesentery (depth 4.0 cm): The mucosa is tan-gray and partially obscured by creeping mesenteric adipose tissue. The mucosa is tan-green with partly granular irregular and partly white flattened mucosa. Wall thickness measures 0.6-0.7 cm. Approximately 20.0 cm from the proximal resection margin is an ill-defined area of bowel wall that is distorted by white firm fibrous streaks. No definite fistulas are identified. No definite masses, lesions or abnormalities can be identified.		
	Ileocecal valve: Patent and partially replaced by a submucosal deposit of adipose tissue		
	Appendix (Length 2.5 cm, Diameter 0.5 cm): The serosa is tan-gray and partially distorted by adherent pericolic soft tissue. Lumen is patent and filled with tan friable material. The mucosa is tan and unremarkable. Wall thickness measures 0.1-0.2 cm		
	Colon (Length 4.0 cm, Distal circumference 6.0 cm-stapled) with attached pericolic soft tissue (depth 4.4 cm): The serosa is gray-purple and shiny. Lumen is patent. Mucosa is tan with irregular edematous folds. No masses, lesions or abnormalities can be identified.		
	Possible lymph nodes: None sampled		
	Ink Code: Silver nitrate-all surfaces, Green-proximal and distal bowel end resection margins		
	Representative sections:		
	A1 proximal and distal resection margin, perpendicular sections		

Flags	Results	Reference Range	Units
	A2-A6 representative full-thickness sections submitted from proximal-distal including irregular fibrous streaks in A4 and A5 and ileocecal valve in A6 (2, 2, 1, 1, 1 pieces)		
	A7 appendix, longitudinal section of tip and 2 full-thickness cross-sections		
	B. The specimen, received in formalin, labeled with the patient's identification, Vantage tag and "B additional ileocolic", consists of an irregular tan-gray tissue fragment partially covered with tan edematous mucosa and surgical staples (4.5 x 1.4 x 1.0 cm). No masses, lesions or abnormalities can be identified.		
	No sections are taken		
	[REDACTED-DATE] /hwqwemu		
	Final Diagnosis		
	Result: A. ILEOCOLIC RESECTION:		
	- Chronic active enteritis with vague granulomatous inflammation, submucosal fibrosis, transmural involvement, and deep, perforated ulceration.		
	- Features are typical for Crohn's disease.		
	- Proximal margin within normal limits. Distal margin shows slightly increased nonspecific chronic inflammation.		
	- Reactive atypia is present, but definite dysplasia is not identified.		
	N.B. Slide A5 shared with Dr. Alina Sacco.		
	B. ADDITIONAL ILEOCOLIC:		
	- For gross examination.		
	1/e		
	Provider; Signing		
	Result: Signed electronically by: Fitzgerald, Santiago 25/08/2022		

CC List

Admitting Provider

Fitzgerald, Santiago (W-7602451830)

Giordano, Javier (Camille Cormier)

Attending Provider Giordano, Javier (Camille Cormier)

[X] Patient Question

This task has been completed

Patient	Alvarez, Lucia	**Task Created By**	[REDACTED-STAFF-OR-PROVIDER-NAME]
Date Due	07/27/2022	**Priority**	Normal
Assigned To	[REDACTED-STAFF-PROVIDER-NAME-OR-USERNAME]	**Completed**	2022-Aug-18 by [REDACTED-STAFF-PROVIDER-NAME-OR-USERNAME]

Notes She had a new order by Dr. Fitzgerald to flush her drain every 2 weeks - this started 2 weeks ago and right afterward both of her feet have gone numb, the foot on the side with the drain is worse... Dr. Fitzgerald and her GP are both on holidays, she just wanted your opinion as she is afraid there may be some permanent damage being standard care. Odd I know. thoughts?

absolutely no idea, if symptoms getting worse will have to go to ER - thx vbbyxtg, 2022-Aug-14(hwqwemu): see notes in EMR from recent consults, ER, cardio etc. Apparently a GP she saw has suggested long term use of antibiotic could cause this - she is "looking for some help from Dr. Fitzgerald" I guess to perhaps consider a different antibiotic? Sorry, thoughts? 2022-Aug-15(hwqwemu): she updated me today - she is hardly able to walk now due to the numbness, had an echo this morning which I will try to pull

---

Dr. Javier Giordano 202 Juniper Rd 202 Juniper Rd Quebec, Ontario U4U 5X1 (733) 332-2040

Jul 5, 2022

Dr. Santiago Fitzgerald 552 Glenarm Ave 202 Juniper Rd Quebec, ON Phone: 496-380-7749 Fax: 930-216-8546

Dear Dr. Santiago Fitzgerald:

Re: Lucia Alvarez Sep 5, 1957 Age: 64 yr HN: 057291 (791) 442-5889 (H) (791) 442-5889 (M)

I saw this 64-year-old woman in the office today She is awaiting surgery.

Recently her drain output was minimal and I asked the Highpark Health Centre team to flush the drain. This morning she tells me she has had about 20 cc drain out. I have decided to leave the drain in situ until the surgery is performed.

Yours truly,

[image] Dr. Javier Giordano

cc: Dr. Santiago Fitzgerald

Patient Question

This task has been completed

Patient	Alvarez, Lucia	**Task Created By**	[REDACTED-STAFF-OR-PROVIDER-NAME]

Date Due	[REDACTED-DATE]	**Priority**	Urgent
Assigned To	[REDACTED-STAFF-OR-PROVIDER-NAME]	**Completed**	2022-Jul-05 by [REDACTED-STAFF-OR-PROVIDER-NAME]

Notes Hello, Lucia left me a msg asking if you had discussed with Dr. Fitzgerald whether Remicade should begin before or after surgery. She says Dr. Fitzgerald doesn't remember. Your note is pretty clear you should wait and start after but wanted to check...does it depend on when her surgery is...? hwqwemu

when is she going for surgery - i had said as long as its within a few months we will start remicade after - if the surgery was going to be delayed >5-6 months then maybe we would start now -t hx vbbyxtg . 2022-Jul-05(hwqwemu): surgery should be August 18th, she will call us if the date gets delayed and we can get the ball rolling.

[X] Call Patient

This task has been completed

Patient	Alvarez, Lucia	**Task Created By**	hwqwemu
Date Due	[REDACTED-DATE]	**Priority**	Very Urgent
Assigned To	[REDACTED-STAFF-OR-PROVIDER-NAME]	**Completed**	2022-Jun-09 by [REDACTED-STAFF-OR-PROVIDER-NAME]

Notes Monoferric Sunnymede Family Practice Jun 14, 2022-Jun-10(hwqwemu): pt advised, RX faxed to her pharmacy, she will pick up and take with her

---

Highpark Health Centre

Stonebridge Health Clinic

Stonebridge Health Clinic

Fax Cover Sheet

To: Dr. Fitzgerald's office **From:** (blank) **Co./Hosp.** (blank) **Department:** Highpark Health Centre **Fax No.** (blank) **Fax No.** (733) 332-2040 **Telephone No.** (blank) **Telephone No.** (733) 332-2040 **Date:** [REDACTED-DATE] **# of page(s) incl. cover sheet** 4

Message: Hi there, We have scheduled Lucia Alvarez for her Monoferric infusion on [REDACTED-DATE] at 10:45. Please make the patient aware that she must bring her own meds to this appointment, as our Pharmacy does not supply this medication.

Thanks! ☺

Exceptional Care, Every Person, Every Time

[ ] Kingston 202 Juniper Rd, [ ] Saskatchewan, 202 Juniper Rd [ ] Mailing Address 202 Juniper Rd, Saskatchewan, Ontario, U4U 5X1

CONFIDENTIALITY NOTICE This electronic transmission and any accompanying attachments may contain privileged or confidential information intended only for the use of the individual or organization named above. Any distribution, copying or action taken in reliance on the contents of this communication by anyone other than the intended recipient(s) is STRICTLY PROHIBITED. If you have received this communication in error, please notify the sender imediately and destroy the materials received.

Alina Sacco Aurelio Jansen

202 Juniper Rd Quebec, Ontario U4U 5X1

PHONE 496-380-7749 FAX 930-216-8546

Alvarez, Lucia Lindgren 368 River Rd Calgary, ON BQT 3T9 PHN: 9187508760-FM DOB: 1957 h: (624) 837-1465 w: (624) 837-1465

Rx Date: [REDACTED-DATE]

Monoferric 1500mg IV x 1

LU Code 610

Repeat ..... Times Every ..... Days

[signature] Santiago Fitzgerald

PLEASE NOTIFY PATIENT OF APPOINTMENT TIME [REDACTED-DATE] [REDACTED-APPOINTMENT-PROCEDURE-TIME]

[REDACTED-DATE] Highpark Health Centre (733) 332-2040 ID: #057291

Highpark Health Centre (733) 332-2040

Glenmore Specialist Centre Glenmore Specialist Centre

PRE-PRINTED ORDERS Intravenous Iron Replacement (Adult) Highpark Health Centre Page 1 of 2

Lucia Alvarez F 368 River Rd Calgary, ON BQT 3T9 Home: (624) 837-1465 Cell: (733) 332-2040 DOB: 08/06/1957 PHN: 057291

ALLERGIES

MEDICATIONS/FOOD	REACTION
[X] NO KNOWN ALLERGY	
[ ] MEDICATIONS	

MEDICATIONS/FOOD	REACTION
[ ] FOOD	
[ ] ENVIRONMENTAL	
[ ] LATEX	

Transcribe all checked boxes as orders SIGNATURE, DESIGNATION, DATE AND TIME

Insurance

[X] Third Party insurance: If the patient has third party coverage for medications and is not using their own pharmacy, fax the prescription to Highpark Health Centre (733) 332-2040 to determine if intravenous (IV) iron is covered for the patient. Please include patient name, date of birth, address and telephone number on the prescription. [ ] No insurance

Clinical Criteria (please check all applicable boxes)

Ensure clinical need for IV iron (at least one of the following): [ ] Hemoglobin (Hgb) less than 90 g/L OR [ ] Hgb less than 100 g/L and symptomatic anemia with persistent or worsening impairment of functional status (e.g. shortness of breath, light-headedness, tachycardia at rest) AND [ ] Ferritin less than 30 mcg/L [ ] Ferritin 30 - 200 mcg/L, and transferrin saturation less than 20% [ ] Bone Marrow aspirate confirming low iron stores

Other Criteria for IV iron, if patient does not meet clinical criteria above: Hgb: (blank) g/L; Ferritin: (blank) mcg/mL; Date test completed: (blank) [ ] Gastric resection or gastric bypass or receiving TPN [ ] Preoperative blood conservation [ ] Surgery in less than 4 weeks, Hgb less than 120 g/L, ferritin (serum) 30-100 mcg/L, and transferrin saturation less than 20% [ ] Pregnancy [X] Failed iron salts (not efficacious or intolerant due to side effects) At least 60 mg/day of elemental iron, for at least 3 months (avoid greater than 150 mg elemental iron/day), given on an empty stomach with vitamin C to enhance iron absorption [ ] Failure of iron complex supplements (Feramax® 150mg PO daily or Proferrin® 11 mg PO daily to TID or other); trial for at least 3 months

Date: (blank) Time: (blank) Practitioner's Signature: [signature: Santiago Fitzgerald] Date: (blank) Time: (blank) Transcriber's Signature: (blank) Faxed to Pharmacy: attached MM/DD/YYYY

Lucia Alvarez F 368 River Rd Calgary, ON BQT 3T9 Home: (624) 837-1465 Cell: (733) 332-2040 DOB: 08/06/1957 PHN: 3062663187SX

Transcribe all checked boxes as orders SIGNATURE, DESIGNATION, DATE AND TIME

Medication	
[ ] Iron sucrose 300 mg in 250 mL 0.9% sodium chloride IV at least over 90 minutes Number of doses: [ ] 2 doses [ ] 3 doses [ ] Other (blank) Frequency: (blank)	
[X] Other: Monoferric 1500mg IV Number of doses: x1 Frequency: (blank)	
Acetaminophen	
[ ] 650 mg PO q4h PRN for headache, fever, arthralgia, or myalgia for each iron infusion. [ ] 950 mg PO q6h PRN for headache, fever, arthralgia, or myalgia for each iron infusion. Do not exceed 4 g/ 24 hour period.	
dimenhyDRINATE	
[ ] 25 mg PO or IV q4h PRN for nausea for each iron infusion [ ] 50 mg PO or IV q4h PRN for nausea for each iron infusion	
diphenhydrAMINE	
[ ] 25 mg PO or IV q4h PRN for mild urticaria for each iron infusion [ ] 50 mg PO or IV q4h PRN for mild urticaria for each iron infusion	
Monitoring	
Vital signs (heart rate, blood pressure, respiration rate, temperature, oxygen saturation) [X] pre procedure [X] q 5 min x 3 THEN [X] q 30 min THEN [X] 30 min post infusion. [X] Stop infusion and notify physician STAT if signs or symptoms of hypersensitivity reaction occurs (e.g., flushing, hypotension, urticaria, bronchospasm, angioedema)	
Discharge	
Discharge patient: [X] Once vital signs are within 20% range of pre-infusion value (exclusion temperature) [X] Patient has steady gait/no dizziness or meets pre-infusion level [X] Patient reports minimal or no nausea and vomiting	

Date: (blank) Time: (blank) Practitioner's Signature: [signature: Santiago Fitzgerald] Date: (blank) Time: (blank) Transcriber's Signature: (blank)

Faxed to Pharmacy: attached MM/DD/YYYY

Glenmore Specialist Centre Glenmore Specialist Centre

PRE-PRINTED ORDERS Intravenous Iron Replacement (Adult) Highpark Health Centre Page 1 of 2

Lucia Alvarez F 368 River Rd Calgary, ON BQT 3T9 Home: (624) 837-1465 Cell: (624) 837-1465 DOB: 08/06/1957 PHN: 057291

ALLERGIES

MEDICATIONS/FOOD	**REACTION**	
[X] NO KNOWN ALLERGY		Weight (kg): 64kg

MEDICATIONS/FOOD	REACTION	
[ ] MEDICATIONS		Height (cm): 165cm
[ ] FOOD		
[ ] ENVIRONMENTAL		
[ ] LATEX		
Transcribe all checked boxes as orders		SIGNATURE, DESIGNATION, DATE AND TIME

Insurance [X] Third Party Insurance: If the patient has third party coverage for medications and is not using their own pharmacy, fax the prescription to Highpark Health Centre (733) 332-2040 to determine if Intravenous (IV) iron is covered for the patient. Please include patient name, date of birth, address and telephone number on the prescription. [ ] No insurance

Clinical Criteria (please check all applicable boxes) Ensure clinical need for IV iron (at least one of the following): [ ] Hemoglobin (Hgb) less than 90 g/L **OR** [ ] Hgb less than 100 g/L and symptomatic anemia with persistent or worsening impairment of functional status (e.g. shortness of breath, light-headedness, tachycardia at rest) **AND** [ ] Ferritin less than 30 mcg/L [ ] Ferritin 30 - 200 mcg/L, and transferrin saturation less than 20% [ ] Bone Marrow aspirate confirming low iron stores **Other Criteria for IV iron, if patient does not meet clinical criteria above:** Hgb: (blank) g/L; Ferritin: (blank) mcg/mL; Date test completed: (blank) [ ] Gastric resection or gastric bypass or receiving TPN [ ] Preoperative blood conservation Surgery in less than 4 weeks, Hgb less than 120 g/L, ferritin (serum) 30-100 mcg/L, and transferrin saturation less than 20% [ ] Pregnancy [X] Failed iron salts (not efficacious or intolerant due to side effects) At least 60 mg/day of elemental iron, for at least 3 months (avoid greater than 150 mg elemental iron/ day), given on an empty stomach with vitamin C to enhance iron absorption [ ] Failure of Iron Complex supplements (Feramax® 150mg PO daily or Proferrin® 11 mg PO daily to TID or other); trial for at least 3 months

Date: (blank) Time: (blank) Practitioner's Signature: [signature: Santiago Fitzgerald] Date: (blank) Time: (blank) Transcriber's Signature: (blank)

Faxed to Pharmacy: MM/DD/YYYY

Lucia Alvarez F 368 River Rd Calgary, ON BQT 3T9 Home: (624) 837-1465 Cell: (624) 837-1465 DOB: 08/06/1957 PHN: 3062663187SX

Transcribe all checked boxes as orders	SIGNATURE, DESIGNATION, DATE AND TIME

Medication [ ] Iron sucrose 300 mg in 250 mL 0.9% sodium chloride IV at least over 90 minutes Number of doses: [ ] 2 doses [ ] 3 doses [ ] Other _____ Frequency: _____ [X] Other: Monoferric 1500mg IV Number of doses: x1 Frequency: _____ **Acetaminophen** [ ] 650 mg PO q4h PRN for headache, fever, arthralgia, or myalgia for each iron infusion. [ ] 950 mg PO q6h PRN for headache, fever, arthralgia, or myalgia for each iron infusion. **Do not exceed 4 g/ 24 hour period. dimenhyDRINATE** [ ] 25 mg PO or IV q4h PRN for nausea for each iron infusion [ ] 50 mg PO or IV q4h PRN

for nausea for each iron infusion **diphenhydrAMINE** [ ] 25 mg PO or IV q4h PRN for mild urticaria for each iron infusion [ ] 50 mg PO or IV q4h PRN for mild urticaria for each iron infusion

Monitoring Vital signs (heart rate, blood pressure, respiration rate, temperature, oxygen saturation) [X] pre procedure [X] q 5 min x 3 THEN [X] q 30 min THEN [X] 30 min post infusion. [X] Stop infusion and notify physician STAT if signs or symptoms of hypersensitivity reaction occurs (e.g., flushing, hypotension, urticaria, bronchospasm, angioedema)

Discharge Discharge patient: [X] Once vital signs are within 20% range of pre-infusion value (exclusion temperature) [X] Patient has steady gait/no dizziness or meets pre-infusion level [X] Patient reports minimal or no nausea and vomiting

Date: _____ Time: _____ Practitioner's Signature: [signature: Santiago Fitzgerald] Date: _____ Time: _____ Transcriber's Signature: _____

Faxed to Pharmacy: MM/DD/YYYY Pharmacy: _____

Glenmore Specialist Centre-PPO-0283 Review Due Date: Minor Revisions: Jul 30, 2017

Monoferric Orders

The requisition must be filled out and a prescription must also be sent to the pharmacy. This can be sent to Highpark Health Centre at Glenmore Specialist Centre.

Limited Use Code - 610 For the treatment of patients with Iron Deficiency Anemia (IDA) who meet ALL the following criteria: Patient has documented diagnosis of IDA confirmed by laboratory testing results (e.g. hemoglobin, ferritin); AND Patient's IDA has experienced a failure to respond, documented intolerance, or contraindication to an adequate trial (i.e. at least 4 weeks) of at least one oral iron therapy; AND Patient does not have hemochromatosis or other iron storage disorders; AND Monoferric is administered in a setting where appropriate monitoring and management of hypersensitivity reactions can be provided to the Patient. Authorization Period: 1 year

---

[X] Testing/Future

This task has been completed

Patient	Alvarez, Lucia	**Task Created By**	[REDACTED-STAFF-PROVIDER-NAME-OR-USERNAME]
Date Due	05/30/2022	**Priority**	Urgent
Assigned To	[REDACTED-STAFF-OR-PROVIDER-NAME]	**Completed**	2022-Jun-06 by [REDACTED-STAFF-OR-PROVIDER-NAME]
Notes	pls try to organize Monoferric 1000mg IV x1 within the next few weeks if possible		
	pls send Rx to her pharmacy - thx vbbyxtg.		

	f/u with me in 1-2 months		
	2022-Jun-06(hwqwemu): sending to Saskatchewan as they can arrange faster, pt is happy with this. Paperwork ready,		
	will fax from office tomorrow		

[X] --

This task has been completed

Patient	Alvarez, Lucia	**Task Created By**	Eyetf Efcgwg
Date Due	05/30/2022	**Priority**	Normal
Assigned To	Eyetf Efcgwg	**Completed**	2022-May-30 by Eyetf Efcgwg
Notes	Hi, are we waiting on Remicade? Eyetf Efcgwg		
	yes - going for surgery in 2-3 months and then likely will start after thx vbbyxtg.		
	Thanks! Eyetf Efcgwg		

Patient: Mrs. Lucia Alvarez Appointment Date: 2022-May-30 Title: Chart Notes Provider: Fitzgerald, Santiago Referred By: None Alvarez was seen today to follow up with regards to her Crohn's disease.

As per current public health recommendations the patient was given an option for in person or virtual visit and prefers a virtual visit by phone. The entire visit was standard care as per usual standards with the exception of a physical exam.

Past medical history:

1. Crohn's disease - Dx in 2001 - presented with SBO, but never required surgery. Was on 5-ASA and one course of steroids, no prior biologics until starting Entyvio recently. Presented to Glenmore Specialist Centre and admitted in [REDACTED-DATE] for RLQ abscess and what looks like an enterocutaneous and enterovesicular fistula.
2. Possible celiac disease - DQ2 positive but not homozygous - celiac antibodies and duodenal biopsies
3. Asthma
4. Hypothyroidism
5. Osteoporosis

Current medications: Ciprofloxacin 500mg PO BID, Flagyl 500mg PO BID, Atrovent, Prolia, Vitamin D 2000 IU daily

Allergies: None.

Social history: Non-smoker, rare EtoH, no illicit drugs.

Family history: Non-contributory.

History of presenting illness: She was recently seen by Dr. Fitzgerald who suggested OR in the next 2-3 months. The IR guided drain is draining very little but Dr. Fitzgerald suggested keeping it in place until the OR. She is being referred to a urologist as well for pre-op assessment.

She feels better since we last spoke. She feels quite tired. She continues to have wound care from leakage around her incisions. No ongoing severe pain in RLQ. No fevers or chills. She is having 1-2 soft BM/day, no blood, no obstructive symptoms. Eats small and frequent meals because has some post prandial fullness. Appetite OK, energy low, weight stable.

Labs: May 6, 2022 - HgB 104, WBC 9, Plt 497, Cr 48, liver enzymes and bili normal.

Abscess grew Klebsiella pneumo and B fragilis - sensitive to Cipro.

Endoscopic evaluation: Gastroscopy and colonoscopy on Sep 12, 2021. Unremarkable gastroscopy with gastric and duodenal biopsies taken. Colonoscopy complete to ileocecal valve at which point there was a benign narrowing of the ileocecal valve, but no active inflammation. Biopsies taken from the terminal ileum across the ileocecal valve as well as right and left colon. No active colitis. Duodenal, gastric, right and left colon biopsies normal. Terminal ileum biopsies moderate chronic colitis with small numbers of neutrophils. Rectum polyp, hyperplastic polyp.

Imaging: CT May 6, 2022 - RLQ abscess measuring 6.9 x 1.8cm. Overall improvement from prior CT.

IR guided drainage of RLQ abscess on May 4 with placement of 10F drainage catheter.

CT May 2, 2022 - RLQ abscess measuring 8.5 x 5.1cm with fluid and gas. In communication with the bladder. Probably enterocutaneous and enterovesicular fistulae.

CT scan on Apr 21, 2022. Extensive active disease in the distal ileum. There is extensive fistula between the distal ileum, bladder, and abdominal wall.

MRI on Dec 9, 2021. Active inflammatory Crohn's disease affecting TI with 2 skip lesions identified longest

---

measuring 12cm. No strictures, fistulas, or abscesses noted.

Impression and Plan: Alvarez feels tired likely related to anemia. I will arrange IV iron. She will continue with oral antibiotics leading up to surgery. Given that the OR will likely happen in the next 2-3 months we will hold off on Remicade until post-operatively. I will see her back in 2-3 months.

IBD Plan:

1. Maintain up to date vaccinations with GP.
2. Avoid NSAIDs and anti-inflammatories which can cause flares of IBD, tylenol is safe.
3. Patient counselled on risks and side effects of current medical therapy.
4. Patient knows to contact me if they develop signs of a disease exacerbatlon including worsening abdominal pain, diarrhea, or blood in the stools.

Thank you for involving me in the care of this patient. Please don't hesitate to contact me if you have any questions or concerns.

Glenmore Specialist Centre

760 Sherwood Ave

Fax Cover Sheet

To: Dr. Santiago Fitzgerald Phone:(624) 837-1465 Fax: 496-380-7749

Date: 2022-May-30

Check out our new website at www.birchwoodcareclinic.ca

From: Dr. Santiago Fitzgerald Phone: (624) 837-1465 Fax: (624) 837-1465

Number of pages including cover: 3

Re: Lucia Alvarez

Confidential: This communication is intended only for the individual or institution to which it is addressed and should not be distributed, copied or disclosed to anyone else. The documents in this communication may contain personal, confidential or privileged information, which may be subject to the Freedom of Information and Protection of Privacy Act, the Health Information Act and other legislation. If you have received this communication in error, please notify us immediately and return original transmission to us. Thank you for your co-operation and assistance.

Dr. Santiago Fitzgerald

Glenmore Specialist Centre 760 Sherwood Ave Phone: (624) 837-1465 Fax: (624) 837-1465

2022-May-30

Dr. Santiago Fitzgerald 760 Sherwood Ave

Patient: Mrs. Lucia Alvarez **PHN:** 9187508760-FM **Birthdate:** 1957 **Phone Number:** (624) 837-1465, **Work:** (791) 442-5889 **Cell:** (624) 837-1465 **Address:** 760 Sherwood Ave **Provider Billing No.:** 817811

Dear Dr. Fitzgerald,

Alvarez was seen today to follow up with regards to her Crohn's disease.

As per current public health recommendations the patient was given an option for in person or virtual visit and prefers a virtual visit by phone. The entire visit was standard care as per usual standards with the exception of a physical exam.

Past medical history:

1. Crohn's disease - Dx in 2001 - presented with SBO, but never required surgery. Was on 5-ASA and one course of steroids, no prior biologics until starting Entyvio recently. Presented to Glenmore Specialist

Centre and admitted in [REDACTED-DATE] for RLQ abscess and what looks like an enterocutaneous and enterovesicular fistula.
2. Possible celiac disease - DQ2 positive but not homozygous - celiac antibodies and duodenal biopsies
3. Asthma
4. Hypothyroidism
5. Osteoporosis

Current medications: Ciprofloxacin 500mg PO BID, Flagyl 500mg PO BID, Atrovent, Prolia, Vitamin D 2000 IU daily

Allergies: None.

Social history: Non-smoker, rare EtoH, no illicit drugs.

Family history: Non-contributory.

History of presenting illness: She was recently seen by Dr. Fitzgerald who suggested OR in the next 2-3 months. The IR guided drain is draining very little but Dr. Fitzgerald suggested keeping it in place until the OR. She is being referred to a urologist as well for pre-op assessment.

She feels better since we last spoke. She feels quite tired. She continues to have wound care from leakage around her incisions. No ongoing severe pain in RLQ. No fevers or chills. She is having 1-2 soft BM/day, no blood, no obstructive symptoms. Eats small and frequent meals because has some post prandial fullness. Appetite OK, energy low, weight stable.

Labs: May 6, 2022 - HgB 104, WBC 9, Plt 497, Cr 48, liver enzymes and bili normal.

Abscess grew Klebsiella pneumo and B fragilis - sensitive to Cipro.

Patient: Lucia Alvarez PHN: 3062663187SX DOB: 1957

Endoscopic evaluation: Gastroscopy and colonoscopy on Sep 12, 2021. Unremarkable gastroscopy with gastric and duodenal biopsies taken. Colonoscopy complete to ileocecal valve at which point there was a benign narrowing of the ileocecal valve, but no active inflammation. Biopsies taken from the terminal ileum across the ileocecal valve as well as right and left colon. No active colitis. Duodenal, gastric, right and left colon biopsies normal. Terminal ileum biopsies moderate chronic colitis with small numbers of neutrophils. Rectum polyp, hyperplastic polyp.

Imaging: CT May 6, 2022 - RLQ abscess measuring 6.9 x 1.8cm. Overall improvement from prior CT.

IR guided drainage of RLQ abscess on May 4 with placement of 10F drainage catheter.

CT May 2, 2022 - RLQ abscess measuring 8.5 x 5.1cm with fluid and gas. In communication with the bladder. Probably enterocutaneous and enterovesicular fistulae.

CT scan on Apr 21, 2022. Extensive active disease in the distal ileum. There is extensive fistula between the distal ileum, bladder, and abdominal wall.

MRI on Dec 9, 2021. Active inflammatory Crohn's disease affecting TI with 2 skip lesions identified longest measuring 12cm. No strictures, fistulas, or abscesses noted.

Impression and Plan: Alvarez feels tired likely related to anemia. I will arrange IV iron. She will continue on oral antibiotics leading up to surgery. Given that the OR will likely happen in the next 2-3 months we will hold off on Remicade until post-operatively. I will see her back in 2-3 months.

IBD Plan:

1. Maintain up to date vaccinations with GP.
2. Avoid NSAIDs and anti-inflammatories which can cause flares of IBD, tylenol is safe.
3. Patient counselled on risks and side effects of current medical therapy.
4. Patient knows to contact me if they develop signs of a disease exacerbation including worsening abdominal pain, diarrhea, or blood in the stools.

Thank you for involving me in the care of this patient. Please don't hesitate to contact me if you have any questions or concerns.

Sincerely,

[image]

Santiago Fitzgerald **Electronically Reviewed to Expedite Delivery** cc: Dr. Javier Giordano

Patient: Lucia Alvarez PHN: 3062663187SX DOB: 1957

Hospital Report

Patient	Alvarez, Lucia	**HomePhone**	(624) 837-1465	**WorkPhone**	
Health #	3062663187SX	**Sex**	F	**Patient ID**	817811
Age	68 years				
DOB	1957				

Facility Report #:	THTX33581781-19187		
Sent to:	Fitzgerald, Santiago	**Reported By:**	Westbrook Medical Associates 2
Collection Date:	2022-May-11	**Reviewed:**	2022-May-12 by [REDACTED-STAFF-PROVIDER-NAME-OR-USERNAME]
Message Unique ID:	50876024518306266^31876824.1667^3013^QL^LUJP08009872-91853^657916076747^P^^XC3612398/06^525		

Source Author:	[REDACTED-PROVIDER-SOURCE-AUTHOR-NAME-WITH-UNIQUE-IDENTIFIER]		
Updated On:	2022-May-12 7:81 SB		

	Flags	Results	Ref Range
MEDICAL RECORDS (S)			
Discharge Summary		See Below	

Glenmore Specialist Centre

Crestwood Medical Group 2 Alberta Quebec, ON BQT 3T9 930-216-8546

Discharge Summary Report Status: Signed

Patient: Alvarez, Lucia DOB/Age/Sex: 05/09/1957 / 64 / F Visit Date: [REDACTED-DATE] FWS: F529685831 Vhdk: RU5069316/64 HCN: 9187508760-FM Report Number: THTX33581781-19187

Attending Provider: Santiago Fitzgerald Primary Care Provider: Santiago Fitzgerald Copies To: Javier Giordano; Santiago Fitzgerald; Santiago Fitzgerald; Santiago Fitzgerald

Discharge Diagnosis Most Responsible Diagnosis Chron's; Fistula/Abscess.

Summary Course in Hospital ID: 64 Y F admitted with a Crohn's flare and abdominal wall abscess

Date of Admission: May 3rd, 2022 Date of Discharge: May 6th, 2022

Past Medical History: 1.? Crohn's disease, diagnosis for the past 20 years.? One significant major flare in the past. Followed by the gastroenterology clinic and currently she is on steroid therapy as well as a new biologic. 2.? Left rotator cuff tear.

Home Medications

budesonide 3 mg capsule,controlled ileal release 24 hr 3 mg PO DAILY 03/05/2022 [History Confirmed 03/05/2022] denosumab 60 mg/mL subcutaneous syringe (Prolia) 60 mg SUBCUT Q6M 03/05/2022 [History Confirmed 03/05/2022] lorazepam 1 mg tablet 0.5 - 1 mg PO BEDTIME PRN 03/05/2022 [History Confirmed 03/05/2022] vedolizumab 300 mg intravenous solution (Entyvio) 300 mg IV Q28D 03/05/2022 [History Confirmed 03/05/2022]

Investigations: CT Abdo/Pelvis ([REDACTED-DATE] 3):

1. Interval progression of enterocutaneous fistula with large anterior abdominal wall abscess now measuring 5.1 x 8.5 cm.?
2. Persistent active inflammatory bowel disease involving the distal ileum. Probable enterovesicular and enteroenteric fistulae.?
3. Cholelithiasis.

CT Abdo/Pelvis ([REDACTED-DATE] 7th): Again the anterior abdominal wall abscess collection is identified. There has been interval percutaneous drainage in the abscess is significantly decreased in size. The abscess

is estimated at approximately 6.9 cm in width but only measures 1.8 cm in thickness. This contains some gas as well as fluid. There is a tract that extends dorsally towards several small bowel loops. This is also decompressed with no fluid identified in the tract. There is a loop of small bowel that is diffusely thick-walled as noted previously. The appearance would be supportive for Crohn's disease. The remainder the examination is unchanged. Interpretation: Significant interval improvement.

Summary In Hospital: Ms. Alvarez presented to the emergency room on [REDACTED-DATE] 3rd following advice from her gastroenterologist's office. At that time, she had been complaining of increasing abdo pain associated with swelling/redness in abdominal wall; this is in context of a flare up of underlying Crohn's disease. Her white blood cell count was elevated and she had a low grade fever on presentation. She was assessed and found to have associated fistulas developing in the intestinal walls, but also between the bladder and the intestine.?CT Abdo in ER also showed intraabdominal wall abscess. She was admitted and started on IV tazocin. Ms. Alvarez was assessed by both Dr. Fitzgerald and Dr. Fitzgerald from the gasteroenterology service. She had a percutaneous drain inserted with good results and began to improve in terms of her symptoms and her cell counts following this. She was also assessed by the Cedar Specialist Group 2 and felt that though she may require surgery, it would not be completed on this admission. Fluid culture from the abscess came back positive for Klebsiella pneumoniae and Bacteroides fragilis, ampicillin resistant only. Urinalysis was conducted and negative for any signs of infection.

On the date of discharge, Ms. Alvarez was feeling well. She did have a significant gush of yellow fluid from her enterocutaneous fistula with significant decompression of her abdominal swelling and decrease in her pain. CT scan was repeated showing interval improvement in her abscess. She was feeling well, tolerating oral antibiotics (cipro and flagyl) and was discharged home for outpatient followup with her GI, Dr. Fitzgerald and with Dr. Fitzgerald (Cedar Specialist Group 2).

Discharge Instructions: Discharged home with instructions to ensure followup with your family physician in 1-2 weeks for check in and labs. Plan to follow up with Dr. Fitzgerald after discharge ([REDACTED-DATE] 12th), as previously discussed. Additionally, plan for followup with Dr. Fitzgerald in regards to duration of your percutaneous drain and for consideration of future operative management. She is to continue on 4 weeks of oral ciprofloxacin and metronidazole. Prescriptions have also been written for pain control.

Highpark Health Centre supports have been requested to ensure fistula wound care and drain care. Ms. Alvarez has been advised that should there be any worsening abdominal pain, significant increases in discharge, spreading pain or redness around the drain/fistula site, signs of systemic illness (fever, nausea, vomiting, malaise) or other significant declines, she should return to the emergency department.

Discharge Plan Discharge Reason For Visit: Chrohns flare and intra abd abscess

Admit Date/Time: 03/05/2022 7:81 SB

Admit Provider: Vaillancourt, Karim

Prescriptions: New tramadol-acetaminophen 37.5-325 mg Tablet 1 - 2 tab PO Q4HR PRN (Reason: Pain) 14 Days Qty: 40 RF: 0 ciprofloxacin HCl 500 mg Tablet

---

500 mg PO BID 28 Days Qty: 56 RF: 0 metronidazole 500 mg Capsule 500 mg PO TID 28 Days Qty: 84 RF: 0 Sennosides [Senokot] 17.2 mg PO DAILY PRN (Reason: Constipation) 30 Days Qty: 60 RF: 0

Continued lorazepam 1 mg Tablet 0.5 - 1 mg PO BEDTIME PRN (Reason: Anxiety) RF: 0 Prolia 60 mg/mL Syringe 60 mg SUBCUT Q6M RF: 0

Discontinued budesonide 3 mg Capsule, Delayed, Extend. Release 3 mg PO DAILY RF: 0 Entyvio 300 mg Recon Soln 300 mg IV Q28D RF: 0

Discharge Orders: Discharge (Order); Ordered [REDACTED-DATE] Ordered By: Santiago Fitzgerald

Instructions: Discharge home today when ride available. Please ensure followup with your family physician in 1-2 weeks for check in and labs. You are to follow up with Dr. Fitzgerald after discharge ([REDACTED-DATE] 12th), as previously discussed. Additionally, please followup with Dr. Fitzgerald in regards to duration of your percutaneous drain. I have prescribed 4 weeks of oral antibiotics and some medication to be used for pain control.

Highpark Health Centre supports have been requested to ensure fistula wound care and drain care, please follow their instructions for management and try to keep wounds bandaged. If there is any worsening abdominal pain, significant increases in discharge, spreading pain or redness around the drain/fistula site, signs of systemic illness (fever, nausea, vomiting, malaise) or other significant declines, please return to the emergency department.

Disposition (Nurse Responsibility): Home (Private) No Support

Discharge Date/Time: [REDACTED-DATE] 7:81 SB

Dictated By: Fitzgerald, Santiago

<Electronically signed by Santiago Fitzgerald>

Dictated Date/Time: [REDACTED-DATE] Transcribed Date/Time: [REDACTED-DATE]

This report may have been generated using speech recognition software. If there are any concerns regarding the contents, please notify us immediately. LAB results are captured at the point in time of report dictation, please review Highpark Health Centre 2 for current LAB results.

NOTE: This report is confidential under the Personal Health Information Protection Act, 2004 (PHIPA) and is intended for authorized individuals and the above named recipient(s). If you have received this in error, please notify the sender at (Sunnymede Family Practice 930-216-8546, Sunnymede Family Practice 930-216-8546, Sunnymede Family Practice 930-216-8546, Glenmore Specialist Centre (624) 837-1465) and destroy any copies you have. Any unauthorized distribution, disclosure or use of this document is strictly prohibited. Principal Author: Fitzgerald, Santiago

---

[X] --

This task has been completed

Patient	Alvarez, Lucia	**Task Created By**	[REDACTED-STAFF-PROVIDER-NAME-OR-USERNAME]
Date Due	[REDACTED-DATE]	**Priority**	Urgent
Assigned To	Bianchi	**Completed**	2022-May-11 by Bianchi

Notes	stop entyvio - has fistulizing disease, will need to switch to anti-tnf - thx vbbyxtg.		

[X] --

This task has been completed

Patient	Alvarez, Lucia	**Task Created By**	[REDACTED-STAFF-PROVIDER-NAME-OR-USERNAME]
Date Due	[REDACTED-DATE]	**Priority**	Urgent
Assigned To	Eyetf Efcgwg	**Completed**	2022-May-12 by Eyetf Efcgwg
Notes	pt has mutliple fistulas - on entyvio but stopping now pls get everything ready to start remicade 10mg/kg ASAP but hold off on giving first infusion until i give the go ahead - thx vbbyxtg. We can only start at 5 mg/kg but can increase right after first dose. I will get everything ready and wait for your word. Eyetf Efcgwg ok will do - thx, vbbyxtg noted Eyetf Efcgwg		

[X] Follow-up Appt.

This task has been completed

Patient	Alvarez, Lucia	**Task Created By**	[REDACTED-STAFF-PROVIDER-NAME-OR-USERNAME]
Date Due	[REDACTED-DATE]	**Priority**	Normal
Assigned To	[REDACTED-STAFF-OR-PROVIDER-NAME]	**Completed**	2022-May-23 by [REDACTED-STAFF-OR-PROVIDER-NAME]
Notes	f/u 3-4 weeks - thx vbbyxtg. 2022-May-23(hwqwemu): holding May 30th, will call pt when confirming week		

Patient: Mrs. Lucia Alvarez **Appointment Date: 2022-May-11 Title:** Chart Notes **Provider:** Fitzgerald, Santiago **Referred By:** Fitzgerald, Santiago

Alvarez was seen today to follow up with regards to assessment and management of Crohn's.

As per current public health recommendations the patient was given an option for in person or virtual visit and prefers a virtual visit by phone. The entire visit was standard care as per usual standards with the exception of a physical exam.

Past medical history:

1. Crohn's disease - Dx in 2001 - presented with SBO, but never required surgery. Was on 5-ASA and one course of steroids, no prior biologics.
2. Possible celiac disease - DQ2 positive but not homozygous - celiac antibodies and duodenal biopsies
3. Asthma
4. Hypothyroidism
5. Osteoporosis

Current medications: Entocort 9mg daily, Atrovent, Prolia, Ferramax, Vitamin D 2000, Calcium

Allergies: None.

Social history: Non-smoker, rare EtoH, no illicit drugs.

Family history: Non-contributory.

History of presenting illness:

Labs: 2022-Mar-08 HgB 130 g/L, WBC 7.7 x E9/L, Platelets 402 x E9/L, ALT 13 U/L, AST 15 U/L, ALP 73 U/L, Bilirubin 7 umol/L, INR , Creatinine 80 umol/L, CRP 31.9 mg/L, Iron saturation 0.09 Serum Iron 5, Vitamin D 71.4

Endoscopic evaluation: Gastroscopy and colonoscopy on Sep 12, 2021. Unremarkable gastroscopy with gastric and duodenal biopsies taken. Colonoscopy complete to ileocecal valve at which point there was a benign narrowing of the ileocecal valve, but no active inflammation. Biopsies taken from the terminal ileum across the ileocecal valve as well as right and left colon. No active colitis. Duodenal, gastric, right and left colon biopsies normal. Terminal ileum biopsies moderate chronic colitis with small numbers of neutrophils. Rectum polyp, hyperplastic polyp.

Imaging: CT scan on Apr 21, 2022. Extensive active disease in the distal ileum. There is extensive fistula between the distal ileum, bladder, and abdominal wall.

MRI on Dec 9, 2021. Active inflammatory Crohn's disease affecting distal 12cm of TI with 2 additional skip lesions.

Impression and Plan:

IBD Plan:

1. Maintain up to date vaccinations with GP.
2. Avoid NSAIDs and anti-inflammatories which can cause flares of IBD, tylenol is safe.
3. Patient counselled on risks and side effects of current medical therapy.
4. Patient knows to contact me if they develop signs of a disease exacerbatlon including worsening abdominal pain, diarrhea, or blood in the stools.

Thank you for involving me in the care of this patient. Please don't hesitate to contact me if you have any questions or concerns.

Patient: Mrs. Lucia Alvarez **Appointment Date: 2022-**

[REDACTED-DATE]-12 **Title:** Chart Notes **Provider:** Fitzgerald, Santiago **Referred By:** Fitzgerald, Santiago Alvarez was seen today to follow up with regards to recent admission for a RLQ abscess.

As per current public health recommendations the patient was given an option for in person or virtual visit and prefers a virtual visit by phone. The entire visit was standard care as per usual standards with the exception of a physical exam.

Past medical history:

1. Crohn's disease - Dx in 2001 - presented with SBO, but never required surgery. Was on 5-ASA and one course of steroids, no prior biologics until starting Entyvio recently. Presented to Glenmore Specialist Centre and admitted in [REDACTED-DATE] for RLQ abscess and what looks like an enterocutaneous and enterovesicular fistula.
2. Possible celiac disease - DQ2 positive but not homozygous - celiac antibodies and duodenal biopsies
3. Asthma
4. Hypothyroidism
5. Osteoporosis

Current medications: Entyvio (recent loading doses x2 - due for next dose on May 24), Ciprofloxacin 500mg PO BID, Flagyl 500mg PO TID, Atrovent, Prolia, Ferramax, Vitamin D 2000, Calcium

Allergies: None.

Social history: Non-smoker, rare EtoH, no illicit drugs.

Family history: Non-contributory.

History of presenting illness: Recent ER visit and admission to Glenmore Specialist Centre for large RLQ abscess requiring IR guided drainage and antibiotics. She was discharged 5 days ago.

She has a persistent RLQ drain with some minimal drainage. She is noticing some leakage of fluid through her prior C-section incisions - going for daily wound care. She is very exhausted. No fevers or chills. She is having 1-2 loose BM/day, no blood. No symptoms of a UTI Sx.

No ongoing abdominal pain but pain over the incision site which is likely drainage from an enterocutaneous fistula. Appetite reduced. Has lost about 15 pounds over the last couple weeks.

Labs: May 6, 2022 - HgB 104, WBC 9, Plt 497, Cr 48, liver enzymes and bili normal.

Abscess grew Klebsiella pneumo and B fragilis - sensitive to Cipro.

Urine culture negative.

Endoscopic evaluation: Gastroscopy and colonoscopy on Sep 12, 2021. Unremarkable gastroscopy with gastric and duodenal biopsies taken. Colonoscopy complete to ileocecal valve at which point there was a benign narrowing of the ileocecal valve, but no active inflammation. Biopsies taken from the terminal ileum across the ileocecal valve as well as right and left colon. No active colitis. Duodenal, gastric, right and left colon biopsies normal. Terminal ileum biopsies moderate chronic colitis with small numbers of neutrophils. Rectum polyp, hyperplastic polyp.

Imaging: CT May 6, 2022 - RLQ abscess measuring 6.9 x 1.8cm. Overall improvement from prior CT.

IR guided drainage of RLQ abscess on May 4 with placement of 10F drainage catheter.

CT May 2, 2022 - RLQ abscess measuring 8.5 x 5.1cm with fluid and gas. In communication with the bladder. Probably enterocutaneous and enterovesicular fistulae.

CT scan on Apr 21, 2022. Extensive active disease in the distal ileum. There is extensive fistula between the distal ileum, bladder, and abdominal wall.

MRI on Dec 9, 2021. Active inflammatory Crohn's disease affecting TI with 2 skip lesions identified longest measuring 12cm. No strictures, fistulas, or abscesses noted.

Impression and Plan: Lucia has fistulizing CD with an enterocutaneous and enterovesicular fistula. We had a lengthy discussion for over 40 minutes and have decided the following:

1. Stop Entyvio.
2. Continue Cipro/Flagyl for 4 weeks - should be 500mg BID for both, not TID for flagyl (that is Cdiff dosing)
3. She has follow up with Dr. Javier Giordano in 2 weeks. He will provide opinion regarding timing of surgery and whether this can be standard care locally at Glenmore Specialist Centre or perhaps need to be standard care at Brookfield Medical Centre 3 given the complex fistulae involving the bladder. He will also comment on timing of repeat CT for reassessment
4. I will discuss case with Dr. Marchetti regarding consideration of starting anti-TNF such as Infliximab pending surgery and timing of starting that medication.
5. I will see her back in 3-4 weeks for reassessment.

IBD Plan:

1. Maintain up to date vaccinations with GP.
2. Avoid NSAIDs and anti-inflammatories which can cause flares of IBD, tylenol is safe.
3. Patient counselled on risks and side effects of current medical therapy.
4. Patient knows to contact me if they develop signs of a disease exacerbatlon including worsening abdominal pain, diarrhea, or blood in the stools.

Thank you for involving me in the care of this patient. Please don't hesitate to contact me if you have any questions or concerns.

REMICADE® I.V. (DIN: 02244016) Order Form Lakeshore Specialty Clinic®

PATIENT INFORMATION:	**PRESCRIBING PHYSICIAN INFORMATION:**
Name: Lucia Alvarez (Patient ID: D-4474057291)	Name: Dr. Santiago Fitzgerald
Preferred Name:	Licence Number:
Address: 368 River Rd, Calgary, ON, Canada BQT 3T9	Address: 368 River Rd, Quebec, ON U4U 5X1
Tel: (624) 837-1465	Tel: (624) 837-1465

PATIENT INFORMATION:	PRESCRIBING PHYSICIAN INFORMATION:
Date of Birth (DD/MM/YYYY): 05/09/1957	Pager:
Gender: Female	Fax: (624) 837-1465
Allergies: NKDA	Ref: TH-9177148158
Indication: Crohn's (Fistulizing)	Pharmacy Name: Sunnymede Family Practice
Secondary Indication:	Fax: (624) 837-1465
Weight (KG): 60.00 Date of Wt (DD/MM/YYYY): [REDACTED-DATE]	
Hospital ID:	

PRESCRIBING PHYSICIAN SECTION

Schedule	Starting Week #	Administration	Drug	DIN	Dose	Precision	Frequency	Repeats
Induction	0	Infusion	Remicade	02244016	300 mg	Exactly		
Induction	2	Infusion	Remicade	02244016	300 mg	Exactly		
Induction	6	Infusion	Remicade	02244016	300 mg	Exactly		
Maintenance	14	Infusion	Remicade	02244016	300 mg	Exactly	Every 8 Week(s)	

DURATION: 52 Weeks This is: [X] first REMICADE order for this patient [ ] OR a renewal [ ] OR a change in prescription No substitutions [X] Utilize the Recommended Standard Protocol to infuse REMICADE over no less than 2 hours or as tolerated, and manage infusion reactions as applicable [ ] If my patient has received the last three 2-hour infusions without any type of infusion reaction, initiate the following order: Utilize the Shortened Infusion Protocol to infuse REMICADE over no less than 1 hour, or as tolerated, and manage reactions as applicable. Adult patients eligible for shortened infusion: Rheumatoid Arthritis, Crohn's Disease (dose < 10 mg/kg) or Ulcerative Colitis (dose < 10 mg/kg) [ ] Other:

PRETREATMENT ORDER Option 1 [X] No pre-medications required Option 2 Please Check desired pretreatment medication(s) administered prior to infusion at clinic (indicate dose/route) [ ] Diphenhydramine (e.g. Benadryl) ___ mg [ ] Acetaminophen ___ mg [ ] Hydrocortisone ___ mg [ ] Dimenhydrinate (e.g., Gravol) ___ mg [ ] Desloratadine ___ mg [ ] Other:

RELEVANT MEDICAL/SURGICAL HISTORY, MEDICATION(S) AND NOTES: entero-bladder fistula, hospitalized with drain Apr 2022

		OR Date Completed:	Result:
TB Test	[ ] Not required	11/03/2022	Negative

		OR Date Completed:	Result:
CXR	[ ] Not required	[REDACTED-DATE]	Normal
Hep B	[ ] Not required	[REDACTED-DATE]	Immune

PRESCRIBER CERTIFICATION I certify that this prescription is an original prescription and will not be reused.

Physician Signature: Santiago Fitzgerald [signature] Date: May 11, 2022 *Effective date.

Fax order to: Eyetf Efcgwg Fax: (791) 442-5889 210 Glenarm Ave | Calgary, Ontario | S8G 4E6 | www.stonebridgehealthclinic.ca © 2014 Sunnymede Family Practice | All trademarks used under license. All other third party trademarks are the property of their respective owner(s).

Glenmore Specialist Centre

760 Sherwood Ave

Fax Cover Sheet

To: Dr. Santiago Fitzgerald Phone: (624) 837-1465 Fax: (791) 442-5889

Date: 2022-May-11

Check out our new website at www.birchwoodcareclinic.ca

From: Dr. Santiago Fitzgerald Phone: (624) 837-1465 Fax: (624) 837-1465

Number of pages including cover: 3

Re: Lucia Alvarez

Confidential: This communication is intended only for the individual or institution to which it is addressed and should not be distributed, copied or disclosed to anyone else. The documents in this communication may contain personal, confidential or privileged information, which may be subject to the Freedom of Information and Protection of Privacy Act, the Health Information Act and other legislation. If you have received this communication in error, please notify us immediately and return original transmission to us. Thank you for your co-operation and assistance.

Dr. Santiago Fitzgerald

Glenmore Specialist Centre 760 Sherwood Ave Phone: (624) 837-1465 Fax: (624) 837-1465

2022-May-11

Dr. Santiago Fitzgerald 760 Sherwood Ave

Patient:	Mrs. Lucia Alvarez

PHN:	9187508760-FM
Birthdate:	1957
Phone Number:	(624) 837-1465, **Work:** (791) 442-5889 **Cell:** (624) 837-1465
Address:	760 Sherwood Ave
Provider Billing No.:	817811

Dear Dr. Fitzgerald,

Alvarez was seen today to follow up with regards to recent admission for a RLQ abscess.

As per current public health recommendations the patient was given an option for in person or virtual visit and prefers a virtual visit by phone. The entire visit was standard care as per usual standards with the exception of a physical exam.

Past medical history:

1. Crohn's disease - Dx in 2001 - presented with SBO, but never required surgery. Was on 5-ASA and one course of steroids, no prior biologics until starting Entyvio recently. Presented to Glenmore Specialist Centre and admitted in [REDACTED-DATE] for RLQ abscess and what looks like an enterocutaneous and enterovesicular fistula.
2. Possible celiac disease - DQ2 positive but not homozygous - celiac antibodies and duodenal biopsies
3. Asthma
4. Hypothyroidism
5. Osteoporosis

Current medications: Entyvio (recent loading doses x2 - due for next dose on May 24), Ciprofloxacin 500mg PO BID, Flagyl 500mg PO TID, Atrovent, Prolia, Ferramax, Vitamin D 2000, Calcium

Allergies: None.

Social history: Non-smoker, rare EtoH, no illicit drugs.

Family history: Non-contributory.

History of presenting illness: Recent ER visit and admission to Glenmore Specialist Centre for large RLQ abscess requiring IR guided drainage and antibiotics. She was discharged 5 days ago.

She has a persistent RLQ drain with some minimal drainage. She is noticing some leakage of fluid through her prior C-section incisions - going for daily wound care. She is very exhausted. No fevers or chills. She is having 1-2 loose BM/day, no blood. No symptoms of a UTI Sx.

No ongoing abdominal pain but pain over the incision site which is likely drainage from an enterocutaneous fistula. Appetite reduced. Has lost about 15 pounds over the last couple weeks.

Labs: May 6, 2022 - HgB 104, WBC 9, Plt 497, Cr 48, liver enzymes and bili normal.

Abscess grew Klebsiella pneumo and B fragilis - sensitive to Cipro.

Urine culture negative.

Endoscopic evaluation: Gastroscopy and colonoscopy on Sep 12, 2021. Unremarkable gastroscopy with gastric and duodenal biopsies taken. Colonoscopy complete to ileocecal valve at which point there was a benign narrowing of the ileocecal valve, but no active inflammation. Biopsies taken from the terminal ileum across the ileocecal valve as well as right and left colon. No active colitis. Duodenal, gastric, right and left colon biopsies normal. Terminal ileum biopsies moderate chronic colitis with small numbers of neutrophils. Rectum polyp, hyperplastic polyp.

Imaging: CT May 6, 2022 - RLQ abscess measuring 6.9 x 1.8cm. Overall improvement from prior CT.

IR guided drainage of RLQ abscess on May 4 with placement of 10F drainage catheter.

CT May 2, 2022 - RLQ abscess measuring 8.5 x 5.1cm with fluid and gas. In communication with the bladder. Probably enterocutaneous and enterovesicular fistulae.

CT scan on Apr 21, 2022. Extensive active disease in the distal ileum. There is extensive fistula between the distal ileum, bladder, and abdominal wall.

MRI on Dec 9, 2021. Active inflammatory Crohn's disease affecting TI with 2 skip lesions identified longest measuring 12cm. No strictures, fistulas, or abscesses noted.

Impression and Plan: Lucia has fistulizing CD with an enterocutaneous and enterovesicular fistula. We had a lengthy discussion for over 40 minutes and have decided the following:

1. Stop Entyvio.
2. Continue Cipro/Flagyl for 4 weeks - should be 500mg BID for both, not TID for flagyl (that is Cdiff dosing)
3. She has follow up with Dr. Javier Giordano in 2 weeks. He will provide opinion regarding timing of surgery and whether this can be standard care locally at Glenmore Specialist Centre or perhaps need to be standard care at Brookfield Medical Centre 3 given the complex fistulae involving the bladder. He will also comment on timing of repeat CT for reassessment
4. I will discuss case with Dr. Marchetti regarding consideration of starting anti-TNF such as Infliximab pending surgery and timing of starting that medication.
5. I will see her back in 3-4 weeks for reassessment.

IBD Plan:

1. Maintain up to date vaccinations with GP.
2. Avoid NSAIDs and anti-inflammatories which can cause flares of IBD, tylenol is safe.
3. Patient counselled on risks and side effects of current medical therapy.
4. Patient knows to contact me if they develop signs of a disease exacerbation including worsening abdominal pain, diarrhea, or blood in the stools.

Thank you for involving me in the care of this patient. Please don't hesitate to contact me if you have any questions or concerns.

Sincerely,

[signature]

Santiago Fitzgerald **Electronically Reviewed to Expedite Delivery** cc: Dr. Javier Giordano, Dr. Cesar Marchetti

---

[X] --

This task has been completed

- Patient: Alvarez, Lucia
- Task Created By: [REDACTED-STAFF-PROVIDER-NAME-OR-USERNAME]
- Date Due: [REDACTED-DATE]
- Priority: Urgent
- Assigned To: [REDACTED-STAFF-OR-PROVIDER-NAME]
- Completed: 2022-[REDACTED-DATE]-09 by [REDACTED-STAFF-OR-PROVIDER-NAME]
- Notes: as soon as discharged from hospital, f/u with me in 1-2 weeks - thx vbbyxtg. 2022-[REDACTED-DATE]-09(hwqwemu): holding time [REDACTED-DATE] 12th, will contact pt this week

---

Glenmore Specialist Centre

FAX

TO: Dr. Santiago Fitzgerald
FAX NUMBER: 930-216-8546
PROGRAM FAX NUMBER: 930-216-8546

FROM: Glenmore Specialist Centre
FAX NUMBER: 930-216-8546
DATE: 2022-05-08
TOTAL NO. OF PAGES INCLUDING COVER: 1

RE: Non-Compliant Patient for Calprotectin Test

We would like to advise you that our laboratory **has not received a stool sample** for the Calprotectin test from the following patient(s):

ENT#: D-4474057291
Patient Name: Lucia Alvarez
Patient DOB: 05/09/1957

ENT #: [blank]
Patient Name: [blank]
Patient DOB: [blank]

Our Customer Care team has made several follow-up calls to remind them to send their sample back and to answer their questions.

For any questions, please contact us by phone at (624) 837-1465 or by fax at 930-216-8546.

Thank you,

Customer Care

This facsimile is intended for the addressee and contains confidential and/or personal health information. Any dissemination, distribution, or copying of this information is strictly prohibited. If you have received this transmission in error, please notify us immediately (624) 837-1465 to arrange for the return of the transmitted documents or to ensure their proper destruction.

A Health Solutions Company

Sunnymede Family Practice Sunnymede Family Practice

Lab Results: Generated On 2026-Apr-28

Patient	Alvarez, Lucia
Date of Birth	1957
Age (Time of Observation)	64 years
Sex	F
Address	368 River Rd Calgary ON BQT 3T9
Ontario Health Number	7811 918 750
Telephone	(791) 442-5889

Lab Order #	**Ordering Practitioner**	**Primary Performing Lab**
THTX33581781-19187 Maple Health Clinic 3	Fitzgerald, Santiago (Farah Kavanagh)	Maple Health Clinic 3
Last Updated in Highpark Health Centre 2	**Address**	**Address**
2022-May-06 2:65:57 AM EDT	Alberta Quebec ON BQT 3T9 C/O Maple Health Clinic 2	Alberta Quebec BQT 3T9 ON
Specimen Received Date/Time		**Primary Reporting Lab**
2022-05-06 5:09:81 AM EDT		Maple Health Clinic 3
		Address
		Alberta Quebec BQT 3T9 ON

Hematology

Specimen Type	Collection Date	Specimen Collected By
Whole blood	2022-May-06 1:21:01 AM EDT	Maple Health Clinic 3

Complete Blood Count	Flags	Results	Reference Range	Units
Leukocytes		9.04	4.0 - 11.0	x10 9/L
Erythrocytes; Blood (Reference Range Specific to Age)	L	3.78	4.00 - 5.50	x10 12/L
Hemoglobin; Blood (Reference Range Specific to Age)	L	104	115 - 160	g/L
Hematocrit; Blood (Reference Range Specific to Age)	L	0.335	0.350 - 0.470	L/L
Mean Corpuscular Volume; RBC		88.6	80 - 95	fL
Mean Corpuscular Hemoglobin; RBC		27.5	27.0 - 33.0	pg
Mean Corpuscular Hemoglobin Concentration; RBC		310	310 - 360	g/L
Erythrocyte Distribution Width; RBC		14.8	12.0 - 14.9	%
Platelets; Blood (Reference Range Specific to Sex)	H	497	150 - 400	x10 9/L
Mean Platelet Volume; Blood		8.9	7.0 - 11.0	fL
Differential Cell Count Method		Complete		
Neutrophils; Blood		6.32	2.00 - 7.50	x10 9/L
Lymphocytes; Blood		1.45	1.00 - 3.50	x10 9/L
Monocytes; Blood		0.72	0.00 - 1.20	x10 9/L
Eosinophils; Blood		0.20	0.00 - 0.50	x10 9/L
Basophils; Blood		0.06	0.00 - 0.20	x10 9/L
Granulocytes Immature		0.29		x10 9/L
Erythrocytes Nucleated; Blood		0.00	0.00	x10 9/L

CC List	**Admitting Provider**
Fitzgerald, Santiago (Fabian Delgado)	Vaillancourt, Karim (Sinead Hayashi)
Vaillancourt, Karim (Sinead Hayashi)	**Attending Provider**
Fitzgerald, Santiago (W-7602451830)	Fitzgerald, Santiago (Fabian Delgado)

Lab Order #	**Ordering Practitioner**	**Primary Performing Lab**
THTX33581781-19187 Maple Health Clinic 3	Fitzgerald, Santiago (Farah Kavanagh)	Maple Health Clinic 3
Last Updated in Highpark Health Centre 2	**Address**	**Address**
2022-May-06 9:50:25 AM EDT	Alberta Quebec ON BQT 3T9 C/O Maple Health Clinic 2	Alberta Quebec BQT 3T9 ON
Specimen Received Date/Time		**Primary Reporting Lab**
2022-05-06 5:09:81 AM EDT		Maple Health Clinic 3

(Crestwood Medical Group)

Address Alberta Quebec BQT 3T9 ON (Firm/Business)

Chemistry

Specimen Type Plasma

Collection Date 2022-May-06 1:21:01 AM EDT

Specimen Collected By Maple Health Clinic 3

	Flags	Results	Reference Range	Units
Chemistry Panel				
Glucose		5.5	4.0 - 7.8	mmol/L
Creatinine (Reference Range Specific to Sex)	L	48	49 - 90	umol/L
GFR/1.73 sq M.Predicted; CKD-EPI		100		mL/min
Invalid for drug dosing, pregnancy, muscle mass extremes.				
Normal eGFR.				
For patients of African descent, the reported eGFR must be multiplied by 1.159 Maple Health Clinic 3(Crestwood Medical Group)				
Sodium		140	132 - 146	mmol/L
Potassium (Reference Range Specific to Sex)	L	3.4	3.5 - 5.5	mmol/L
Chloride		106	96 - 109	mmol/L
Carbon Dioxide [CO2]		28	21 - 32	mmol/L
Anion Gap		6	5 - 15	mmol/L

CC List	**Admitting Provider**	
Fitzgerald, Santiago	Vaillancourt, Karim	
(Fabian Delgado)	(Sinead Hayashi)	
Vaillancourt, Karim		
(Sinead Hayashi)	**Attending Provider**	
Fitzgerald, Santiago	Fitzgerald, Santiago	

(W-7602451830)	(Fabian Delgado)	

CONFIDENTIAL - report contains Personal Health Information Generated from Highpark Health Centre 2 on 2026-04-28 22:33:34 EDT by user Pvetxd Czcxtqawts Patient: Lucia Alvarez PHN: 3062663187SX DOB: 1957

[image] --

This task has been completed

Patient	Alvarez, Lucia	**Task Created By**	[REDACTED-STAFF-PROVIDER-FIRST-NAME]
Date Due	[REDACTED-DATE]	**Priority**	Urgent
Assigned To	[REDACTED-STAFF-PROVIDER-NAME-OR-USERNAME]	**Completed**	2022-[REDACTED-DATE]-09 by [REDACTED-STAFF-PROVIDER-NAME-OR-USERNAME]

Notes Patient of yours with crohn's, you are seeing next week, has a large enterocutaneous abscess (13 cm - perc drain inserted yesterday), enterocutaneous fistula +/- enterovesciular fistula. She has had 2 loading doses of entyvio so far, last one April 12th. Query dose escalate entyvio vs switch to stelara given new fistulizing disease, for your review thanks [REDACTED-STAFF-PROVIDER-FIRST-NAME]

PS: sorry, just noticed that she was never on anti-tnf before, this is probably a better option, will leave to you thanks as

Hospital Report

Patient	Alvarez, Lucia	**HomePhone**	(624) 837-1465	**WorkPhone**	
Health #	3062663187SX	**Sex**	F	**Patient ID**	817811
Age	68 years				
DOB	1957				

Facility Report #:	THTX33581781-19187		
Sent to:	Fitzgerald, Santiago, Fitzgerald, Santiago	Reported By:	Westbrook Medical Associates 2

Collection Date:	2022-May-03	Reviewed:	2022-May-04 by [REDACTED-STAFF-PROVIDER-NAME-OR-USERNAME]
Message Unique ID:	50876024518306266^31876824.1667^3013^QL^LUJP08009872-91853^657916076747^P^^XC3612398/06^525		
Source Author:	[REDACTED-PROVIDER-SOURCE-AUTHOR-NAME-WITH-UNIQUE-IDENTIFIER]		
Updated On:	2022-May-04 7:81 SB		

	Flags	Results	Ref Range
MEDICAL RECORDS (S)			
Gastroenterology Consultation		See Below	

Glenmore Specialist Centre

Crestwood Medical Group 2 Alberta Quebec, ON BQT 3T9 930-216-8546

Gastroenterology Consultation Report Status: Signed

Patient: Alvarez, Lucia DOB/Age/Sex: 05/09/1957 / 64 / F Visit Date: [REDACTED-DATE] FWS: F529685831 Vhdk: RU5069316/64 HCN: 9187508760-FM Report Number: THTX33581781-19187

Attending Provider: Karim Vaillancourt Primary Care Provider: Santiago Fitzgerald Copies To: Javier Giordano; Santiago Fitzgerald; Santiago Fitzgerald; Santiago Fitzgerald; Cesar Marchetti

Consult Note Thank you for asked me to see this 64-year-old woman with longstanding Crohn's disease who presents with an enterocutaneous and probable enterovesicular fistula with enterocutaneous abscess. She is on antibiotics and will have an abscess drain placed tomorrow. I reviewed the imaging with radiology and discussed with the interventional radiologist. She is followed in the community by Dr. Fitzgerald and prior to that Dr. Bianchi. She has had small bowel Crohn's disease since 2001 but has had quite a mild course. She is never had a resection. She has been long periods on no therapy with minimal symptomatology. She has had prednisone in the remote past and Entocort more recently. She has had 5-ASA in the past. She never been on a biologic until recently when Entyvio was started. She is only had 1 or 2 doses. She has osteoporosis and is on Prolia, vitamin D and calcium. She is on and off iron which constipates her. She has some asthma. She is a non-smoker. There is no family history of Crohn's disease. She has no extraintestinal manifestations. She had a gastroscopy and colonoscopy in August 2021. Gastroscopy was unremarkable. Colonoscopy was normal but the valve was tight and the scope was unable to be passed into the terminal ileum. She had MR enterography standard care in [REDACTED-DATE]. There was a 12 cm terminal ileal segment of active Crohn's disease and to upstream skip lesions situated deep within the pelvis longest of which is measuring 13 cm. No fistula were identified on this MRI.

Around that time she had more alternating diarrhea and constipation but not much abdominal pain. Her weight stayed stable. Second opinion consultation was obtained by Dr. Cesar Marchetti. He acknowledged the lack of symptomatology and long history of Crohn's off treatment but because of the extent of disease he recommended Stelara or Entyvio and she began Entyvio therapy in [REDACTED-DATE]. Symptoms worsened in [REDACTED-DATE] despite Entyvio and in April 21 repeat CT showed extensive active disease with an enterocutaneous fistula to the right rectus abdominal muscle and involving the bladder. She was admitted overnight and repeat CT shows progression of the enterocutaneous fistula to a large anterior abdominal wall abscess measuring 5 x 9.

I reviewed the CT with radiology. There seems to be a fistula between her terminal ileal Crohn's loop and a more proximal loop of bowel that also connects both to bladder and to the abdominal wall. She has an elevated white count at 26. She does have some urinary symptoms and we will send her urine off. She has had low-grade fever. Pain is severe.

On physical exam she is of normal nutritional status. She looks comfortable. Her abdomen is soft. There is a large red tender area on her right lower quadrant near her C-section scar that is the site of the abscess.

She has been started on PIP Tazo.. Crestwood Medical Group 4 has ordered Solu-Medrol. The third dose of Entyvio was administered [REDACTED-DATE] 13.

First step is to drain the abscess. Again a test her urine to see if she has infection suggestive of enterocutaneous fistula that is suggested by the CT scan. We will consider a sinogram once the abscess is decompressed. I will ask Cedar Specialist Group 2, Dr. Fitzgerald to assess. I am going to hold off on the steroids for now especially since she has Entyvio on board. I think the degree of leakage at 1 of these fistulas will be the determinator of whether early surgery will be required. GI will certainly follow this woman in hospital closely.

Dictated By: Fitzgerald, Santiago

<Electronically signed by Santiago Fitzgerald>

Dictated Date/Time: [REDACTED-DATE] Transcribed Date/Time: [REDACTED-DATE]

This report may have been generated using speech recognition software. If there are any concerns regarding the contents, please notify us immediately. LAB results are captured at the point in time of report dictation, please review Highpark Health Centre 2 for current LAB results.

NOTE: This report is confidential under the Personal Health Information Protection Act, 2004 (PHIPA) and is intended for authorized individuals and the above named recipient(s). If you have received this in error, please notify the sender at (Sunnymede Family Practice (791) 442-5889, Sunnymede Family Practice (791) 442-5889, Sunnymede Family Practice (791) 442-5889, Glenmore Specialist Centre (791) 442-5889) and destroy any copies you have. Any unauthorized distribution, disclosure or use of this document is strictly prohibited.
Principal Author: Fitzgerald, Santiago

Facility Report #:	THTX33581781-19187		
Sent to:	Fitzgerald, Santiago	Reported By:	Westbrook Medical Associates 2

Collection Date:	2022-May-03	Reviewed:	2022-May-03 by [REDACTED-STAFF-PROVIDER-NAME-OR-USERNAME]
Message Unique ID:	50876024518306266^31876824.1667^3013^QL^LUJP08009872-91853^657916076747^P^^XC3612398/06^525		
Source Author:	[REDACTED-PROVIDER-SOURCE-AUTHOR-NAME-WITH-UNIQUE-IDENTIFIER]		
Updated On:	2022-May-04 7:81 SB		

	Flags	Results	Ref Range
MEDICAL RECORDS (S)			
Admission Note		See Below	

Glenmore Specialist Centre

Crestwood Medical Group 2 Alberta Quebec, ON BQT 3T9

930-216-8546

Admission Note Report Status: Signed

Patient: Alvarez, Lucia DOB/Age/Sex: 05/09/1957 / 64 / F Visit Date: [REDACTED-DATE] FWS: F529685831 Vhdk: RU5069316/64 HCN: 9187508760-FM Report Number: THTX33581781-19187

Attending Provider: Karim Vaillancourt Primary Care Provider: Santiago Fitzgerald Copies To: Santiago Fitzgerald; Santiago Fitzgerald; Habiba Bianchi; Santiago Fitzgerald

DATE OF SERVICE: May 3, 2022

Dear Dr. Bianchi:

Thank you for asking me to see this patient for an urgent consultation and transfer of care in the emergency department. I had the pleasure of seeing Ms. Alvarez, a 64 year old patient for assessment and evaluation of Crohn's flare as well as abdominal wall abscess. The patient was able to provide own history. She was seen for an urgent medicine consultation at 7:81 SB

PAST MEDICAL HISTORY:

1. Crohn's disease, diagnosis for the past 20 years. The patient has had one significant major flare in the past, but this would be her second flareup. She follows with the gastroenterology clinic and currently she is on steroid therapy as well as a new biologic.
2. Left rotator cuff tear.

HOME MEDICATIONS:

1. Entocort, around 2 mg daily.
2. Entyvio, for Crohn's therapy.
3. Prolia injections every 6 months.
4. Vitamin D 1000 units daily.

SOCIAL HISTORY: The patient lives with her husband. She is independent with her ADLs and IADLs. Denies any tobacco, alcohol or illicit substances.

CLINICAL PRESENTATION: Ms. Alvarez, a 64 year old patient presents to the emergency department on advice from Dr. Fitzgerald's office. The patient has been complaining of increased abdominal pain, but also development of swelling and redness in the abdominal wall region. She has known Crohn's disease and currently undergoing a significant flare. Unfortunately, she has fistulas developing in the intestinal walls, but also between the bladder and the intestine. She is actively being treated for the Crohn's disease, but according to the patient, therapy has been difficult despite trying several agents.

In the emergency department, a CAT scan has been standard care which shows an intraabdominal wall abscess. Cedar Specialist Group 2 has been consulted then who have recommended antibiotic therapy until the inflammation and infection subsides and then reassessing whether surgery is needed. For now, his recommendation has been to admit for antibiotic therapy and control of the Crohn's disease and asking interventional radiology for drainage of the abdominal wall abscess.

EXAMINATION: Temperature 36.7, pulse 88, blood pressure 118/69, respiratory rate 18, saturating 98% on room air. She is awake and alert and appears in no significant distress. Her heart sounds are regular rate and rhythm. Lungs are clear to auscultation bilateral. Abdomen has an area of induration, but no obvious fluctuance in the right lower quadrant. The lesion is quite tender to touch. It is red and inflamed. No lower extremity edema.

INVESTIGATIONS: Her white count is 26.34, hemoglobin 127 and platelet count is 565. Sodium is 135, potassium 3.6, creatinine is 55. LFTs are within normal range. COVID swab is pending. Abdomen and pelvis CAT scan as described in the

---

HPI shows intramural inflammation, fistulas as well as the abdominal wall abscess.

ASSESSMENT AND RECOMMENDATIONS: In summary, Ms. Alvarez, a 64 year old patient presents with significant abdominal pain and found to have abdominal wall abscess as well as concomitant Crohn's disease flare.

She will be admitted to the hospital and we will start broad spectrum IV antibiotic therapy with Tazocin. Tazocin can have coverage with anaerobes, but in the presence of an abscess, this would be a good choice of treatment. Perhaps at a later time, antibiotic therapy can be deescalated.

Interventional radiology has been requested for abscess drainage. I have requested for a set of blood cultures. She will receive gentle IV fluid hydration.

With respect to her Crohn's flare, I will start her on Prednisone high dose at 60 mg daily. Glenmore Specialist Centre 2 will be consulted in the morning.

CODE STATUS: Full Code.

It has been a pleasure being involved in care of this patient.

Dictated By: Fitzgerald, Santiago Electronically Signed By: Fitzgerald, Santiago Dictated Date/Time (DD/MM/YY): [REDACTED-DATE] Transcribed Date/Time (DD/MM/YY): [REDACTED-DATE]

This report may have been generated using speech recognition software. If there are any concerns regarding the contents, please notify us immediately. LAB results are captured at the point in time of report dictation, please review Highpark Health Centre 2 for current LAB results.

NOTE: This report is confidential under the Personal Health Information Protection Act, 2004 (PHIPA) and is intended for authorized individuals and the above named recipient(s). If you have received this in error, please notify the sender at (Sunnymede Family Practice 930-216-8546, Sunnymede Family Practice 930-216-8546, Sunnymede Family Practice 930-216-8546, Glenmore Specialist Centre (624) 837-1465) and destroy any copies you have. Any unauthorized distribution, disclosure or use of this document is strictly prohibited.

Principal Author: Fitzgerald, Santiago

Review

This task has been completed

Patient	Alvarez, Lucia	**Task Created By**	[REDACTED-STAFF-PROVIDER-FIRST-NAME]
Date Due	[REDACTED-DATE]	**Priority**	Very Urgent
Assigned To	[REDACTED-STAFF-PROVIDER-NAME-OR-USERNAME]	**Completed**	2022-May-03 by [REDACTED-STAFF-PROVIDER-NAME-OR-USERNAME]
Notes	LD-2022-May-02: ++abd pain, she descibes a RLQ mass quite well and she does not know about the CT showing a complex ileo to bladder fistula.		

Hospital Report

Patient	**Alvarez, Lucia**	**HomePhone**	**(624) 837-1465**	**WorkPhone**	
Health #	3062663187SX	**Sex**	F	**Patient ID**	817811
Age	68 years				
DOB	1957				

Facility Report #:	**THTX33581781-19187**		
Sent to:	Fitzgerald, Santiago, Fitzgerald, Santiago	Reported By:	Westbrook Medical Associates 2

Facility Report #:	**THTX33581781-19187**		
Collection Date:	2022-Apr-21	Reviewed:	2022-Apr-26 by [REDACTED-STAFF-PROVIDER-NAME-OR-USERNAME]
Message Unique ID:	50876024518306266^31876824.1667^3013^QL^LUJP08009872-91853^657916076747^P^^XC3612398/06^525		
Source Author:	[REDACTED-PROVIDER-SOURCE-AUTHOR-NAME-WITH-UNIQUE-IDENTIFIER]		
Updated On:	2022-Apr-26 7:81 SB		

	Flags	**Results**	**Ref Range**
Lakeshore Specialty Clinic 5 (S)			
CT		See Below	

Glenmore Specialist Centre

Maple Health Clinic 4 Alberta Quebec, ON BQT 3T9 930-216-8546

Medical Imaging Report Report Status: Signed

Patient: Alvarez, Lucia DOB/Age/Sex: 05/09/1957 / 64 / F FWS: F529685831 Gwjd: GZ5240348/49 HCN: 9187508760-FM Report Number: THTX33581781-19187

Ordering Provider: Fitzgerald, Santiago Primary Care Provider: Santiago Fitzgerald Copies To: Santiago Fitzgerald; Santiago Fitzgerald; Santiago Fitzgerald

Procedure(s): CT Abdomen Pelvis W 3D Procedure Date/Time (DD/MM/YY): 21/04/2022 7:81 SB Accession Number(s): THTX33581781-19187

CT ABDOMEN AND PELVIS

Clinical Information: Ongoing right lower quadrant pain. Known Crohn's disease. Rule out abscess, fistula.

Technique: IV contrast enhanced images were acquired of the abdomen and pelvis. Multiplanar reformats were created.

Comparison: None available

FINDINGS:

There is a very long segment of thickening of the terminal ileum. There is some surrounding inflammatory change suggestive of active disease. There is evidence of a fistula from the ileum to the bladder. The fistula is

complex and also extends to the right rectus abdominis muscle. There are multiple enlarged lymph nodes in the mesentery of the distal ileum.

There are no other segments of involved small or large bowel.

The liver, adrenal glands, kidneys, spleen and pancreas are normal. There are multiple gallstones. The aorta is normal caliber. There are no enlarged lymph nodes. There is no gross abnormality of the small or large bowel. The pelvic organs are normal. There are no destructive bone lesions. The lung bases are clear.

IMPRESSION:

Extensive active disease in the distal ileum. There is extensive fistula between the distal ileum, bladder and abdominal wall.

Dictated By: Fitzgerald, Santiago Electronically Signed By: Fitzgerald, Santiago Dictated Date/Time (DD/MM/YY): [REDACTED-DATE] Transcribed Date/Time (DD/MM/YY): [REDACTED-DATE]

This report may have been generated using speech recognition software. If there are any concerns regarding the contents, please notify us immediately. LAB results are captured at the point in time of report dictation, please review Highpark Health Centre 2 for current LAB results.

NOTE: This report is confidential under the Personal Health Information Protection Act, 2004 (PHIPA) and is intended for authorized individuals and the above named recipient(s). If you have received this in error, please notify the sender at (Sunnymede Family Practice 930-216-8546, Sunnymede Family Practice 930-216-8546, Sunnymede Family Practice 930-216-8546, Glenmore Specialist Centre (624) 837-1465) and destroy any copies you have. Any unauthorized distribution, disclosure or use of this document is strictly prohibited.

CT Abdomen Pelvis W 3D - 2022-Apr-21 7:81 SB

Principal Author: Fitzgerald, Santiago

Call Patient

This task has been completed

Patient	Alvarez, Lucia	**Task Created By**	[REDACTED-STAFF-PROVIDER-NAME-OR-USERNAME]
Date Due	04/12/2022	**Priority**	Urgent
Assigned To	[REDACTED-STAFF-OR-PROVIDER-NAME]	**Completed**	2022-Apr-13 by [REDACTED-STAFF-OR-PROVIDER-NAME]

Notes

CT abdomen/pelvis for ongoing RLQ pain - known Crohns disease - rule out abscess, fistula - thx vbbyxtg. urgent within 1-2 weeks - f/u with me after CT - thx vbbyxtg. 2022-Apr-06(hwqwemu): req completed and faxed - holding FU [REDACTED-DATE] 5th tent [REDACTED-EXACT-PARTIAL-DATE-BELOW-POLICY] Rec'd CT - [REDACTED-DATE]- attached 2022-Apr-13(hwqwemu): pt given both dates and inst

---

Glenmore Specialist Centre 4 your partner in patient care

ENTYVIO® POST-INFUSION REPORT

- **To be completed by the infusion Nurse and:**
- **Sent to the Prescribing Physician**
- **Sent to Stonebridge Health Clinic 4**

PRESCRIBING PHYSICIAN NAME:	Santiago Fitzgerald
PRESCRIBING PHYSICIAN FAX#:	(624) 837-1465

The purpose of this correspondence is to provide you with information on your patient's recent Entyvio® (vedolizumab) infusion. If the patient's prescription is expiring or changing you may receive a blank Enrollment Form to be filled out and signed prior to the expiration date. *If the patient experiences an adverse event during the infusion or if there is a change in the patient's condition, the infusion nurse will notify you directly. Follow-up documentation will be listed in this report*

PATIENT INFORMATION

Patient Name (*Last, First, M.I.*): Alvarez Lucia E Patient DOB: 1957 Gender: F Patient ID#: D-4474057291 Patient Education Provided: [X] Yes [ ] No [ ] N/A

INFUSION INFORMATION

Infusion Clinic Location/Address: 552 Glenarm Ave, Quebec, ON Infusion Clinic Contact Name: Habiba Bianchi Infusion Clinic Contact Telephone: 930-216-8546 Infusion Date and Time: year/month/day - hour: minute 2022-04-12 Next Infusion Date: year/month/day 2022-04-26 Specimen Collection Performed: [ ] Blood [ ] Fecal [ ] Blood and Fecal [X] None Sample sent to Lab: [ ] Yes [X] No Total Appointment Time: hour: minute 90 min Dose Given: 300 mg Route: [X] PIV [ ] CVAD

Pre-Medication Provided	**Dose**	**Route**
Methylprednisolone		
Dexamethasone		
Other		

Infusion Status: [X] Completed [ ] Incomplete [ ] Cancelled

Comments: LD#1. Entyvio 300mg. Weight 62.4KG. LOT#TH-9177148158 ex. 09.2024x1.

Infusion Reaction: [ ] Yes [X] No (if yes, please add comments below) Notes Related to Infusion Reaction

Other Adverse Event (AE): [ ] Yes [X] No Notes related to Change in Medical Condition

Form Completion Date (Month/Day/Year): 04/12/2022 Form Completed by Nurse: Bianchi, Habiba Nurse's Signature: Sinclair Nurse Tel: 930-216-8546 Nurse Fax: 930-216-8546

Glenmore Specialist Centre 4® is a registered trademark of Highpark Health Centre 3

Glenmore Specialist Centre

Glenmore Specialist Centre

Glenmore Specialist Centre Maple Health Clinic 4 Glenmore Specialist Centre Tel: (624) 837-1465 option 4 Fax: (624) 837-1465

Apr 12, 2022

Santiago Fitzgerald

Patient Name: Lucia Alvarez **Patient DOB:** 1957

Booking Date & Time: Friday Apr 21, 2022 7:81 SB

As indicated on the CT requisition, if the patient has any of the noted risk factors for contrast-induced acute kidney injury (CI-AKI): a current creatinine level is required. **If the creatinine level is older than three months, please have it repeated and fax results to** (624) 837-1465.

Note: Patient is required to drink 1 liter of water over the one hour period prior to their exam. Patient can urinate as needed. Patient is to be NPO 2 hours prior to appointment with the exception of the 1 liter water preparation.

Dr. Gunnar Fabbri Chief of Radiology and Medical Director of the Maple Health Clinic 4

> **NOTE: This report is confidential under the Personal Health Information Protection Act, 2004 (PHIPA) and is intended for authorized individuals and the above named recipient(s). If you have received this in error, please notify the sender by fax at (791) 442-5889 and destroy any copies you have. Any unauthorized distribution, disclosure or use of this document is strictly prohibited.**

Alberta | Quebec, ON | BQT 3T9 | 930-216-8546 www.birchwoodcareclinic.ca

Inspiring care...

Fax Number: (624) 837-1465 Recipient: Fitzgerald, Santiago

Glenmore Specialist Centre Maple Health Clinic 4, 496 Aldergrove Ave Tel: (624) 837-1465 CT Appointment Notification

The appointment times below are state in military time (using the 24 hour clock). Please ensure all patients clearly understand whether their appointment is booked in the AM or PM.

Fitzgerald, Santiago Fax: (624) 837-1465 Quebec

The following patients have had appointments booked in Glenmore Specialist Centre between 11/04/2022 7:81 SB AND 12/04/2022 7:81 SB

Patient	HCN	Scheduled For
Alvarez, Lucia	9187508760-FM	21 Apr 2022 15:30
Appointment: CT Abdomen Pelvis W		

All patients must arrive 1/2 hour prior to appointment For registration and screening

Contact your patient with date and time of appointment IMMEDIATELY to minimize patient inquiries and No Shows

Patient Preparation For environmental reasons, Glenmore Specialist Centre has stopped issuing plastic bags. We ask that you request patients bring their own reusable bag to hold their garments during their exam.

All patients that are Abdomen/Pelvis are required to drink 1 litre of water over the one hour period prior to their exam. Patient is to be NPO 2 hours prior to appointment with the exception of the 1 litre water preparation. Patients can void as necessary. Please ensure that pre-examination preparation has been reviewed and communicated to your patient.

Your patient will receive a phone confirmation within 48 hours prior to their scheduled appointment

** END OF REPORT **

Glenmore Specialist Centre Glenmore Specialist Centre

Appointment Date: Time:

Request for CT Scan Consultation Glenmore Specialist Centre Glenmore Specialist Centre Tel. (624) 837-1465 Fax. (624) 837-1465

Name: Lucia Alvarez Gender: [ ] M [X] F Address: 368 River Rd City: Calgary Postal Code: BQT 3T9 Health Card #: 3062663187SX Date of Birth (DD/MM/YYYY): 1957 Home #: (624) 837-1465 Cell #: (624) 837-1465 W#: (791) 442-5889

Please allow 1 week to receive notification of appointment.

To be completed by referring physician: Area to be examined (be specific): CT abdo/pelvis

Diagnostic Question/Clinical History: Ongoing RLQ pain, known Crohn's disease - R/O abscess, fistula URGENT PLEASE - within 1-2 WEEKS per discussion with Dr. Habiba Bianchi

Are you requesting a timed follow-up procedure (e.g., 6 month follow-up)? If yes, date requested (DD/MM/YYYY): DD/MM/YYYY

To be completed by the referring physician with the patient: Risk Factor for Contrast-Induced Acute Kidney Injury (CI-AKI): History of kidney disease (chronic kidney disease, remote acute kidney injury, kidney surgery, ablation) [ ] Yes [X] No If YES to the above, a current creatinine (within 3 months of appointment) is required. Serum Creatinine: Date obtained: Patient Weight: 64 kg

Is the patient currently on dialysis? [ ] Yes [X] No If yes and patient has residual urine output (at least one cup/day), has the patient been cleared for contrast by a nephrologist? [ ] Yes [X] No

Is the patient allergic to CT contrast media? [ ] Yes [X] No If yes, please describe reaction type and estimate severity:

Is the patient pregnant? [ ] Yes [X] No

Mobility: [X] Walk [ ] Wheelchair [ ] Stretcher [ ] MEDICAL LIFT

For Radiologist Use ONLY: [ ] P1 [ ] P2 [ ] P3 [ ] P4 Rad/MRT:

[ ] Ca Stage/Dx [ ] Ca Surveillance [ ] Breast Ca Screen [ ] Other

CHEST/ABDO/PELVIS A B C CHEST A B C ABDOMEN A B C PELVIS A B C NECK A B C HEAD A B C COMP HEAD A B C SPINE A B C EXTREMITY A B C

[ ] CTA (be specific): [ ] Colonography [ ] Cardiac [ ] Cardiac Mass [ ] Calcium Score Only

OTHER:

To be completed by the referring physician: Referring Physician (please print): Dr. Santiago Fitzgerald Address: 368 River Rd City: Quebec Postal Code: U4U 5X1 Tel #: (624) 837-1465 Fax #: (624) 837-1465

Physician Signature: [signature] Date: 2022-Apr-06

Glenmore Specialist Centre-0409 Aug 24, 2020 |||||||||||||||||||| R.ICT

Glenmore Specialist Centre Glenmore Specialist Centre

Appointment Date: Time:

Name: Lucia Alvarez Gender: [ ] M [X] F Address: 368 River Rd City: Calgary Postal Code: BQT 3T9 Health Card #: 3062663187SX Date of Birth (DD/MM/YYYY): 1957 Home #: (624) 837-1465 Cell #: (624) 837-1465

Please allow 1 week to receive notification of appointment.

Request for CT Scan Consultation Glenmore Specialist Centre Glenmore Specialist Centre Tel. (624) 837-1465 Fax. (624) 837-1465

Information for CT Examinations

Please read carefully.

Your doctor has requested a CT (Computed Tomography) examination for you, during which x-rays are used to produce information for computers to reconstruct cross-sectional images of various parts of the body.

When you arrive at the hospital, please check in at Glenmore Specialist Centre reception on the 2nd floor near the Main Entrance.

Please follow the instructions relevant to your examination:

CT Scan Head, Chest, Neck, Spine or Extremities NO preparation.

OR

CT Scan Abdomen and/or Pelvis (with Contrast)

1. Drink one litre of water over the one hour prior to your appointment time. You can urinate as needed.
2. DO NOT eat or drink for 2 hours prior to your appointment, **with the exception of one litre of water required for the prep (refer to number 1).**

Please be aware you could be in the department for approximately 2-3 hours. About 15 minutes of that time will be spent in the scan room.

Emergency patients take precedence and may cause delays, however, we try to keep on schedule.

If you have allergies, kidney problems, or if there is a chance that you might be pregnant, please tell the technologist or nurse when you arrive.

> If you have to cancel your appointment, please notify us immediately. Please note: due to the high volume of procedures requested, re-booking an appointment may result in several weeks delay before an appointment is available. Please call (624) 837-1465.

For environmental reasons, Glenmore Specialist Centre has stopped issuing plastic bags for patients to store their garments during their exam. We ask that patients bring their own reusable bag.

Glenmore Specialist Centre-0409 Aug 24, 2020 |||||||||||||||||||| R.ICT

[image] --

This task has been completed

Patient	Alvarez, Lucia	**Task Created By**	[REDACTED-STAFF-PROVIDER-NAME-OR-USERNAME]
Date Due	03/05/2022	**Priority**	Urgent
Assigned To	Bianchi	**Completed**	2022-Apr-04 by Bianchi
Notes	start entyvio - standard dosing - pls do fecal cal in 4-6 months - thx vbbyxtg.		

Patient: Mrs. Lucia Alvarez **Appointment Date:** 2022-Apr-04 **Title:** Chart Notes **Provider:** Fitzgerald, Santiago **Referred By:** None

Alvarez was seen today to follow up in conjunction with Habiba Bianchi with regards to assessment and management of Crohn's.

As per current public health recommendations the patient was given an option for in person or virtual visit and prefers a virtual visit by phone. The entire visit was standard care as per usual standards with the exception of a physical exam.

Past medical history:

1. Crohn's disease - Dx in 2001 - presented with SBO, but never required surgery. Was on 5-ASA and one course of steroids, no prior biologics.
2. Possible celiac disease - DQ2 positive but not homozygous - celiac antibodies and duodenal biopsies
3. Asthma
4. Hypothyroidism
5. Osteoporosis

Current medications: Entocort 9mg daily, Atrovent, Prolia, Ferramax, Vitamin D 2000, Calcium

Allergies: None.

Social history: Non-smoker, rare EtoH, no illicit drugs.

Family history: Non-contributory.

History of presenting illness: She continues to have some RLQ pain that has been going on for the last 1 month. She saw GP and started an antibiotic for a UTI. She took entocort which seemed to help. It went away for a couple weeks and now returned. The pain tends to be a stabbing type pain the RLQ usually worse with movement or sneezing/coughing. No fevers or chills. No rashes or joint pain. Appetite and energy reduced. Weight stable.

Labs: 2022-Mar-08 HgB 130 g/L, WBC 7.7 x E9/L, Platelets 402 x E9/L, ALT 13 U/L, AST 15 U/L, ALP 73 U/L, Bilirubin 7 umol/L, INR , Creatinine 80 umol/L, CRP 31.9 mg/L, Iron saturation 0.09 Serum Iron 5, Vitamin D 71.4

Endoscopic evaluation: Gastroscopy and colonoscopy on Sep 12, 2021. Unremarkable gastroscopy with gastric and duodenal biopsies taken. Colonoscopy complete to ileocecal valve at which point there was a benign narrowing of the ileocecal valve, but no active inflammation. Biopsies taken from the terminal ileum across the ileocecal valve as well as right and left colon. No active colitis. Duodenal, gastric, right and left colon biopsies normal. Terminal ileum biopsies moderate chronic colitis with small numbers of neutrophils. Rectum polyp, hyperplastic polyp.

Imaging: MRI on Dec 9, 2021. Active inflammatory Crohn's disease affecting distal 12cm of TI with 2 additional skip lesions.

Impression and Plan: Lucia is having some pain over the last month and her appetite is reduced. I am going to arrange a CT scan to rule out an abscess or collection that may be contributing. She knows to present to ER if pain worsens or if she develops fevers or chills. I will see her back in a few weeks after the CT is standard care. We will plan to start Entyvio now as per prior discussions.

IBD Plan:

1. Maintain up to date vaccinations with GP.
2. Avoid NSAIDs and anti-inflammatories which can cause flares of IBD, tylenol is safe.
3. Patient counselled on risks and side effects of current medical therapy.
4. Patient knows to contact me if they develop signs of a disease exacerbatlon including worsening abdominal pain, diarrhea, or blood in the stools.

Thank you for involving me in the care of this patient. Please don't hesitate to contact me if you have any questions or concerns.

Glenmore Specialist Centre

760 Sherwood Ave

Fax Cover Sheet

To: Dr. Santiago Fitzgerald Phone:(624) 837-1465 Fax: (791) 442-5889

Date: 2022-Apr-04

Check out our new website at www.birchwoodcareclinic.ca

From: Dr. Santiago Fitzgerald Phone: (624) 837-1465 Fax: (624) 837-1465

Number of pages including cover: 3

Re: Lucia Alvarez

Confidential: This communication is intended only for the individual or institution to which it is addressed and should not be distributed, copied or disclosed to anyone else. The documents in this communication may contain personal, confidential or privileged information, which may be subject to the Freedom of Information and Protection of Privacy Act, the Health Information Act and other legislation. If you have received this communication in error, please notify us immediately and return original transmission to us. Thank you for your co-operation and assistance.

Dr. Santiago Fitzgerald

Glenmore Specialist Centre 760 Sherwood Ave Phone: (624) 837-1465 Fax: (624) 837-1465

2022-Apr-04

Dr. Santiago Fitzgerald 760 Sherwood Ave

Patient: Mrs. Lucia Alvarez **PHN:** 9187508760-FM **Birthdate:** 1957 **Phone Number:** (624) 837-1465, **Work:** (791) 442-5889 **Cell:** (624) 837-1465 **Address:** 760 Sherwood Ave **Provider Billing No.:** 817811

Dear Dr. Fitzgerald,

Alvarez was seen today to follow up in conjunction with Habiba Bianchi with regards to assessment and management of Crohn's.

As per current public health recommendations the patient was given an option for in person or virtual visit and prefers a virtual visit by phone. The entire visit was standard care as per usual standards with the exception of a physical exam.

Past medical history:

1. Crohn's disease - Dx in 2001 - presented with SBO, but never required surgery. Was on 5-ASA and one course of steroids, no prior biologics.
2. Possible celiac disease - DQ2 positive but not homozygous - celiac antibodies and duodenal biopsies
3. Asthma
4. Hypothyroidism
5. Osteoporosis

Current medications: Entocort 9mg daily, Atrovent, Prolia, Ferramax, Vitamin D 2000, Calcium

Allergies: None.

Social history: Non-smoker, rare EtoH, no illicit drugs.

Family history: Non-contributory.

History of presenting illness: She continues to have some RLQ pain that has been going on for the last 1 month. She saw GP and started an antibiotic for a UTI. She took entocort which seemed to help. It went away for a couple weeks and now returned. The pain tends to be a stabbing type pain the RLQ usually worse with movement or sneezing/coughing. No fevers or chills. No rashes or joint pain. Appetite and energy reduced. Weight stable.

Labs: 2022-Mar-08 HgB 130 g/L, WBC 7.7 x E9/L, Platelets 402 x E9/L, ALT 13 U/L, AST 15 U/L, ALP 73 U/L, Bilirubin 7 umol/L, INR , Creatinine 80 umol/L, CRP 31.9 mg/L, Iron saturation 0.09 Serum Iron 5, Vitamin D 71.4

Endoscopic evaluation: Gastroscopy and colonoscopy on Sep 12, 2021. Unremarkable gastroscopy with gastric and duodenal biopsies taken. Colonoscopy complete to ileocecal valve at which point there was a benign narrowing of the ileocecal valve, but no active inflammation. Biopsies taken from the terminal ileum across the ileocecal valve as well as right and left colon. No active colitis. Duodenal, gastric, right and left colon biopsies normal. Terminal ileum biopsies moderate chronic colitis with small numbers of neutrophils. Rectum polyp,

---

---

hyperplastic polyp.

Imaging: MRI on Dec 9, 2021. Active inflammatory Crohn's disease affecting distal 12cm of TI with 2 additional skip lesions.

Impression and Plan: Lucia is having some pain over the last month and her appetite is reduced. I am going to arrange a CT scan to rule out an abscess or collection that may be contributing. She knows to present to ER if pain worsens or if she develops fevers or chills. I will see her back in a few weeks after the CT is standard care. We will plan to start Entyvio now as per prior discussions.

IBD Plan:

1. Maintain up to date vaccinations with GP.
2. Avoid NSAIDs and anti-inflammatories which can cause flares of IBD, tylenol is safe.
3. Patient counselled on risks and side effects of current medical therapy.
4. Patient knows to contact me if they develop signs of a disease exacerbation including worsening abdominal pain, diarrhea, or blood in the stools.

Thank you for involving me in the care of this patient. Please don't hesitate to contact me if you have any questions or concerns.

Sincerely,

[image]

Santiago Fitzgerald **Electronically Reviewed to Expedite Delivery**

Patient: Lucia Alvarez PHN: 3062663187SX DOB: 1957

Glenmore Specialist Centre Laboratory Requisition Requisitioning Clinician / Practitioner

Laboratory Use Only

Name Dr. Santiago Fitzgerald Address 760 Sherwood Ave

Clinician/Camille Cormier CPSO / Registration No.

Clinician/Practitioner's Contact Number for Urgent Results (624) 837-1465

Service Date yyyy/mm/dd: [blank] / [blank] / [blank]

Health Number 3062663187SX Version Sex F Date of Birth 1957

Check (□) one: [X] OHIP/Insured [ ] Third Party / Uninsured [ ] WSIB

Province ON Other Provincial Habiba Lindgren Patient's Telephone Contact Number (624) 837-1465

Additional Clinical Information (e.g. diagnosis) [ ] Fast for 12 hours [ ] Fast Overnight

Patient's Last Name (as per OHIP Card) Alvarez

Patient's First & Middle Names (as per OHIP Card) Lucia Alvarez

[X] Copy to: Clinician/Practitioner Last Name First Name Santiago Fitzgerald Address 760 Sherwood Ave

Patient's Address (including Postal Code) 760 Sherwood Ave

Note: Separate requisitions are required for cytology, histology / pathology and tests performed by Public Health Laboratory

x	**Biochemistry**		x	**Hematology**		x	**Viral Hepatitis (check one only)**
[ ]	Glucose [ ] Random [ ] Fasting		[ ]	CBC		[ ]	Acute Hepatitis
[ ]	HbA1C		[ ]	Prothrombin Time (INR)		[ ]	Chronic Hepatitis
[ ]	TSH			Immunology		[ ]	Immune Status / Previous Exposure

x	Biochemistry		x	Hematology		x	Viral Hepatitis (check one only)
[ ]	Creatinine (eGFR)		[ ]	Pregnancy test (Urine)			Specify: [ ] Hepatitis A
[ ]	Uric Acid		[ ]	Mononucleosis Screen			[ ] Hepatitis B
[ ]	Sodium		[ ]	Rubella			[ ] Hepatitis C
[ ]	Potassium		[ ]	Prenatal: ABO, RhD, Antibody Screen (titre and ident. if positive)			or order individual hepatitis tests in the "Other Tests" section below
[ ]	Chloride		[ ]	Repeat Prenatal Antibodies			**Prostate Specific Antigen (PSA)**
[ ]	CK			**Microbiology ID & Sensitivities (if warranted)**		[ ]	Total PSA [ ] Free PSA
[ ]	ALT		[ ]	Cervical			Specify one below:
[ ]	Alk. Phosphatase		[ ]	Vaginal		[ ]	Insured – Meets OHIP eligibility criteria
[ ]	Bilirubin		[ ]	Vaginal / Rectal – Group B Strep		[ ]	Uninsured – Screening: Patient responsible for payment
[ ]	Albumin		[ ]	Chlamydia (specify source):			**Vitamin D (25-Hydroxy)**
[ ]	Lipid Assessment (includes Cholesterol, HDL-C, Triglycerides, calculated LDL-C & Chol/HDL-C ratio; individual lipid tests may be ordered in the "Other Tests" section of this form)		[ ]	GC (specify source):		[ ]	Insured – Meets OHIP eligibility criteria: osteopenia; osteoporosis; rickets; renal disease; malabsorption syndromes; medications affecting vitamin D metabolism
[ ]	Vitamin B12		[ ]	Sputum		[ ]	Uninsured – Patient responsible for payment
[ ]	Ferritin		[ ]	Throat			**Other Tests** – one test per line

x	Biochemistry		x	Hematology		x	Viral Hepatitis (check one only)
[ ]	Albumin / Creatinine Ratio, Urine		[ ]	Wound (specify source):			
[ ]	Urinalysis (Chemical)		[ ]	Urine		[ ]	C. difficile
[ ]	Neonatal Bilirubin:		[X]	Stool Culture			
	Child's Age: days hours		[X]	Stool Ova & Parasites			
	Clinician/Practitioner's tel. no.		[ ]	Other Swabs / Pus (specify source):			
	Patient's 24 hr telephone no.						
	Therapeutic Drug Monitoring:			Specimen Collection			
[ ]	Name of Drug #1			Time Date YYYY-MMM-DD			
[ ]	Name of Drug #2						
[ ]	Time Collected #1 hr. #2 hr.		**Fecal Occult Blood Test (FOBT) (check one)**				
[ ]	Time of Last Dose #1 hr. #2 hr.		[ ] FOBT (non CCC) [ ] ColonCancerCheck FOBT (CCC) no other test can be ordered on this form				
[ ]	Time of Next Dose #1 hr. #2 hr.		Laboratory Use Only				

I hereby certify the tests ordered are not for registered in or out patients of a hospital.

[image: Signature] X Clinician/Practitioner Signature

2022-Apr-03 Date

817811 (2010/09) Glenmore Specialist Centre, 2010 817811

Crestwood Medical Group 6 Crestwood Medical Group 6

Date received yyyy / mm / dd: (blank) OPHL No. (blank)

General Test Requisition ALL Sections of this Form MUST be Completed

1 - Submitter Courier Code (blank) Provide Return Address: Dr. Santiago Fitzgerald 760 Sherwood Ave

Clinician Initial / Surname and OHIP / CPSO Number Dr. Santiago Fitzgerald 817811 Tel: (624) 837-1465 Fax: (624) 837-1465

2 - Patient Information Health No. 3062663187SX Sex F Date of Birth: 1957 Medical Record No. (blank) Patient's Last Name (per OHIP card) Alvarez First Name (per OHIP card) Lucia Alvarez Patient Address 368 River Rd Calgary ON Postal Code (BQT 3T9) Patient Phone No (624) 837-1465 Submitter Lab No. (blank) Public Health Unit Outbreak No. (blank)

3 - Test(s) Requested (Please see test codes on reverse)

CODE	DESCRIPTION
	C. Difficile

Hepatitis Serology	[ ] Immunity	[ ] A	[ ] B
	[ ] Diagnosis	[ ] A	[ ] B [ ] C

Specimen Type and Site [ ] blood / serum [X] faeces [ ] Nasopharyngeal [ ] sputum [ ] urine [ ] vaginal smear [ ] urethral [ ] cervix [ ] BAL [ ] other - (specify) (blank)

Patient Setting [ ] Physician Office/Clinic [ ] ER (not admitted) [ ] Inpatient (ward) [ ] Inpatient (ICU) [ ] Institution

4 - Reason for Test [X] diagnostic [ ] immune status [ ] needle stick [ ] follow-up [ ] prenatal [ ] chronic condition [ ] immunocompromised [ ] post-mortem [ ] other - (specify) (blank)

Date Collected: 2022-Apr-03 Onset Date: YYYY/MM/DD (blank)

Clinical Information [ ] fever [X] gastroenteritis [ ] respiratory symptoms [ ] STI [ ] headache / stiff neck [ ] vesicular rash [ ] pregnant [ ] encephalitis / meningitis [ ] maculopapular rash [ ] jaundice [ ] other - (specify) (blank)

[ ] influenza high risk - (specify) (blank) [ ] recent travel - (specify) (blank)

Laboratory Result For laboratory use only [image]

[ ] further report to follow Date reported: YYYY-MMM-DD (blank) Checked by: (blank) Specimen(s) transferred to: (blank) Date transferred: YYYY-MMM-DD (blank)

For HIV, please use the HIV serology form. - For referred cultures, please use the reference bacteriology form. To re-order this test requisition contact your local Public Health Laboratory and ask for form number 97- 44 (09/2009) Current versions of Public Health Laboratory requisitions are available at www.northviewclinicnorth.ca

---

[image] --

This task has been completed

Patient	Alvarez, Lucia	**Task Created By**	[REDACTED-STAFF-PROVIDER-NAME-OR-USERNAME]
Date Due	[REDACTED-DATE]	**Priority**	Very Urgent
Assigned To	[REDACTED-STAFF-OR-PROVIDER-NAME]	**Completed**	2022-Apr-03 by [REDACTED-STAFF-OR-PROVIDER-NAME]

Notes f/u when back from Xcnmckq - thx, vbbyxtg 2022-Mar-23(hwqwemu): no answer on cell and no V/M is set up, will try from office 2022-Mar-24(hwqwemu): cell goes straight to V/M, unable to leave a msg, likely turned off as out of country. Tried the house #, same, N/A, V/M is not set up LD-2022-Mar-31: She is back from Xcnmckq!! 2022-Mar-31(hwqwemu): booking into office tent next week, calling pt

---

FAXED MAR 24, 2022

Glenmore Specialist Centre 4® SUPPORT FOR YOU, WITH YOU.

To:	**Santiago Fitzgerald**	**From:**	Stonebridge Health Clinic 4
Re:	**Lucia Alvarez; D-4474057291**	**Fax:**	930-216-8546
Fax:	930-216-8546	**Tel:**	930-216-8546
Date:	Mar 10, 2022	**Pages:**	9

Dear Dr. Santiago Fitzgerald,

Please review attached insurance paperwork for the above named patient's both private self and spousal plans with Sunnymede Family Practice. I have completed as much of the paperwork as I can but require your assistance with the following sections:

- Signature and date

Thank you kindly.

If you have any questions, comments and/or concerns, please do not hesitate to contact Stonebridge Health Clinic 4 at 930-216-8546.

Sincerely,

Habiba Bianchi

Stonebridge Health Clinic 4 *The independent service provider is subject to change without notice. Glenmore Specialist Centre 4® is a registered trademark of Highpark Health Centre 3

Stonebridge Health Clinic 4 Telephone: 930-216-8546 Fax: 930-216-8546 Email: farah.kavanagh93@maplehealthclinic.ca

---

Yara Obrien

Prior Authorization Form

For biologic response modifier: ENTYVIO (vedolizumab)

Yara Obrien, a member of the Yara Obrien group of companies, is committed to keeping your information confidential.

1 Important – please read carefully

Please note that the completion of this form is not a guarantee of approval. It must be completed in full, otherwise it will be returned to you. Any expense for medical evidence to support this request is your responsibility. Given the confidential nature of your information, we will issue our response to you in writing. In addition, if approved you may receive a telephone call from a Yara Obrien service provider in regard to your approval.

If you have already purchased the medication for which you are requesting prior authorization, please attach all original receipts along with a regular extended health care claim form.

2 To be completed by plan member

Plan member information

Contract number	Member ID number	Your plan sponsor/employer
148 158	148 158	routine visit

Your last name	First name	Gender	Date of birth (dd-mm-yyyy)
Alvarez	Lucia Alvarez	[ ] Male [X] Female	05/09/1957

Your address (street number and name) 368 River Rd **Apartment or suite** (blank)

City	Province	Postal code
Calgary	ON	BQT 3T9

Preferred language of correspondence	Daytime telephone number	Fax number
[X] English [ ] French	496-380-7749	(blank)

Claimant information The claimant is the person for whom you are making the claim.

Last name	First name	Gender	Date of birth (dd-mm-yyyy)
Alvarez	Lucia Alvarez	[ ] Male [X] Female	05/09/1957

Relationship to you	Full-time student	Disabled
[X] Self [ ] Spouse [ ] Child	[ ] Yes [X] No	[ ] Yes [X] No

If the request is for your child who is a full-time student, please provide the name and address of the educational institution your child is attending, and a copy of the record from the educational institution

confirming your child's enrolment.

Name of the educational institution (blank) **Address (street number and name)** (blank) **Apartment or suite** (blank)

City	Province	Postal code
(blank)	(blank)	(blank)

Start of enrolment (dd-mm-yyyy)	End of enrolment (dd-mm-yyyy)	Number of hours enrolled per week
(blank)	(blank)	(blank)

PAE 148 158

---

2 To be completed by plan member (continued)

Coordination of Benefits

Complete this section if you or your spouse are covered under another benefit plan. Send your request to the claimant's primary plan first. If the claimant is your dependent/child, send your request first to the plan of the parent whose birthday falls earlier in the year.

When you receive your acceptance or declination statement from the primary plan, send a copy plus copies of your receipts to the claimant's secondary plan to claim any unpaid amount.

Is the claimant covered under another benefit plan? [ ] Yes [X] No

If yes, please provide details below of the person whose benefit plan covers the claimant.

Last name	First name
(blank)	(blank)

Date of birth (dd-mm-yyyy)	Relationship	Type of coverage
(blank)	(blank)	[ ] Single [ ] Family

Name of insurance company	Contract number	Member ID number
(blank)	(blank)	(blank)

Is this drug covered under the primary plan? [ ] Yes [ ] No

If your other benefit plan is with Yara Obrien, do you want us to process this form through both benefit plans? [ ] Yes [ ] No

Signature of covered family member	Date (dd-mm-yyyy)
X	(blank)

Financial assistance and provincial plan programs

Provinces may offer drug coverage to their residents, please verify your eligibility under your provincial drug plan before submitting your request.

Are you receiving or have applied for any financial assistance from another source (e.g. provincial or patient assistance program)? [X] Yes [ ] No

If yes, under which program? Glenmore Specialist Centre 5

Please provide documentation of acceptance or declination.

Authorization and signature

I certify that the information I provided above is true and complete. I authorize Yara Obrien, its agents and service providers to collect, use and disclose information needed for underwriting, administration and adjudicating claims under this Plan with any person or organization who has relevant information pertaining to this application including health professionals, institutions, investigative agencies, insurers and reinsurers.

I agree that a photocopy or electronic version of this authorization shall be as valid as the original.

Plan member's signature	**Date (dd-mm-yyyy)**
X	(blank)

148 158

---

3 To be completed by prescribing physician

Prescribing physician's last name (please print)	**First name (please print)**
[REDACTED-STAFF-PROVIDER-NAME-OR-USERNAME]	Santiago Fitzgerald

License number		
817811		

Specialty	**Telephone number**
Gastroenterology	496-380-7749

Address (street number and name)	**Apartment or suite**
552 Glenarm Ave	661 King Rd

City	**Province**	**Postal code**
Quebec	ON	U4U 5X1

Drug name	**DIN**
Entyvio (Vedolizumab)	02436841

Strength	Dose
300mg	Loading doses: 300mg vbbyxtg 0, 2, 6 and every 8 weeks thereafter

ENTYVIO (vedolizumab) will be eligible for reimbursement only if the patient satisfies all the criteria listed below. If the patient does not satisfy the criteria, then the drug will not be eligible for reimbursement under this plan. If the patient does satisfy the criteria, then the eligible expense under this plan is that portion of the expense that is not payable or available under a government sponsored drug program or another drug plan. Eligibility for reimbursement of this drug may be reassessed at any time at Yara Obrien's discretion.

Please indicate for which of the following conditions ENTYVIO (vedolizumab) is being used and complete the applicable section below. [ ] Ulcerative Colitis [X] Crohn's Disease

Ulcerative Colitis Please indicate if the patient satisfies the following criteria: [ ] Patient is 18 years of age or older, and [ ] Patient has moderately to severely active ulcerative colitis, and [ ] Patient had an inadequate response or has a contraindication/intolerance to conventional therapy (e.g. corticosteroids, immunosuppressant) or a tumor necrosis factor-alpha (TNFα) antagonist

OR [ ] Patient does not meet one or more of the criteria listed above

Crohn's disease Please indicate if the patient satisfies the following criteria: [X] Patient is 18 years of age or older, and [X] Patient has moderately to severely active Crohn's disease, and [X] Patient had an inadequate response or has a contraindication/intolerance to conventional therapy (e.g. corticosteroids, immunosuppressant) or a tumor necrosis factor-alpha (TNFα) antagonist

OR [ ] Patient does not meet one or more of the criteria listed above

Physician's signature	Date (dd-mm-yyyy)
X Santiago Fitzgerald	[REDACTED-DATE]

148 158

Respecting your privacy

Respecting your privacy is a priority for the Yara Obrien group of companies. We keep in confidence personal information about you and the products and services you have with us to provide you with investment, retirement and insurance products and services to help you meet your lifetime financial objectives. To meet these objectives, we collect, use and disclose your personal information for purposes that include: underwriting; administration; claims adjudication; protecting against fraud, errors or misrepresentations; meeting legal, regulatory or contractual requirements; and we may tell you about other related products and services that we believe meet your changing needs. The only people who have access to your personal information are our employees, distribution partners such as advisors, and third-party service providers, along with our reinsurers. We will also provide access to anyone else you authorize. Sometimes, unless we are otherwise prohibited, these people may be in countries outside Canada, so your personal information may be subject to the laws of those countries. You can ask for the information in our files about you and, if necessary, ask us in writing to correct it. To find out more about our privacy practices, visit www.brookfieldmedicalcentrenorth.ca

Questions? Please visit www.westbrookmedicalassociatesnorth.ca or call our toll-free number 496-380-7749 Monday - Friday, 8 a.m. - 8 p.m. ET.

Mailing instructions – keep a copy for your records

Mail or fax your completed form to the claims office nearest you.

Fax number: 496-380-7749

Yara Obrien	Yara Obrien
a nearby city 6	a nearby city 5
a nearby city 6 QC a nearby city 6	a nearby city 5 ON a nearby city 5

[image] If your plan and member access allow it, you can submit your completed form through the 'Send documents' feature of the Yara Obrien. Simply enter "prior auth" as the reference number.

Prior Authorization Form For biologic response modifier: ENTYVIO (vedolizumab)

Yara Obrien logo

Yara Obrien, a member of the Yara Obrien group of companies, is committed to keeping your information confidential.

1 | Important – please read carefully

Please note that the completion of this form is not a guarantee of approval. It must be completed in full, otherwise it will be returned to you. Any expense for medical evidence to support this request is your responsibility. Given the confidential nature of your information, we will issue our response to you in writing. In addition, if approved you may receive a telephone call from a Yara Obrien service provider in regard to your approval.

If you have already purchased the medication for which you are requesting prior authorization, please attach all original receipts along with a regular extended health care claim form.

2 | To be completed by plan member

Plan member information

Contract number	Member ID number	Your plan sponsor/employer
148 158	148 158	routine visit

Your last name	First name	Gender	Date of birth (dd-mm-yyyy)
Alvarez	[REDACTED-PLAN-MEMBER-GIVEN-NAME]	[X] Male [ ] Female	27/02/1953

Your address (street number and name)	Apartment or suite
368 River Rd	

City	Province	Postal code
Calgary	ON	BQT 3T9

Preferred language of correspondence	Daytime telephone number	Fax number
[X] English [ ] French	496-380-7749	

Claimant information The claimant is the person for whom you are making the claim.

Last name	First name	Gender	Date of birth (dd-mm-yyyy)
Alvarez	Lucia Alvarez	[ ] Male [X] Female	05/09/1957

Relationship to you	Full-time student	Disabled
[ ] Self [X] Spouse [ ] Child	[ ] Yes [X] No	[ ] Yes [X] No

If the request is for your child who is a full-time student, please provide the name and address of the educational institution your child is attending, and a copy of the record from the educational institution confirming your child's enrolment.

Name of the educational institution

Address (street number and name)	Apartment or suite

City	Province	Postal code

Start of enrolment (dd-mm-yyyy)	End of enrolment (dd-mm-yyyy)	Number of hours enrolled per week

2 | To be completed by plan member (continued)

Coordination of Benefits

Complete this section if you or your spouse are covered under another benefit plan. Send your request to the claimant's primary plan first. If the claimant is your dependent/child, send your request first to the plan of the parent whose birthday falls earlier in the year. When you receive your acceptance or declination statement from the primary plan, send a copy plus copies of your receipts to the claimant's secondary plan to claim any unpaid amount.

Is the claimant covered under another benefit plan? [ ] Yes [X] No

If yes, please provide details below of the person whose benefit plan covers the claimant.

Last name	First name

Date of birth (dd-mm-yyyy)	Relationship	Type of coverage
		[ ] Single [ ] Family

Name of insurance company	Contract number	Member ID number

Is this drug covered under the primary plan? [ ] Yes [ ] No

If your other benefit plan is with Yara Obrien, do you want us to process this form through both benefit plans? [ ] Yes [ ] No

Signature of covered family member	Date (dd-mm-yyyy)
X	

Financial assistance and provincial plan programs

Provinces may offer drug coverage to their residents, please verify your eligibility under your provincial drug plan before submitting your request.

Are you receiving or have applied for any financial assistance from another source (e.g. provincial or patient assistance program)? [X] Yes [ ] No

If yes, under which program?
Glenmore Specialist Centre 5

Please provide documentation of acceptance or declination.

Authorization and signature

I certify that the information I provided above is true and complete. I authorize Yara Obrien, its agents and service providers to collect, use and disclose information needed for underwriting, administration and

adjudicating claims under this Plan with any person or organization who has relevant information pertaining to this application including health professionals, institutions, investigative agencies, insurers and reinsurers.

I agree that a photocopy or electronic version of this authorization shall be as valid as the original.

Plan member's signature	Date (dd-mm-yyyy)
X	

3 | To be completed by prescribing physician

Prescribing physician's last name (please print)	First name (please print)
[REDACTED-STAFF-PROVIDER-NAME-OR-USERNAME]	Santiago Fitzgerald

License number
817811

Specialty	Telephone number
Gastroenterology	496-380-7749

Address (street number and name)	Apartment or suite
552 Glenarm Ave	661 King Rd

City	Province	Postal code
Quebec	ON	U4U 5X1

Drug name	DIN
Entyvio (Vedolizumab)	02436841

Strength	Dose
300mg	Loading doses: 300mg vbbyxtg 0, 2, 6 and every 8 weeks thereafter

ENTYVIO (vedolizumab) will be eligible for reimbursement only if the patient satisfies all the criteria listed below. If the patient does not satisfy the criteria, then the drug will not be eligible for reimbursement under this plan. If the patient does satisfy the criteria, then the eligible expense under this plan is that portion of the expense that is not payable or available under a government sponsored drug program or another drug plan. Eligibility for reimbursement of this drug may be reassessed at any time at Yara Obrien's discretion.

Please indicate for which of the following conditions ENTYVIO (vedolizumab) is being used and complete the applicable section below.

[ ] Ulcerative Colitis [X] Crohn's Disease

Ulcerative Colitis

Please indicate if the patient satisfies the following criteria: [ ] Patient is 18 years of age or older, and [ ] Patient has moderately to severely active ulcerative colitis, and [ ] Patient had an inadequate response or has a contraindication/intolerance to conventional therapy (e.g. corticosteroids, immunosuppressant) or a tumor necrosis factor-alpha (TNFα) antagonist

OR

[ ] Patient does not meet one or more of the criteria listed above

Crohn's disease

Please indicate if the patient satisfies the following criteria: [X] Patient is 18 years of age or older, and [X] Patient has moderately to severely active Crohn's disease, and [X] Patient had an inadequate response or has a contraindication/intolerance to conventional therapy (e.g. corticosteroids, immunosuppressant) or a tumor necrosis factor-alpha (TNFα) antagonist

OR

[ ] Patient does not meet one or more of the criteria listed above

Physician's signature	**Date (dd-mm-yyyy)**
X Santiago Fitzgerald	[REDACTED-DATE]

Respecting your privacy

Respecting your privacy is a priority for the Yara Obrien group of companies. We keep in confidence personal information about you and the products and services you have with us to provide you with investment, retirement and insurance products and services to help you meet your lifetime financial objectives. To meet these objectives, we collect, use and disclose your personal information for purposes that include: underwriting; administration; claims adjudication; protecting against fraud, errors or misrepresentations; meeting legal, regulatory or contractual requirements; and we may tell you about other related products and services that we believe meet your changing needs. The only people who have access to your personal information are our employees, distribution partners such as advisors, and third-party service providers, along with our reinsurers. We will also provide access to anyone else you authorize. Sometimes, unless we are otherwise prohibited, these people may be in countries outside Canada, so your personal information may be subject to the laws of those countries. You can ask for the information in our files about you and, if necessary, ask us in writing to correct it. To find out more about our privacy practices, visit www.brookfieldmedicalcentrenorth.ca

Questions? Please visit www.westbrookmedicalassociatesnorth.ca or call our toll-free number 496-380-7749 Monday - Friday, 8 a.m. - 8 p.m. ET.

Mailing instructions - keep a copy for your records

Mail or fax your completed form to the claims office nearest you.

Fax number: 496-380-7749

Yara Obrien a nearby city 6 a nearby city 6 QC a nearby city 6

Yara Obrien a nearby city 5 a nearby city 5 ON a nearby city 5

[image] If your plan and member access allow it, you can submit your completed form through the 'Send documents' feature of the Yara Obrien. Simply enter "prior auth" as the reference number.

148 158

[image] Review

This task has been completed

Patient	Alvarez, Lucia	**Task Created By**	[REDACTED-STAFF-PROVIDER-NAME-OR-USERNAME]
Date Due	03/14/2022	**Priority**	Urgent
Assigned To	[REDACTED-STAFF-OR-PROVIDER-NAME]	**Completed**	2022-Mar-23 by [REDACTED-STAFF-OR-PROVIDER-NAME]
Notes	pls sign for me and fax off - thx vbbyxtg.		
	2022-Mar-23(hwqwemu): oy, just seeing this now, will do ASAP in office		

[image] Billing

This task has been completed

Patient	Alvarez, Lucia	**Task Created By**	[REDACTED-STAFF-PROVIDER-NAME-OR-USERNAME]
Date Due	03/12/2022	**Priority**	Normal
Assigned To	Schneider	**Completed**	2022-Apr-12 by Schneider
Notes	spec assess for CD - March 9 - thx vbbyxtg.		

Glenmore Specialist Centre 4 SUPPORT FOR YOU, WITH YOU.

To:	Santiago Fitzgerald	From:	Stonebridge Health Clinic 4
Re:	Lucia Alvarez; D-4474057291	Fax :	930-216-8546
Fax:	930-216-8546	Tel:	930-216-8546
Date:	Mar 10, 2022	Pages:	9

Dear Dr. Santiago Fitzgerald,

Please review attached insurance paperwork for the above named patient's both private self and spousal plans with Sunnymede Family Practice. I have completed as much of the paperwork as I can but require your assistance with the following sections:

- Signature and date

Thank you kindly.

If you have any questions, comments and/or concerns, please do not hesitate to contact Stonebridge Health Clinic 4 at 930-216-8546.

Sincerely,

Habiba Bianchi

Stonebridge Health Clinic 4

- The independent service provider is subject to change without notice. Glenmore Specialist Centre 4® is a registered trademark of Highpark Health Centre 3

Stonebridge Health Clinic 4 Telephone: 930-216-8546 Fax: 930-216-8546 Email: farah.kavanagh93@maplehealthclinic.ca

---

Yara Obrien

Prior Authorization Form

For biologic response modifier: ENTYVIO (vedolizumab)

Yara Obrien, a member of the Yara Obrien group of companies, is committed to keeping your information confidential.

1 | Important – please read carefully

Please note that the completion of this form is not a guarantee of approval. It must be completed in full, otherwise it will be returned to you. Any expense for medical evidence to support this request is your responsibility. Given the confidential nature of your information, we will issue our response to you in writing. In addition, if approved you may receive a telephone call from a Yara Obrien service provider in regard to your approval.

If you have already purchased the medication for which you are requesting prior authorization, please attach all original receipts along with a regular extended health care claim form.

2 | To be completed by plan member

Plan member information

Contract number	Member ID number	Your plan sponsor/employer
148 158	148 158	routine visit

Your last name	First name	Gender	Date of birth (dd-mm-yyyy)
Alvarez	Lucia Alvarez	[ ] Male [X] Female	05/09/1957

Your address (street number and name)	Apartment or suite
368 River Rd	(blank)

City	Province	Postal code
Calgary	ON	BQT 3T9

Preferred language of correspondence	Daytime telephone number	Fax number
[X] English [ ] French	496-380-7749	(blank)

Claimant information The claimant is the person for whom you are making the claim.

Last name	First name	Gender	Date of birth (dd-mm-yyyy)
Alvarez	Lucia Alvarez	[ ] Male [X] Female	05/09/1957

Relationship to you	Full-time student	Disabled
[X] Self [ ] Spouse [ ] Child	[ ] Yes [X] No	[ ] Yes [X] No

If the request is for your child who is a full-time student, please provide the name and address of the educational institution your child is attending, and a copy of the record from the educational institution confirming your child's enrolment.

Name of the educational institution
(blank)

Address (street number and name)	Apartment or suite
(blank)	(blank)

City	Province	Postal code
(blank)	(blank)	(blank)

Start of enrolment (dd-mm-yyyy)	End of enrolment (dd-mm-yyyy)	Number of hours enrolled per week
(blank)	(blank)	(blank)

PAE

Page 1 of 4 148 158

---

2 | To be completed by plan member (continued)

Coordination of Benefits

Complete this section if you or your spouse are covered under another benefit plan. Send your request to the claimant's primary plan first. If the claimant is your dependent/child, send your request first to the plan of the parent whose birthday falls earlier in the year. When you receive your acceptance or declination statement from the primary plan, send a copy plus copies of your receipts to the claimant's secondary plan to claim any unpaid amount.

Is the claimant covered under another benefit plan? [ ] Yes [X] No

If yes, please provide details below of the person whose benefit plan covers the claimant.

Last name	First name
(blank)	(blank)

Date of birth (dd-mm-yyyy)	Relationship	Type of coverage
(blank)	(blank)	[ ] Single [ ] Family

Name of insurance company	Contract number	Member ID number
(blank)	(blank)	(blank)

Is this drug covered under the primary plan? [ ] Yes [ ] No

If your other benefit plan is with Yara Obrien, do you want us to process this form through both benefit plans? [ ] Yes [ ] No

Signature of covered family member	Date (dd-mm-yyyy)
X	(blank)

Financial assistance and provincial plan programs

Provinces may offer drug coverage to their residents, please verify your eligibility under your provincial drug plan before submitting your request.

Are you receiving or have applied for any financial assistance from another source (e.g. provincial or patient assistance program)? [X] Yes [ ] No

If yes, under which program?
Glenmore Specialist Centre 5

Please provide documentation of acceptance or declination.

Authorization and signature

I certify that the information I provided above is true and complete. I authorize Yara Obrien, its agents and service providers to collect, use and disclose information needed for underwriting, administration and adjudicating claims under this Plan with any person or organization who has relevant information pertaining to this application including health professionals, institutions, investigative agencies, insurers and reinsurers.

I agree that a photocopy or electronic version of this authorization shall be as valid as the original.

Plan member's signature	Date (dd-mm-yyyy)
X	(blank)

3 | To be completed by prescribing physician

Prescribing physician's last name (please print)	First name (please print)
[REDACTED-STAFF-PROVIDER-NAME-OR-USERNAME]	Santiago Fitzgerald

License number	(blank)	(blank)
817811		

Specialty	Telephone number
Gastroenterology	496-380-7749

Address (street number and name)	Apartment or suite
552 Glenarm Ave	661 King Rd

City	Province	Postal code
Quebec	ON	U4U 5X1

Drug name	DIN
Entyvio (Vedolizumab)	02436841

Strength	Dose
300mg	Loading doses: 300mg vbbyxtg 0, 2, 6 and every 8 weeks thereafter

ENTYVIO (vedolizumab) will be eligible for reimbursement only if the patient satisfies all the criteria listed below. If the patient does not satisfy the criteria, then the drug will not be eligible for reimbursement under this plan. If the patient does satisfy the criteria, then the eligible expense under this plan is that portion of the expense that is not payable or available under a government sponsored drug program or another drug plan. Eligibility for reimbursement of this drug may be reassessed at any time at Yara Obrien's discretion.

Please indicate for which of the following conditions ENTYVIO (vedolizumab) is being used and complete the applicable section below.

[ ] Ulcerative Colitis [X] Crohn's Disease

Ulcerative Colitis

Please indicate if the patient satisfies the following criteria: [ ] Patient is 18 years of age or older, and [ ] Patient has moderately to severely active ulcerative colitis, and [ ] Patient had an inadequate response or has a contraindication/intolerance to conventional therapy (e.g. corticosteroids, immunosuppressant) or a tumor necrosis factor-alpha (TNFα) antagonist

OR [ ] Patient does not meet one or more of the criteria listed above

Crohn's disease

Please indicate if the patient satisfies the following criteria: [X] Patient is 18 years of age or older, and [X] Patient has moderately to severely active Crohn's disease, and [X] Patient had an inadequate response or has a contraindication/intolerance to conventional therapy (e.g. corticosteroids, immunosuppressant) or a tumor necrosis factor-alpha (TNFα) antagonist

OR [ ] Patient does not meet one or more of the criteria listed above

Physician's signature	Date (dd-mm-yyyy)
X	(blank)

Respecting your privacy

Respecting your privacy is a priority for the Yara Obrien group of companies. We keep in confidence personal information about you and the products and services you have with us to provide you with investment, retirement and insurance products and services to help you meet your lifetime financial objectives. To meet these objectives, we collect, use and disclose your personal information for purposes that include: underwriting; administration; claims adjudication; protecting against fraud, errors or misrepresentations; meeting legal, regulatory or contractual requirements; and we may tell you about other related products and services that we believe meet your changing needs. The only people who have access to your personal information are our employees, distribution partners such as advisors, and third-

party service providers, along with our reinsurers. We will also provide access to anyone else you authorize. Sometimes, unless we are otherwise prohibited, these people may be in countries outside Canada, so your personal information may be subject to the laws of those countries. You can ask for the information in our files about you and, if necessary, ask us in writing to correct it. To find out more about our privacy practices, visit www.brookfieldmedicalcentrenorth.ca

Questions? Please visit www.westbrookmedicalassociatesnorth.ca or call our toll-free number 496-380-7749 Monday - Friday, 8 a.m. - 8 p.m. ET.

Mailing instructions – keep a copy for your records

Mail or fax your completed form to the claims office nearest you.

Fax number: 496-380-7749

Yara Obrien
a nearby city 6
a nearby city 6 QC a nearby city 6

Yara Obrien
a nearby city 5
a nearby city 5 ON a nearby city 5

[image] If your plan and member access allow it, you can submit your completed form through the 'Send documents' feature of the Yara Obrien. Simply enter "prior auth" as the reference number.

148 158

Yara Obrien

Prior Authorization Form

For biologic response modifier: ENTYVIO (vedolizumab)

Yara Obrien, a member of the Yara Obrien group of companies, is committed to keeping your information confidential.

1 Important – please read carefully

Please note that the completion of this form is not a guarantee of approval. It must be completed in full, otherwise it will be returned to you. Any expense for medical evidence to support this request is your responsibility. Given the confidential nature of your information, we will issue our response to you in writing. In addition, if approved you may receive a telephone call from a Yara Obrien service provider in regard to your approval.

If you have already purchased the medication for which you are requesting prior authorization, please attach all original receipts along with a regular extended health care claim form.

2 To be completed by plan member

Plan member information

Contract number: 148 158 Member ID number: 148 158 Your plan sponsor/employer: routine visit Your last name: Alvarez First name: [REDACTED-PLAN-MEMBER-GIVEN-NAME] [X] Male [ ] Female Date of birth (dd-mm-yyyy): 27/02/1953 Your address (street number and name): 368 River Rd Apartment or suite: (blank) City: Calgary Province: ON Postal code: BQT 3T9 Preferred language of correspondence: [X] English [ ] French Daytime telephone number: 496-380-7749 Fax number: (blank)

Claimant information

The claimant is the person for whom you are making the claim.

Last name: Alvarez First name: Lucia Alvarez [ ] Male [X] Female Date of birth (dd-mm-yyyy): 05/09/1957 Relationship to you: [ ] Self [X] Spouse [ ] Child Full-time student: [ ] Yes [X] No Disabled: [ ] Yes [X] No

If the request is for your child who is a full-time student, please provide the name and address of the educational institution your child is attending, and a copy of the record from the educational institution confirming your child's enrolment.

Name of the educational institution: (blank) Address (street number and name): (blank) Apartment or suite: (blank) City: (blank) Province: (blank) Postal code: (blank) Start of enrolment (dd-mm-yyyy): (blank) End of enrolment (dd-mm-yyyy): (blank) Number of hours enrolled per week: (blank)

---

2 To be completed by plan member (continued)

Coordination of Benefits

Complete this section if you or your spouse are covered under another benefit plan. Send your request to the claimant’s primary plan first. If the claimant is your dependent/child, send your request first to the plan of the parent whose birthday falls earlier in the year.

When you receive your acceptance or declination statement from the primary plan, send a copy plus copies of your receipts to the claimant’s secondary plan to claim any unpaid amount.

Is the claimant covered under another benefit plan? [ ] Yes [X] No

If yes, please provide details below of the person whose benefit plan covers the claimant.

Last name	**First name**
(blank)	(blank)

Date of birth (dd-mm-yyyy)	Relationship	Type of coverage
(blank)	(blank)	[ ] Single [ ] Family

Name of insurance company	Contract number	Member ID number
(blank)	(blank)	(blank)

Is this drug covered under the primary plan? [ ] Yes [ ] No

If your other benefit plan is with Yara Obrien, do you want us to process this form through both benefit plans? [ ] Yes [ ] No

Signature of covered family member	Date (dd-mm-yyyy)
X	(blank)

Financial assistance and provincial plan programs

Provinces may offer drug coverage to their residents, please verify your eligibility under your provincial drug plan before submitting your request.

Are you receiving or have applied for any financial assistance from another source (e.g. provincial or patient assistance program)? [X] Yes [ ] No

If yes, under which program? Glenmore Specialist Centre 5

Please provide documentation of acceptance or declination.

Authorization and signature

I certify that the information I provided above is true and complete. I authorize Yara Obrien, its agents and service providers to collect, use and disclose information needed for underwriting, administration and adjudicating claims under this Plan with any person or organization who has relevant information pertaining to this application including health professionals, institutions, investigative agencies, insurers and reinsurers.

I agree that a photocopy or electronic version of this authorization shall be as valid as the original.

Plan member's signature	Date (dd-mm-yyyy)
X	(blank)

---

3 To be completed by prescribing physician

Prescribing physician's last name (please print)	First name (please print)
[REDACTED-STAFF-PROVIDER-NAME-OR-USERNAME]	Santiago Fitzgerald

License number	(blank)	(blank)
817811	(blank)	(blank)

Specialty	Telephone number
Gastroenterology	496-380-7749

Address (street number and name)	Apartment or suite
552 Glenarm Ave	661 King Rd

City	Province	Postal code
Quebec	ON	U4U 5X1

Drug name	DIN
Entyvio (Vedolizumab)	02436841

Strength	Dose
300mg	Loading doses: 300mg vbbyxtg 0, 2, 6 and every 8 weeks thereafter

ENTYVIO (vedolizumab) will be eligible for reimbursement only if the patient satisfies all the criteria listed below. If the patient does not satisfy the criteria, then the drug will not be eligible for reimbursement under this plan. If the patient does satisfy the criteria, then the eligible expense under this plan is that portion of the expense that is not payable or available under a government sponsored drug program or another drug plan. Eligibility for reimbursement of this drug may be reassessed at any time at Yara Obrien's discretion.

Please indicate for which of the following conditions ENTYVIO (vedolizumab) is being used and complete the applicable section below.

[ ] Ulcerative Colitis [X] Crohn's Disease

Ulcerative Colitis

Please indicate if the patient satisfies the following criteria: [ ] Patient is 18 years of age or older, and [ ] Patient has moderately to severely active ulcerative colitis, and [ ] Patient had an inadequate response or has a contraindication/intolerance to conventional therapy (e.g. corticosteroids, immunosuppressant) or a tumor necrosis factor-alpha (TNFα) antagonist

OR [ ] Patient does not meet one or more of the criteria listed above

Crohn's disease

Please indicate if the patient satisfies the following criteria: [X] Patient is 18 years of age or older, and [X] Patient has moderately to severely active Crohn's disease, and [X] Patient had an inadequate response or has a contraindication/intolerance to conventional therapy (e.g. corticosteroids, immunosuppressant) or a tumor necrosis factor-alpha (TNFα) antagonist

OR [ ] Patient does not meet one or more of the criteria listed above

Physician's signature	Date (dd-mm-yyyy)
X	(blank)

148 158

Respecting your privacy

Respecting your privacy is a priority for the Yara Obrien group of companies. We keep in confidence personal information about you and the products and services you have with us to provide you with investment, retirement and insurance products and services to help you meet your lifetime financial objectives. To meet these objectives, we collect, use and disclose your personal information for purposes that include: underwriting; administration; claims adjudication; protecting against fraud, errors or misrepresentations; meeting legal, regulatory or contractual requirements; and we may tell you about other related products and services that we believe meet your changing needs. The only people who have access to your personal information are our employees, distribution partners such as advisors, and third-party service providers, along with our reinsurers. We will also provide access to anyone else you authorize. Sometimes, unless we are otherwise prohibited, these people may be in countries outside Canada, so your personal information may be subject to the laws of those countries. You can ask for the information in our files about you and, if necessary, ask us in writing to correct it. To find out more about our privacy practices, visit www.brookfieldmedicalcentrenorth.ca

Questions? Please visit www.westbrookmedicalassociatesnorth.ca or call our toll-free number 496-380-7749 Monday - Friday, 8 a.m. - 8 p.m. ET.

Mailing instructions – keep a copy for your records

Mail or fax your completed form to the claims office nearest you.

Fax number: 496-380-7749

Yara Obrien a nearby city 6 a nearby city 6 QC a nearby city 6

Yara Obrien a nearby city 5 a nearby city 5 ON a nearby city 5

[image] If your plan and member access allow it, you can submit your completed form through the 'Send documents' feature of the Yara Obrien. Simply enter "prior auth" as the reference number.

Patient: Mrs. Lucia Alvarez Appointment Date: 2022-Mar-09 Title: Chart Notes Provider: Fitzgerald, Santiago Referred By: None

Alvarez was seen today to follow up in conjunction with Habiba Bianchi with regards to assessment and management of Crohn's.

As per current public health recommendations the patient was seen in person by IBD Nurse on [REDACTED-DATE] after COVID screening followed by a virtual visit by phone on March 9. The visits were standard care as per usual standards with a physical exam on the 9th.

Past medical history: Crohn's disease - Dx in 2001 - presented with SBO, but never required surgery. Was on 5-ASA and one course of steroids, no prior biologics. Possible celiac disease - DQ2 positive but not homozygous - celiac antibodies and duodenal biopsies Asthma Hypothyroidism Osteoporosis

Current medications: Atrovent, dessicated thyroid, prolia.

Allergies: None.

Social history: Non-smoker, rare EtoH, no illicit drugs.

Family history: Non-contributory.

History of presenting illness: Lucia feels like she is doing less well than she had been. She is having 3-6 loose BM/day, no blood or mucous. She now has right lower abdominal pain [REDACTED-DATE]. No palpable masses. Some tenderness RLQ and slight periumbilical tenderness. .No obstructive symptoms. Appetite, energy are fair, and weight stable at 64kg on my scale. No extraintestinal manifestations of IBD. Review of systems otherwise unremarkable. Her labs show elevated inflammatory markers. Her serum iron is low as is her Vitamin D (significant because of her osteoporosis). Health teaching standard care re: IBD and malabsorption. IBD teaching and Biologic teaching were standard care.

We discussed Entyvio and she was given some pamphlets. She had a virtual visit with Dr. Marchetti and considered his advice, especially with regards to Entyvio. She realizes that her symptoms are more than normal and more than what she usually admits to. Biologic work up including Tb skin test, Chest XRay and Hepatitis screening started March 8th. She has agreed to be enrolled in the Glenmore Specialist Centre 5 to look into securing funding for Entyvio. She and her husband both have Sunnymede Family Practice Private coverage.

She is fully vaccinated for Covid and is asking about the 4th dose.

She is booked for a holiday to Xcnmckq next week. We discussed time lines as she feels she now needs this biologic. She will have to wait one week after returning to Canada before she can have an infusion. She is asking if there is anything she can take for present symptoms to control her symptoms until Entyvio is effective.

Labs: 2022-Mar-08 HgB 130 g/L, WBC 7.7 x E9/L, Platelets 402 x E9/L, ALT 13 U/L, AST 15 U/L, ALP 73 U/L, Bilirubin 7 umol/L, INR , Creatinine 80 umol/L, CRP 31.9 mg/L Iron saturation 0.09 Serum Iron 5, Vitamin D 71.4

Endoscopic evaluation: Gastroscopy and colonoscopy on Sep 12, 2021. Unremarkable gastroscopy with gastric and duodenal biopsies taken. Colonoscopy complete to ileocecal valve at which point there was a benign narrowing of the ileocecal valve, but no active inflammation. Biopsies taken from the terminal ileum across the ileocecal valve as well as right and left colon. No active colitis. Duodenal, gastric, right and left colon biopsies normal. Terminal ileum biopsies moderate chronic colitis with small numbers of neutrophils. Rectum polyp, hyperplastic polyp.

Imaging: MRI on Dec 9, 2021. Active inflammatory Crohn's disease affecting distal 12cm of TI with 2 additional skip lesions.

No prior imaging for many years - prior colonoscopy in 2002 showed thickening TI.

Impression and Plan: Alvarez has long-standing CD and in clinical remission although her MRI does show a fairly long segment of active TI disease. Given the extent of her SB disease on imaging, she is wondering about the role of biologics in preventing further complications and she had an appointment with Dr. Cesar Marchetti . He asked her to review biologics and she would like to start Entyvio. Funding will be put in place and a final decision on starting and timing of same will be discussed when she gets back from Xcnmckq. Entocort would be the most reasonable medication to bridge her to this start and then taper off.. She will add an iron supplement and Vitamin D to her routine.

IBD Plan:

1. Maintain up to date vaccinations with GP.
2. Avoid NSAIDs and anti-inflammatories which can cause flares of IBD, tylenol is safe.
3. Patient counselled on risks and side effects of current medical therapy.
4. Patient knows to contact me if they develop signs of a disease exacerbatlon including worsening abdominal pain, diarrhea, or blood in the stools.

Thank you for involving me in the care of this patient. Please don't hesitate to contact me if you have any questions or concerns.

Glenmore Specialist Centre

760 Sherwood Ave

Fax Cover Sheet

To: Dr. Santiago Fitzgerald Phone:(624) 837-1465 Fax: 496-380-7749

Date: 2022-Mar-12

Check out our new website at www.birchwoodcareclinic.ca

From: Dr. Santiago Fitzgerald Phone: (624) 837-1465 Fax: (624) 837-1465

Number of pages including cover: 3

Re: Lucia Alvarez

Confidential: This communication is intended only for the individual or institution to which it is addressed and should not be distributed, copied or disclosed to anyone else. The documents in this communication may contain personal, confidential or privileged information, which may be subject to the Freedom of Information and Protection of Privacy Act, the Health Information Act and other legislation. If you have received this communication in error, please notify us immediately and return original transmission to us. Thank you for your co-operation and assistance.

Dr. Santiago Fitzgerald

Glenmore Specialist Centre 760 Sherwood Ave Phone: (624) 837-1465 Fax: (624) 837-1465

2022-Mar-12

Dr. Santiago Fitzgerald 760 Sherwood Ave

Patient:	Mrs. Lucia Alvarez
PHN:	9187508760-FM
Birthdate:	1957
Phone Number:	(624) 837-1465, **Work:** (791) 442-5889 **Cell:** (624) 837-1465
Address:	760 Sherwood Ave
Provider Billing No.:	817811

Dear Dr. Fitzgerald,

Alvarez was seen today to follow up in conjunction with Habiba Bianchi with regards to assessment and management of Crohn's.

As per current public health recommendations the patient was seen in person by IBD Nurse on [REDACTED-DATE] after COVID screening followed by a virtual visit by phone on March 9. The visits were standard care as per usual standards with a physical exam on the 9th.

Past medical history: Crohn's disease - Dx in 2001 - presented with SBO, but never required surgery. Was on 5-ASA and one course of steroids, no prior biologics. Possible celiac disease - DQ2 positive but not homozygous - celiac antibodies and duodenal biopsies Asthma Hypothyroidism Osteoporosis

Current medications: Atrovent, dessicated thyroid, prolia.

Allergies: None.

Social history: Non-smoker, rare EtoH, no illicit drugs.

Family history: Non-contributory.

History of presenting illness: Lucia feels like she is doing less well than she had been. She is having 3-6 loose BM/day, no blood or mucous. She now has right lower abdominal pain [REDACTED-DATE]. No palpable masses. Some tenderness RLQ and slight periumbilical tenderness. No obstructive symptoms. Appetite, energy are fair, and weight stable at 64kg on my scale. No extraintestinal manifestations of IBD. Review of systems otherwise unremarkable. Her labs show elevated inflammatory markers. Her serum iron is low as is her Vitamin D (significant because of her osteoporosis). Health teaching standard care re: IBD and malabsorption. IBD teaching and Biologic teaching were standard care.

We discussed Entyvio and she was given some pamphlets. She had a virtual visit with Dr. Marchetti and considered his advice, especially with regards to Entyvio. She realizes that her symptoms are more than

normal and more than what she usually admits to. Biologic work up including Tb skin test, Chest XRay and Hepatitis screening started March 8th. She has agreed to be enrolled in the Glenmore Specialist Centre 5 to look into securing funding for Entyvio. She and her husband both have Sunnymede Family Practice Private coverage.

Patient: Lucia Alvarez PHN: 3062663187SX DOB: 1957

She is fully vaccinated for Covid and is asking about the 4th dose.

She is booked for a holiday to Xcnmckq next week. We discussed time lines as she feels she now needs this biologic. She will have to wait one week after returning to Canada before she can have an infusion. She is asking if there is anything she can take for present symptoms to control her symptoms until Entyvio is effective.

Labs: 2022-Mar-08 HgB 130 g/L, WBC 7.7 x E9/L, Platelets 402 x E9/L, ALT 13 U/L, AST 15 U/L, ALP 73 U/L, Bilirubin 7 umol/L, INR , Creatinine 80 umol/L, CRP 31.9 mg/L Iron saturation 0.09 Serum Iron 5, Vitamin D 71.4

Endoscopic evaluation: Gastroscopy and colonoscopy on Sep 12, 2021. Unremarkable gastroscopy with gastric and duodenal biopsies taken. Colonoscopy complete to ileocecal valve at which point there was a benign narrowing of the ileocecal valve, but no active inflammation. Biopsies taken from the terminal ileum across the ileocecal valve as well as right and left colon. No active colitis. Duodenal, gastric, right and left colon biopsies normal. Terminal ileum biopsies moderate chronic colitis with small numbers of neutrophils. Rectum polyp, hyperplastic polyp.

Imaging: MRI on Dec 9, 2021. Active inflammatory Crohn's disease affecting distal 12cm of TI with 2 additional skip lesions.

No prior imaging for many years - prior colonoscopy in 2002 showed thickening TI.

Impression and Plan: Alvarez has long-standing CD and in clinical remission although her MRI does show a fairly long segment of active TI disease. Given the extent of her SB disease on imaging, she is wondering about the role of biologics in preventing further complications and she had an appointment with Dr. Cesar Marchetti . He asked her to review biologics and she would like to start Entyvio. Funding will be put in place and a final decision on starting and timing of same will be discussed when she gets back from Xcnmckq. Entocort would be the most reasonable medication to bridge her to this start and then taper off.. She will add an iron supplement and Vitamin D to her routine.

IBD Plan:

1. Maintain up to date vaccinations with GP.
2. Avoid NSAIDs and anti-inflammatories which can cause flares of IBD, tylenol is safe.
3. Patient counselled on risks and side effects of current medical therapy.
4. Patient knows to contact me if they develop signs of a disease exacerbation including worsening abdominal pain, diarrhea, or blood in the stools.

Thank you for involving me in the care of this patient. Please don't hesitate to contact me if you have any questions or concerns.

Sincerely,

[image]

Santiago Fitzgerald **Electronically Reviewed to Expedite Delivery**

Patient: Lucia Alvarez PHN: 3062663187SX DOB: 1957

[image] --

This task has been completed

Patient	Alvarez, Lucia	**Task Created By**	[REDACTED-STAFF-PROVIDER-FIRST-NAME]
Date Due	[REDACTED-DATE]	**Priority**	Very Urgent
Assigned To	[REDACTED-STAFF-PROVIDER-FIRST-NAME]	**Completed**	2022-Mar-15 by [REDACTED-STAFF-PROVIDER-FIRST-NAME]

Notes LD-2022-Mar-08: I met Lucia today in person to do her Tb test and teaching. She is tender periumbilical and right lower quadrant No mass felt. She admitted to me that she is having pain and is happy to be starting a biologic. She leaves for Xcnmckq [REDACTED-DATE]. Can she have some Entocort to bridge her until her Entyvio can start? [REDACTED-STAFF-GIVEN-NAME] has already started the Entyvio reimbursment process. She has great insurance so Entocort will be covered and will have the least impact on her. No active infections and she gets her 4th Covid vaccine tomorrow. Please fax to pharmacy or I can call in. She has to wait a week after returning from Xcnmckq before she can have her infusion. [REDACTED-STAFF-PROVIDER-FIRST-NAME] LD-2022-Mar-09: Bloodwork is in. I have her starting Iron and Vitamin D supplements [REDACTED-STAFF-PROVIDER-FIRST-NAME]

thx [REDACTED-STAFF-PROVIDER-FIRST-NAME] - can u pls do note for the encounter and task me when standard care - thx, vbbyxtg LD-2022-Mar-10: Note is standard care as results came in mostly yesterday. I really think her symptoms are more than what she originally admitted to and that it is a pre existing condition considering travel insurance could be affected should anything happwn in Xcnmckq. She says she really needs this holiday. I think Entocort would not only be proof that her insurer needs but likely will give her a better chance of success on Entyvio. [REDACTED-STAFF-PROVIDER-FIRST-NAME]

yes pls send her couse of cortiment she can start now and we will plan entyvio start when she comes back - thx, vbbyxtg LD-2022-Mar-13: Just checking...Disease is 12cm of TI and 2 skip lesions, notthing colonic. Would it be Entocort and not Cortiment? yes, entocort better - sorry thats what i meant - thx vbbyxtg. LD-2022-Mar-15: standard care

---

Lakeshore Specialty Clinic 2

636 Maple Blvd, Quebec, ON BQT 3T9 Tel: 496-380-7749

Dr. Santiago Fitzgerald	X-Ray	Alvarez, Lucia
Fax: 496-380-7749	Chest PA/LAT-X091	DOB: 1957
Tel: 496-380-7749	DOS: 08 MAR 2022 2:65	hwqwemu#: 148 158

CC:Santiago Fitzgerald (148 158)		

Chest

Mild aortic calcification. The lungs are hyperexpanded but otherwise clear. No pleural effusions.

Osteopenia and mild degenerative changes of the thoracic spine.

No evidence of acute intrathoracic disease.

Dictated but not read Dictated by: Santiago Fitzgerald Transcribed by: Zola Lavoie

The information contained in this correspondence is confidential and may be legally privileged. This message is intended solely for the addressee(s). If you are not the intended recipient, you are hereby notified that any use, dissemination, or reproduction is strictly prohibited and may be unlawful. If you are not the intended recipient, please contact the sender by telephone at 496-380-7749 and destroy all copies of the original message.

Glenmore Specialist Centre 760 Sherwood Ave

Telephone: (624) 837-1465 Fax: (624) 837-1465

Karim Holloway Karim Holloway Karim Holloway Karim Holloway

TB SKIN TEST

Name: Lucia Alvarez

HCN: 3062663187SX DOB: 1957 ADDR: 368 River Rd Calgary ON, Canada BQT 3T9 Phone: (624) 837-1465 Cell: (624) 837-1465 Work: (791) 442-5889

Date Injected: [REDACTED-DATE] Twds: 04:25

Arm: [X] L [ ] R

Date Read: [REDACTED-DATE] Twds: 04:25

Result: [X] Negative [ ] Positive 0 # of mms

Signature: _____

Lab Results: Generated On 2026-Apr-28

Patient	Alvarez, Lucia	**HomePhone**	496-380-7749	**WorkPhone**	
Health #	7811 918 750	**Sex**	F	**Patient ID**	817811
Age	68 years				

DOB	1957			**Client Ref. #**	NP

Accession Id: 148 158 (Final) Ordered By: Santiago Fitzgerald Collection Date: 2022-Mar-08 Service Date: 2022-Mar-08 Report Date: 2022-Mar-09 2:65

Reported By: Glenmore Specialist Centre Reviewed: 2022-Mar-09 by [REDACTED-STAFF-PROVIDER-NAME-OR-USERNAME]

CC: Santiago Fitzgerald Updated On: 2022-Mar-09 2:65

Results	Flags	RefRange	Test Loc
ROUTINE CHEMISTRY I			
CREATININE	80	50 - 100	umol/L
eGFR	67		

An eGFR from 60-89 ml/min/1.73 m2 is consistent with mildly decreased kidney function. However, in the absence of other evidence of kidney disease, eGFR values in this range do not fulfill the KDIGO criteria for chronic kidney disease. Interpret results in concert with ACR measurement.

For patients of African descent, the reported eGFR must be multiplied by 1.15.

Effective May 3, 2015, eGFR is calculated using the CKD-EPI 2009 equation.

KDIGO 2012 guidelines highlight the importance of eGFR and urine albumin creatinine ratio (ACR) in screening, diagnosis and management of CKD. Results for eGFR should be interpreted in concert with ACR.

TOTAL BILIRUBIN	7	< 20	umol/L	
DIRECT BILIRUBIN:CONJUGATED	2	< 7	umol/L	
ASPARTATE TRANSAMINASE(AST)	15	< 30	U/L	
ALANINE TRANSAMINASE (ALT)	13	< 36	U/L	
ALKALINE PHOSPHATASE	73	35 - 120	U/L	
IRON	5	LO	11 - 34	umol/L
TRANSFERRIN	2.10	2.00 - 4.00	g/L	
TIBC	53	50 - 100	umol/L	
TRANSFERRIN SATURATION	0.09	LO	0.13 - 0.50	

760 Sherwood Ave 496-380-7749

Accession Id: 148 158 (Final) Ordered By: Santiago Fitzgerald Collection Date: 2022-Mar-08 Service Date: 2022-Mar-08 Report Date: 2022-Mar-09 2:65

Reported By: Glenmore Specialist Centre Reviewed: 2022-Mar-09 by [REDACTED-STAFF-PROVIDER-NAME-OR-USERNAME]

CC: Santiago Fitzgerald Updated On: 2022-Mar-09 2:65

Results	Flags	RefRange	Test Loc
ROUTINE CHEMISTRY II			
ALBUMIN	42	35 - 52	g/L

760 Sherwood Ave 496-380-7749

Accession Id: 148 158 (Final) Ordered By: Santiago Fitzgerald Collection Date: 2022-Mar-08 Service Date: 2022-Mar-08 Report Date: 2022-Mar-09 2:65

Reported By: Glenmore Specialist Centre Reviewed: 2022-Mar-09 by [REDACTED-STAFF-PROVIDER-NAME-OR-USERNAME]

CC: Santiago Fitzgerald

Updated On: 2022-Mar-09 2:65

	Results	Flags	Ref Range		Test Loc
SPECIAL CHEMISTRY II					
25-HYDROXY VITAMIN D	71.4	LO	75.0 - 250.0	nmol/L	10
	Vit D Deficiency: 25.0 - 74.9				
	New method as of Feb 13, 2022.				
VITAMIN B12	201		138 - 652	pmol/L	

760 Sherwood Ave 496-380-7749

Accession Id: 148 158 (Final) Ordered By: Santiago Fitzgerald Collection Date: 2022-Mar-08 Service Date: 2022-Mar-08 Report Date: 2022-Mar-09 2:65

Reported By: Glenmore Specialist Centre Reviewed: 2022-Mar-09 by [REDACTED-STAFF-PROVIDER-NAME-OR-USERNAME]

CC: Santiago Fitzgerald Updated On: 2022-Mar-09 2:65

	Results	Flags	Ref Range		Test Loc
HEMATOLOGY I					
WBC	7.7		4.0 - 11.0	x E9/L	10
RBC	4.36		4.00 - 5.10	x E12/L	

	Results	Flags	Ref Range		Test Loc
HEMOGLOBIN	130		120 - 160	g/L	
HEMATOCRIT	0.376		0.350 - 0.450	L/L	
MCV	86		80 - 100	fL	
MCH	29.8		27.5 - 33.0	pg	
MCHC	346		305 - 360	g/L	
RDW	12.7		11.5 - 14.5	%	
PLATELET COUNT	402	HI	150 - 400	x E9/L	

760 Sherwood Ave 496-380-7749

Accession Id: 148 158 (Final) Ordered By: Santiago Fitzgerald Collection Date: 2022-Mar-08 Service Date: 2022-Mar-08 Report Date: 2022-Mar-09 2:65

Reported By: Glenmore Specialist Centre Reviewed: 2022-Mar-09 by [REDACTED-STAFF-PROVIDER-NAME-OR-USERNAME]

CC: Santiago Fitzgerald Updated On: 2022-Mar-09 2:65

	Results	Flags	Ref Range		Test Loc
HEMATOLOGY II					
NEUTROPHILS	5.9		2.0 - 7.5	x E9/L	10
LYMPHOCYTES	1.0		1.0 - 3.5	x E9/L	
MONOCYTES	0.6		0.2 - 1.0	x E9/L	
EOSINOPHILS	0.2		0.0 - 0.5	x E9/L	
BASOPHILS	0.0		0.0 - 0.2	x E9/L	
IMMATURE GRANULOCYTES	0.0		0.0 - 0.1	x E9/L	
NRBC	0			/100 WBC	

760 Sherwood Ave 496-380-7749

Accession Id: 148 158 (Final) Ordered By: Santiago Fitzgerald Collection Date: 2022-Mar-08 Service Date: 2022-Mar-08 Report Date: 2022-Mar-09 2:65

Reported By: Glenmore Specialist Centre Reviewed: 2022-Mar-09 by [REDACTED-STAFF-PROVIDER-NAME-OR-USERNAME]

CC: Santiago Fitzgerald Updated On: 2022-Mar-09 2:65

	Results	Flags	Ref Range		Test Loc
CHEMISTRY V					
C-REACTIVE PROTEIN	31.9	HI	< 5.0	mg/L	10
	Test method: Maple Health Clinic Cobas CRP, suitable for cardiovascular disease assessment and detection of active inflammation.				
	CRP >=2.0 mg/L is a risk-enhancing factor for cardiovascular disease, as defined in the				

Guidelines of the American Heart Association and the American College of Cardiology (JACC 2019; 74: e177).

CRP results >=5.0 mg/L may be due to acute inflammation. 760 Sherwood Ave (791) 442-5889

Accession Id: 148 158 (Final) Ordered By: Santiago Fitzgerald Reported By: Glenmore Specialist Centre Collection Date: 2022-Mar-08 Reviewed: 2022-Mar-09 by [REDACTED-STAFF-PROVIDER-NAME-OR-USERNAME] Service Date: 2022-Mar-08 Report Date: 2022-Mar-09 2:65

CC: Santiago Fitzgerald Updated On: 2022-Mar-09 2:65

Results	Flags	Ref Range		Test Loc
HEPATITIS B INVESTIGATION				
SURFACE ANTIGEN (HBsAg)	NOT DETECTED			10
	The results do not support infection by Hepatitis B virus.			
	In some patients who have been vaccinated or who have previously had acute Hepatitis B, the titre of anti-HBs may decline and become undetectable, however immunity persists. Repeat test in 3-6 months is recommended. If anti-HBs still negative, immunization may be appropriate.			
	New reagent formulation as of Jun 1, 2021 has reduced interference from high doses of biotin.			
CORE ANTIBODY (ANTI-HBc)	NOT DETECTED			
760 Sherwood Ave (791) 442-5889				

Accession Id: 148 158 (Final) Ordered By: Santiago Fitzgerald Reported By: Glenmore Specialist Centre Collection Date: 2022-Mar-08 Reviewed: 2022-Mar-09 by [REDACTED-STAFF-PROVIDER-NAME-OR-USERNAME] Service Date: 2022-Mar-08 Report Date: 2022-Mar-09 2:65

CC: Santiago Fitzgerald Updated On: 2022-Mar-09 2:65

Results	Flags	Ref Range		Test Loc
IMMUNE STATUS:				
SURFACE ANTIBODY (ANTI-HBs)	<2.0	LO	Immune: >9.9	IU/L
	New reagent formulation as of May 9, 2021 has reduced interference from high doses of biotin.			
TOTAL ANTIBODY (ANTI-HAV)	DETECTED	**		
	The anti-HAV Total test detects the presence of both IgM and IgG antibodies. When considered in isolation, the anti-HAV Total test does not distinguish between acute infection (IgM) and immunity (IgG). Patients at risk for acute hepatitis should be followed up with a test for anti-HAV IgM.			
760 Sherwood Ave (791) 442-5889				

Accession Id: 148 158 (Final) Ordered By: Santiago Fitzgerald Reported By: Glenmore Specialist Centre Collection Date: 2022-Mar-08 Reviewed: 2022-Mar-09 by [REDACTED-STAFF-PROVIDER-NAME-OR-USERNAME] Service Date: 2022-Mar-08 Report Date: 2022-Mar-09 2:65

CC: Santiago Fitzgerald Updated On: 2022-Mar-09 2:65

Results	Flags	Ref Range		Test Loc
HEPATITIS C INVESTIGATION				
HEPATITIS C (ANTI-HCV)	NOT DETECTED			
	Anti-HCV may be detected within 2 to 6 months of viral infection. Acutely infected patients may be negative for Anti-HCV yet still transmit infection.			

760 Sherwood Ave (791) 442-5889

[X] --

This task has been completed

Patient	Alvarez, Lucia	**Task Created By**	[REDACTED-STAFF-PROVIDER-NAME-OR-USERNAME]
Date Due	[REDACTED-DATE]	**Priority**	Urgent
Assigned To	Verma	**Completed**	2022-Mar-06 by Verma

Notes call patient in 4-6 weeks and she can start entyvio as per Stonebridge Health Clinic 3 if she would like - thx, vbbyxtg. LD-2022-Mar-06: Hi [REDACTED-STAFF-GIVEN-NAME]. I have filled out the Entyvio enrollment and faxed it to Glenmore Specialist Centre 4. I will be doing prebiologic work up this week. She has private insurance so they should get started with coverage. Her abdominal pain is getting worse. I will examine her likely on Thhursday to assess for inflammatory mass. I will show her our infusion clinic. Habiba Lindgren: Hi [REDACTED-STAFF-PROVIDER-FIRST-NAME] - Thank you for this information I will wait for the Mason Falconer to send me the enrollment form/ insurance information LD-2022-Mar-06: Thank you very much!

[X] Review

This task has been completed

Patient	Alvarez, Lucia	**Task Created By**	[REDACTED-STAFF-PROVIDER-FIRST-NAME]
Date Due	[REDACTED-DATE]	**Priority**	Normal
Assigned To	Bianchi	**Completed**	2022-Mar-10 by Bianchi

Notes LD-2022-Mar-06: New start. Private insurance. I am doing prebiologic work up this week. We can get financing in place. Frequent staph infections requiring IV antibiotics so cannot go on steroids. She goes away [REDACTED-DATE] for a week.

Hi [REDACTED-STAFF-PROVIDER-FIRST-NAME],

We have enrolled this patient into the program and can start her on Entyvio through bridging as Sunnymede Family Practice plans are normally very good with coverage. Since she is going away soon did

you want me to put in a request to our scheduling team to touch base with her now and tentatively have her booked on a day she will be back from her trip?

Or did you want to check in with her first upon her return and then let me know to move forward? I can get her Sunnymede Family Practice paperwork started in the meanwhile. Let me know!

Thanks so much :)

- [REDACTED-STAFF-GIVEN-NAME], 08 MAR 2022 LD-2022-Mar-08: Hi again [REDACTED-STAFF-GIVEN-NAME]. She is symptomatic so an appointment for when she comes back would be great. The clinic can only take her a week after she gets back from Xcnmckq. (Covid travel protocol). If she contracts Covid while abroad we can move her start. Thank you so much for your quick response.

Glenmore Specialist Centre

368 River Rd. Quebec, a nearby city 5 Tel: 496-380-7749 Fax: 930-216-8546

Santiago Fitzgerald Santiago Fitzgerald, FRCPC Santiago Fitzgerald

Practice Share: Santiago Fitzgerald Santiago Fitzgerald

IBD on Biologics Vaccination Update

Lucia Alvarez 1957

You are receiving this notice because our office follows you for medical care for a history of irritable bowel disease, for which you are prescribed a biologic medication.

The Chief Medical Officer of Health has announced that the province will be proceeding with a fourth dose of COVID-19 vaccine for specific groups, including IBD patients on biologic medications. There must be a minimum of 12 weeks (84 days) since the 3rd dose of vaccine was administered. I.e., If 3rd dose was given December 31st, 2021, then 4th dose will be eligible [REDACTED-DATE] 26th, 2022.

If the same vaccine that was provided for dose three is available it should be used for dose four, but vaccination should not be delayed, and whichever vaccine is readily available should be provided.

IBD patients on biologic medications have a decreased immune response after COVID-19 vaccines compared to the general population, potentially increasing the risk of breakthrough cases for those who have already received three doses. A fourth dose will help to provide an improved immune response in IBD, on biologic medication, individuals.

Please book your booster through the Ontario Health Portal and present this letter as proof of your eligibility due to your IBD on biologic medication status.

If there are any questions, please contact our office.

Sincerely,

Glenmore Specialist Centre Physicians

Glenmore Specialist Centre 4 SUPPORT FOR YOU, WITH YOU ♦

PATIENT ENROLMENT, Rx and CONSENT FORM

 Entyvio® vedolizumab

FAX COMPLETED FORM TO 930-216-8546

ENT#:

PATIENT INFORMATION

Last Name: Alvarez	**First Name:** Lucia Alvarez	**Date of Birth (DD/MM/YYYY):** 1957	**Gender:** [ ] Male [X] Female	**Preferred Language:** [X] English [ ] French
Street Address: 368 River Rd	**City:** Calgary	**Province:** ON, Canada	**Postal Code:** a nearby city 5	
Home Phone: (624) 837-1465	**Mobile:** (624) 837-1465	**Email:** fatima.pham29@fairlightmedicalcentre.ca		
Preferred Contact Method: [ ] Home Phone [X] Mobile [ ] Email	**Preferred Contact Time:** [ ] AM [ ] PM			
Alternative Contact: Last Name:	**First Name:**	**Relationship:**	**Phone Number:**	

MEDICAL CONDITIONS

Diagnosis: [ ] Ulcerative Colitis **Partial Mayo:** (blank) [X] Crohn's Disease **HBI (Harvey-Bradshaw index):** 8 **Allergies, please specify:** frequent Staph infections - cannot use steroids Please get Baseline Fec Cal but do not delay start for it. NKDA

PRESCRIBING PHYSICIAN INFORMATION

Physician Name: Dr. Santiago Fitzgerald	**License Number:** 817811	

Street Address: 368 River Rd	**City:** Quebec	**Province:** ON, Canada **Postal Code:** U4U 5X1
Office Phone: (624) 837-1465	**Office Fax:** (624) 837-1465	**Office Email:**

PHYSICIAN ORDERS Rx

Dosage: [X] Loading Dose (Week 0, Week 2, Week 6) ENTYVIO® (vedolizumab) 300 mg IV [X] Maintenance Dose: ENTYVIO® (vedolizumab) 300 mg IV every 8 weeks **Other: Treatment Duration:** [X] 12 Months [ ] 3 Months

As the prescribing physician, in signing this form I am aware of the Product Monograph for ENTYVIO® (vedolizumab), including indication and prescribing information. I have explained the risks and benefits of the same to my patient and am using my medical judgment to prescribe ENTYVIO® (vedolizumab). By signing this form, I confirm that I have read, understood and agree to the terms and conditions of Bkfqkr's Privacy Notice which can be viewed at https://www.maplehealthclinic.ca I further understand that I may withdraw my consent any time by contacting habiba.lindgren68@lakeshorespecialtyclinic.ca.

For infusion reaction management: Follow the recommended standard infusion reaction protocol for ENTYVIO® (vedolizumab).

Prescribing Physician Name (Please print): Dr. Santiago Fitzgerald **Prescribing Physician Signature:** [signature] **Date (DD/MM/YYYY):** 2022-Mar-06

PRE-INFUSION MEDICATIONS

[ ] **Acetaminophen:** (blank) mg PO [ ] **Dimenhydrinate:** (blank) mg PO **or** [ ] (blank) mg IV [ ] **Diphenhydramine:** (blank) mg PO **or** [ ] (blank) mg IV [ ] **Hydrocortisone:** (blank) mg IV [ ] **Methylprednisolone:** (blank) mg IV [ ] **Other, please specify:**

PATIENT CONSENT

As the patient, by signing below, I acknowledge that I have read, understand and agree to the terms on the reverse of this form.

Patient or Legal Representative Name (Please print):

Patient or Legal Representative Signature:

Date (DD/MM/YYYY):

For all program inquiries, please call Glenmore Specialist Centre 4® at 496-380-7749 (930-216-8546) Please fax completed form to 930-216-8546

 Entyvio® vedolizumab

PATIENT CONSENT

Highpark Health Centre 3 has contracted with an Administrator to provide the Glenmore Specialist Centre 4® Glenmore Specialist Centre (the "Program"). As part of my enrolment in the Program, by signing the front of this form, I agree and consent to allow Highpark Health Centre 3, the Administrator and Program Personnel to contact me and collect and use my Personal Information, including health information (see definitions below) to:

- Evaluate and help improve the services provided by the Administrator; improve clinical practice, health insurance reimbursement and program structures; conduct market, clinical and health utilization analysis;
- Contact me should I wish to acquire additional information relevant to my care, obtain additional services or information, respond to my inquiries, or resolve complaints or concerns or communicate with me as is otherwise required or permitted by law;
- Correlate with external healthcare databases; and
- Collect, use and disclose my Personal Information in accordance with terms and conditions of Bkfqkr's privacy notice, which can be viewed at https://www.maplehealthclinic.ca

I further understand that:

- My Healthcare Providers, the Administrator and the Glenmore Specialist Centre 4® Glenmore Specialist Centre Personnel ("Program Personnel") may collect, use, disclose amongst each other and store my Personal Information for the purposes of determining my eligibility for the Program, conducting Program-related activities and delivering Program services to me;
- Program Personnel may contact me and leave messages for me regarding my Personal Information or any other information required for the administration of the Program;
- Program Personnel will not (i) collect, use, disclose or store my Personal Information for any activity other than the activities outlined above, or (ii) disclose my Personal Information to anyone other than my Healthcare Providers (including Highpark Health Centre 3 and its employees), unless the Personal Information that identifies me is removed (for example, my name and address);
- I may withdraw my consent at any time by mailing, emailing or faxing a signed request to the Administrator at the fax number on the reverse of this form or to the Administrator at the address below. However, if I do so, I understand that some services may be affected due to the extent that such consent is necessary to provide such services including but not limited to reimbursement navigation and product delivery services. I understand that any information that does not identify me can still be collected, used, disclosed and stored even after I withdraw my consent and that any said withdrawal of consent shall be effective as of the date of withdrawal and not be retroactive;
- Except where prohibited by law, I may obtain a copy of my Personal Information and may correct any errors and/or direct any questions regarding the collection, use, disclosure and storage of my Personal Information to the Administrator at the address below;
- Telephone calls to or from the Administrator in the course of its administration of the Glenmore Specialist Centre 4® Glenmore Specialist Centre may be monitored or recorded for the mutual protection of me and the Administrator;
- My Personal Information may be collected, used, disclosed and/or stored outside of my province or territory or country, and that the laws of those countries regarding privacy may be less stringent than the laws of Canada and its provinces; and

- I am entitled to a copy of this document.

By signing the front of this form, I acknowledge that I have read, understand and agree to these terms.

Administrator is one or more entities that run and administer all or part of the Program including Nvwcgwh Dksupaszjd Ssn., located at a nearby city 5, a nearby city 5, Ontario, Canada, a nearby city 5, and its affiliates or Nvwcgwh Dksupaszjd Ssn., located at a nearby city 6, Barrhaven, a nearby city 6, Canada, a nearby city 6, and its affiliates, and/or other third parties. I understand that the Administrator(s) may change without notice and I agree that the consent I provide herein shall also apply to any other Program Administrator(s).

Personal Information includes, without limitation, my Personal Information (name, address, phone number, date of birth, financial information, etc.) and personal health information (medical history, medical condition[s], information relating to my treatment, information relating to my health insurance, etc.).

Healthcare Providers includes, without limitation, my doctors, nurses, pharmacists and health insurer(s).

Glenmore Specialist Centre 4® Glenmore Specialist Centre Personnel include the Glenmore Specialist Centre 4® Care Managers and employees and consultants of the Administrator.

I consent to the receipt of electronic communications including email and text message from Highpark Health Centre 3, the Administrator, and Program Personnel, for the purposes of determining my eligibility for the Program, conducting Program-related activities and in the delivery of Program services to me and for the purposes I have consented to above regarding the collection, use and disclosure of my Personal Information. Email communications may be sent to the address I have provided and text messages may be sent to the telephone number I have provided. Standard data or message rates may apply; consult your carrier for details. I understand I can withdraw my consent at any time.

Bkfqkr	ENTYVIO® is a registered trademark of Bkfqkr Used under licence by Highpark Health Centre 3 Glenmore Specialist Centre 4® is a registered trademark of Shire Human Genetic Therapies, Inc., a Bkfqkr company. Product Monograph available on request.		
Highpark Health Centre 3 Northview Clinic 2 a nearby city 5, Northview Clinic 2 Calgary, Ontario, a nearby city 5	Highpark Health Centre 3 www.westbrookmedicalassociatesnorth.ca © 2020 Bkfqkr. All rights reserved. Bkfqkr and the Bkfqkr Logo are trademarks of Bkfqkr, used under license.	MEMBER OF Glenmore Specialist Centre	Glenmore Specialist Centre 4 SUPPORT FOR YOU, WITH YOU ♦ □ Entyvio® vedolizumab
	148 158		

Santiago Fitzgerald, Santiago Fitzgerald, Santiago Fitzgerald, Santiago Fitzgerald, Santiago Fitzgerald, Santiago Fitzgerald, Santiago Fitzgerald, Santiago Fitzgerald, Santiago Fitzgerald, Santiago Fitzgerald, Santiago Fitzgerald

Lakeshore Specialty Clinic 2 www.harbourmedicalcentre.ca

[ ] Saskatchewan - 636 Maple Blvd 472-336-3702 [ ] Saskatchewan - 636 Maple Blvd 472-336-3702 [ ] Saskatchewan - 636 Maple Blvd 472-336-3702 [ ] Quebec - 636 Maple Blvd 472-336-3702 [ ] Quebec - 636 Maple Blvd 472-336-3702

BOOKING PHONE# : 472-336-3702 BOOKING FAX# : 472-336-3702

PATIENT CLINICAL HISTORY:

Prebiologic R/O latent Tb Previous Imaging? Location & Date? Clinical Hx must be filled out

PATIENT Appointment:

Date: D ___ M ___ Y ___ Time: ___ am / pm Preparation # ___ See reverse page

---

X-RAY Walk-in only

Chest: [X] PA/Lateral [ ] Rib [ ] L [ ] R [ ] Sternum [ ] SC joints

Abdomen: [ ] KUB / Single [ ] Acute (3 views)

Spine: [ ] Cervical - Osteoarthritis [ ] Cervical w Flex/Ext - Trauma [ ] Thoracic [ ] Lumbosacral [ ] Sacrum / Coccyx [ ] SI joints

Other: [ ] [ ] Bone Age [ ] Skeletal Survey work-up [ ] Arthritic work-up [ ] Metastatic work-up

Head and Neck: [ ] Skull [ ] Facial Bones [ ] Nose [ ] TMJs [ ] Mandible [ ] [ ] Orbits - trauma [ ] Orbits - Pre MRI [ ] Adenoids/Soft tissue [ ] Sinuses (Uninsured)

Upper Extremity:

Bilat	L	R	Part
[ ]	[ ]	[ ]	AC joints
[ ]	[ ]	[ ]	Clavicle
[ ]	[ ]	[ ]	Shoulder
[ ]	[ ]	[ ]	Scapula
[ ]	[ ]	[ ]	Humerus
[ ]	[ ]	[ ]	Elbow
[ ]	[ ]	[ ]	Forearm
[ ]	[ ]	[ ]	Wrist

Bilat	L	R	Part
[ ]	[ ]	[ ]	Scaphoid
[ ]	[ ]	[ ]	Hand
[ ]	[ ]	[ ]	Fingers T 2 3 4 5

Lower Extremity: [ ] | [ ] | [ ] | Pelvis [ ] | [ ] | [ ] | Hip and Pelvis [ ] | [ ] | [ ] | Femur [ ] | [ ] | [ ] | Knee [ ] | [ ] | [ ] | Knee - Standing [ ] | [ ] | [ ] | Tibia/Fibula [ ] | [ ] | [ ] | Ankle [ ] | [ ] | [ ] | Foot [ ] | [ ] | [ ] | Os Calcis/Heel [ ] | [ ] | [ ] | Toes 1 2 3 4 5

NUCLEAR MEDICINE Booked appt only

[ ] MUGA [ ] Bone Scan [ ] Hepatobiliary [ ] Salivary [ ] Renal GFR [ ] with Lasix [ ] Other:

For BMD Studies - Use BMD Requisition

ULTRASOUND Booked appt only

[ ] Upper Abdomen [ ] HCC Surveillance/Portal HTN [ ] Liver Elastography (Fibrosis) [ ] Kidneys [ ] Bladder (Pre & Post Void) [ ] Pelvis (includes TV unless contraindicated) [ ] Small Part: _____ [ ] Early Dating [ ] IPS/EFTS (11w-13w6days) [ ] Routine [ ] Multi-gestation Date LMP: DD/MM/YYYY [ ] Breast [ ] L [ ] R Quadrant: _____ (<45yrs, Focal & Palpable Lump, No Cancer Hx)

[ ] Hernia - Abdo Wall [ ] Hernia - Umbilical [ ] Hernia - Inguinal [ ] Scrotal/Testicular [ ] Thyroid [ ] [ ] [ ] Salivary Glands [ ] L [ ] R [ ] Other: _____

[ ] Recheck/Limited [ ] Growth/EFW [ ] BPP/Cord Doppler [ ] MCA Doppler

Vascular: [ ] Venous - DVT [ ] L [ ] R Leg [ ] L [ ] R Arm [ ] Venous Insufficiency - Legs [ ] Arterial Legs - Bilateral [ ] Diabetic Foot Screening [ ] Aorta [ ] Carotids [ ] Renals Arterial [ ] Vascular Screening (Carotids, Aorta, Legs) [ ] Interventional Consult If Abnormal Vascular Study

Musculoskeletal: L R

L	R	Part
[ ]	[ ]	Hip
[ ]	[ ]	Hamstring
[ ]	[ ]	Knee
[ ]	[ ]	Ankle
[ ]	[ ]	Achilles
[ ]	[ ]	Plantar Fasciitis
[ ]	[ ]	Synovitis Study
[ ]	[ ]	Shoulder

L	R	Part
[ ]	[ ]	Elbow
[ ]	[ ]	Wrist
[ ]	[ ]	Digits T 2 3 4 5
[ ]	[ ]	Carpal Tunnel
[ ]	[ ]	Popliteal Fossa - Baker's Cyst
[ ] Other Msk: _____		

PATIENT INFORMATION:

DATE: D 06 / M 03 / Y 2022 M / F: F DOB: D 05 / M 09 / Y 1957 Name: Lucia Alvarez Address: 368 River Rd City: Calgary Home P#: (624) 837-1465 Cell P#: (624) 837-1465 Province: ON, Canada OHIP# / WCB#: 3062663187SX

TECH NOTES:

REV. Oct 2019 [ ] NCP

Practitioner SIGNATURE: [image] : Signature Dr. Santiago Fitzgerald : Printed Name Dr. Santiago Fitzgerald : CC Copy

Please bring this form & health card to your examination to avoid delay or cancellation

---

** For Bookings Please call 472-336-3702 and have your health card available**

LOCATIONS & SERVICES AVAILABLE

Fairlight Medical Centre	**Fairlight Medical Centre**	**Fairlight Medical Centre**	**Fairlight Medical Centre**	**Fairlight Medical Centre**
Suite 1300	Suite LL01	Suite 101	Unit 105	4th Floor
Saskatchewan, ON U4U 5X1	Quebec, ON BQT 3T9	Quebec, ON U4U 5X1	Saskatchewan, ON U4U 5X1	Saskatchewan, ON U4U 5X1
Ph 472-336-3702	Ph 472-336-3702	Ph 472-336-3702	Ph 472-336-3702	Ph 472-336-3702
Fx 472-336-3702	Fx 472-336-3702	Fx 472-336-3702	Fx 472-336-3702	Fx 472-336-3702
-Ultrasound	-Ultrasound	-Ultrasound	-Ultrasound	-Ultrasound
-Bone Density	-Bone Density	-X-Ray (Walk-in only)	-Bone Density	-X-Ray (Walk-in only)

Fairlight Medical Centre	Fairlight Medical Centre	Fairlight Medical Centre	Fairlight Medical Centre	Fairlight Medical Centre
-Nuclear Medicine	-X-Ray (Walk-in only)		-X-Ray (Walk-in only)	
-X-Ray (Walk-in only)				

ULTRASOUND - PATIENT PREPARATION

1. OBSTETRICAL / PELVIC / BLADDER EXAMINATIONS
    - A full bladder is required for this examination.
    - Finish drinking 1 litre of non-carbonated, clear fluid (water, black tea/coffee, juice - no dairy) 1 hour before your appointment.
    - Do not empty your bladder until the examination is finished.
    - Failure to completely finish drinking the required amount of fluid a full hour prior to your appointment time can reduce the accuracy and image quality of your examination.
2. UPPER ABDOMEN ULTRASOUND / HCC SURVEILLANCE / PORTAL HTN / LIVER ELASTOGRAPHY
    - DO NOT eat or drink for 8 hours prior to your appointment. Medications may be taken with a sip of water.
    - NO CARBONATED BEVERAGES OR GUM 8 hours prior to the examination.
3. ABDOMINAL + PELVIC/BLADDER
    - Do not eat or drink 8 hours prior to your appointment but finish drinking 1 litre of non-carbonated, clear fluid (water, black tea, coffee, juice - no dairy) 1 hour before your appointment time.
    - Do not empty your bladder until the examination is finished.
    - Failure to completely finish drinking the required amount of fluid a full hour prior to your appointment time can reduce the accuracy and image quality of your examination.
4. AORTA ONLY
    - DO NOT eat or drink for 4 hours prior to your appointment.
5. KIDNEYS ONLY
    - No preparation required.
6. CHILDREN
    - Please call our bookings office for preparation advice.
7. VASCULAR
    - Please call our bookings office for preparation advice.

NUCLEAR MEDICINE - PATIENT PREPARATION

8. RENAL GFR / WITH LASIX
    - FINISH drinking 1 litre of fluids one hour before your appointment time. You may empty your bladder.
9. HEPATOBILIARY (HIDA)
    - DO NOT eat for 4 hours prior to your appointment (but not longer than 24 hours).
    - NO opioid medications or opioid drugs for 4 hrs prior to your appointment.
10. BONE SCAN
    - No preparation required.
11. MUGA
    - No preparation required.
12. SALIVARY
    - No preparation required.

You MUST arrive 10 minutes prior to your appointment to complete registration. If you are late, another appointment may have to be arranged.

This requisition form can be taken to any licenced facility providing healthcare services including hospitals and Independent Health Facilities.

Visit us at... www.harbourmedicalcentre.ca

Glenmore Specialist Centre Laboratory Requisition Requisitioning Clinician / Practitioner

Name Dr. Santiago Fitzgerald

Address 760 Sherwood Ave

Clinician/Practitioner Number	**CPSO / Registration No.**
817811	

Check (□) one: [X] OHIP/Insured [ ] Third Party / Uninsured [ ] WSIB

Additional Clinical Information (e.g. diagnosis) [ ] Fast for 12 hours [ ] Fast Overnight

[X] Copy to: Clinician/Practitioner Last Name Fitzgerald First Name Santiago Address 760 Sherwood Ave

Laboratory Use Only

Clinician/Practitioner's Contact Number for Urgent Results (624) 837-1465

Service Date yyyy (blank) mm (blank) dd (blank)

Health Number 3062663187SX Version (blank) Sex F Date of Birth 1957

Province ON Other Provincial Habiba Lindgren

Patient's Telephone Contact Number (624) 837-1465

Patient's Last Name (as per OHIP Card) Alvarez Patient's First & Middle Names (as per OHIP Card) Lucia Alvarez Patient's Address (including Postal Code) 368 River Rd Calgary ON BQT 3T9

Note: Separate requisitions are required for cytology, histology / pathology and tests performed by Public Health Laboratory

x	**Biochemistry**	x	**Hematology**	x	**Viral Hepatitis (check one only)**
[ ]	Glucose [ ] Random [ ] Fasting	[X]	CBC	[ ]	Acute Hepatitis
[ ]	HbA1C	[ ]	Prothrombin Time (INR)	[ ]	Chronic Hepatitis
[ ]	TSH		Immunology	[X]	Immune Status / Previous Exposure Specify: [X] Hepatitis A [X] Hepatitis B [X] Hepatitis C or order individual hepatitis tests in the "Other Tests" section below
[X]	Creatinine (eGFR)	[ ]	Pregnancy test (Urine)		
[ ]	Uric Acid	[ ]	Mononucleosis Screen		
[ ]	Sodium	[ ]	Rubella		
[ ]	Potassium	[ ]	Prenatal: ABO, RhD, Antibody Screen (titre and ident. if positive)		
[ ]	Chloride				
[ ]	CK	[ ]	Repeat Prenatal Antibodies		Prostate Specific Antigen (PSA)
[X]	ALT		Microbiology ID & Sensitivities (if warranted)	[ ]	Total PSA [ ] Free PSA
[X]	Alk. Phosphatase				Specify one below:
[X]	Bilirubin total and direct	[ ]	Cervical	[ ]	Insured - Meets OHIP eligibility criteria
[X]	Albumin	[ ]	Vaginal	[ ]	Uninsured - Screening: Patient responsible for payment

x	Biochemistry	x	Hematology	x	Viral Hepatitis (check one only)
[ ]	Lipid Assessment (includes Cholesterol, HDL-C, Triglycerides, calculated LDL-C & Chol/HDL-C ratio; individual lipid tests may be ordered in the "Other Tests" section of this form)	[ ]	Vaginal / Rectal – Group B Strep		Vitamin D (25-Hydroxy)
[X]	Vitamin B12	[ ]	Chlamydia (specify source):	[X]	Insured - Meets OHIP eligibility criteria: osteopenia; osteoporosis; rickets; renal disease; malabsorption syndromes; medications affecting vitamin D metabolism
[ ]	Ferritin	[ ]	GC (specify source):		
[ ]	Albumin / Creatinine Ratio, Urine	[ ]	Sputum	[ ]	Uninsured – Patient responsible for payment
[ ]	Urinalysis (Chemical)	[ ]	Throat		Other Tests - one test per line
[ ]	Neonatal Bilirubin:	[ ]	Wound (specify source):		AST - advised by hepatologist
	Child's Age: days hours	[ ]	Urine		CRP
	Clinician/Practitioner's tel. no.	[ ]	Stool Culture		Serum iron (IBD)
	Patient's 24 hr telephone no.	[ ]	Stool Ova & Parasites		Iron saturation
	Therapeutic Drug Monitoring:	[ ]	Other Swabs / Pus (specify source):		HepB Surface Antigen
	Name of Drug #1				HepB Core antibody
	Name of Drug #2		Specimen Collection		
	Time Collected #1 hr. #2 hr.		Time (blank) Date YYYY-MMM-DD		
	Time of Last Dose #1 hr. #2 hr.		Fecal Occult Blood Test (FOBT) (check one)		
	Time of Next Dose #1 hr. #2 hr.		[ ] FOBT (non CCC) [ ] ColonCancerCheck FOBT (CCC) no other test can be ordered on this form		

I hereby certify the tests ordered are not for registered in or out patients of a hospital.

X [signature] Clinician/Practitioner Signature

2022-Mar-06 Date

Laboratory Use Only

817811 (2010/09) ©Glenmore Specialist Centre, 2010 817811

PHYSICIAN STATUS REPORT

Glenmore Specialist Centre 4® SUPPORT FOR YOU, WITH YOU™

TO: Dr. Fitzgerald	Date: 06 March 2022
FROM: < Stonebridge Health Clinic 4>	Page: 1
Patient Name: Lucia Alvarez	Patient ID#: D-4474057291

Section 1 Program Notifications / Updates [ ] Reimbursement [ ] Adverse Event/Product Quality Complaint [ ] Financial Assistance [ ] Entyvio® (vedolizumab) Treatment Scheduling [ ] Travel Assistance [ ] Entyvio® (vedolizumab) Infusion Administration [ ] Unable to Contact Patient [ ] Entyvio® (vedolizumab) Injection Administration & Training [ ] Waiting on Patient's Insurance Information [ ] Special Authorization Required [ ] Patient Discontinued Therapy [ ] Medical Clarification Required [ ] Patient Dropped Out [ ] Entyvio® (vedolizumab) Infusion Appointment Information

ACTION REQUIRED [X] NO ACTION REQUIRED

Section 2: COMMENTS Dear Dr. Fitzgerald

Thank you for enrolling Lucia Alvarez into the Glenmore Specialist Centre 5 for Entyvio

Please be advised that we have received the enrolment and we will proceed with contacting your patient.

We will notify you if we require any additional information as well as the status outcome to the process.

If you have any questions about the Stonebridge Health Clinic 4 and/or about your patient's status, please call 930-216-8546

Sincerely,

Stonebridge Health Clinic 4

ENTYVIO® is registered trade mark of Bkfqkr Used under license by Highpark Health Centre 3 Glenmore Specialist Centre 4® is a registered trademark of Highpark Health Centre 3

Stonebridge Health Clinic 4 Telephone: 930-216-8546 Fax: 930-216-8546 Email: farah.kavanagh93@maplehealthclinic.ca

---

Sunnymede Family Practice 2 Harbour Medical Centre 2 Lakeshore Specialty Clinic 4 Crestwood Medical Group 7

Dr. Cesar Marchetti MSc Fitzgerald FRCPC Gastroenterologist, Harbour Medical Centre 3 496 Aldergrove Ave, Calgary, Ontario X3J 9M0 t: 786 370 1461 ext. 4254 f: (899) 593-3646

Feb 27, 2022

Dr. Fitzgerald 368 River Rd Quebec, ON

Patient: Ms. Lucia Alvarez PHN: 9187508760-FM Birthdate: Sep 5, 1957 Phone: H: (899) 593-3646 C: (624) 837-1465 Address: 368 River Rd Calgary, ON BQT 3T9

Dear Dr. Fitzgerald,

Sunnymede Family Practice 2 - NEW CONSULT

Lucia Alvarez was seen in virtually in consultation at the Sunnymede Family Practice 2 on Feb 27, 2022 for a new consultation.

Lucia is a 64-year-old with sticturing Crohn's disease, on no medication.

Informed verbal consent was obtained from this patient to communicate and provide care using virtual and other telecommunications tools. This patient has been explained the risks related to unauthorized disclosure or interception of personal health information and steps they can take to help protect their information. We have discussed that care provided through video or audio communication cannot replace the need for physical examination or an in person visit for some disorders or urgent problems and patient understands the need to seek urgent care in an Emergency Department as necessary.

IBD Phenotype: B2 Prior (IBD) Therapies: Pentasa; Steroids 2001 IBD Complications: None IBD Extraintestinal Manifestations: None Past Medical History: Crohn's disease; Possible celiac disease; Asthma;Hypothyroidism;OP Past Surgical History: 3 C/S Known Allergies: None External Medications: Prolia;Atrovent Lifestyle Notes: None Family History: None

History of Present Illness:

Lucia had symptoms prior to 2001 with diarrhea and abdominal pain. She had a SBO in 2001 when she was given a likely diagnosis of IBD.

Lucia has been feeling well. She has perioids of 1 BM per day and sometimes it can be 4 to 6 but it is difficult. Her stools are often of variable consistency. None of her bowel movements are bloody. She has occasional abdominal pain in the mid lower abdomen. No nauese or vomiting. She has occasional bloating. She reports no constitutional symptoms. She reports no extraintestinal manifestations of IBD.

She has had staph infection in the past.

Patient: Lucia Alvarez PHN: 3062663187SX DOB: Sep 5, 1957

Disease Activity Scores: {HBI: | 5 on Feb 23, 2022

Physical Exam

NOT standard care DUE TO COVID19

Impression and Plan:

In summary, Lucia is a 64 year old with inflammatory stricturing Crohn's disease currently on no medication, who does have symptoms, although minimal impact to her QoL.

We had a discussion about the various options for treating her disease.

She could consider with a watch and wait approach but when you ask her, she does have symptoms. Further she has active disease on MRI so I worry about this progressing and her developing further complications.

We also discussed surgical approach but she has multiple skip lesions, so this [REDACTED-DATE] not be the best approach to start.

Last we discussed biologics. I think she might benefit from Entyvio or Stelara. She is going to read about them. She has had recurrent staph infections requiring IV antibiotics so I would not recommend steroids or antiTNF.

I have told her to arrange an appointment with you to start the process for Entyvio or Stelara. She seemed to be leaning towards Entyvio. She is going away [REDACTED-DATE] and will call your office upon her return.

I advise a CT enterography to be standard care 6 months after starting biologic therapy.

I have not arranged follow up but would be happy to see as needed.

Thank you for involving me in her care.

Sincerely,

[image]

Cesar Marchetti Darius Velasquez Farah Mehta **Electronically Reviewed to Expedite Delivery**

Patient Lucia Alvarez PHN: 3062663187SX DOB: Sep 5, 1957

Sunnymede Family Practice 2 Harbour Medical Centre 2 Lakeshore Specialty Clinic 4 Crestwood Medical Group 7

Dr. Cesar Marchetti Gastroenterologist, Harbour Medical Centre 3 496 Aldergrove Ave, Calgary, Ontario X3J 9M0 t: 786 370 1461 ext. 4254 f: (899) 593-3646

APPOINTMENT NOTIFICATION - PATIENT IS AWARE

Date: 2021-Dec-20

Dear Lucia Alvarez

Your physician Dr. Santiago Fitzgerald has referred you to our Gastroenterology clinic for consultation.

Appointment date: Feb 27, 2022 time: 20:42 Location: DUE TO COVID pandemic, this will be a PHONE CALL visit.

Sunnymede Family Practice 2 is affiliated with the Harbour Medical Centre 3. Dr. Marchetti is highly specialized and may have trainees (medical students, residents, fellows) learning during your clinic encounter.

- Please ensure all relevant files and other investigations have them faxed to us before your clinic appointment.
    - [ ] Colonoscopy/gastroscopy or other operative reports AND Pathology reports
    - [ ] Laboratory reports
    - [ ] Ultrasound/X-ray/CT scan/MRI reports
    - [ ] ALL past medical history
    - [ ] Any Other relevant documents
- Please remember to
    - [ ] Ensure you have a valid HEALTH CARD, or other insurance documentation.

CANCELLATION POLICY CANCELLATIONS WITH LESS THAN 2 BUSINESS DAY'S NOTICE WILL RESULT IN A $150 FEE NOT COVERED BY OHIP. You have been given the next available appointment date and time based on triage of your referral. Failure to confirm your appointment in a timely manner may result in your time being given away to another patient. Due to our long waiting lists, we do not keep cancellation lists. Failure to attend a scheduled appointment may result in your consultation being delayed or cancelled.

Patient: Lucia Alvarez PHN: 3062663187SX DOB: 1957

[X] --

This task has been completed

Patient	Alvarez, Lucia	**Task Created By**	[REDACTED-STAFF-PROVIDER-NAME-OR-USERNAME]
Date Due	12/16/2021	**Priority**	Urgent
Assigned To	[REDACTED-STAFF-PROVIDER-NAME-OR-USERNAME]	**Completed**	2021-Dec-17 by [REDACTED-STAFF-PROVIDER-NAME-OR-USERNAME]

Notes	- can we get prior CT at Glenmore Specialist Centre from 2000-2002 ish - thx vbbyxtg. 2021-Dec-16 XG:no luck with Birchwood Care Clinic 3, faxed Glenmore Specialist Centre health records. 2021-Dec-16 XG:attached		

Glenmore Specialist Centre

368 River Rd. Quebec, U4U 5X1 Tel: 496-380-7749 Fax: 930-216-8546

Santiago Fitzgerald Santiago Fitzgerald, FRCPC Santiago Fitzgerald

Practice Share: Santiago Fitzgerald Santiago Fitzgerald

AUTHORIZATION TO RELEASE INFORMATION

Lucia Alvarez F 368 River Rd Calgary, ON BQT 3T9 DOB: 08/06/1957 PHN: 3062663187SX

Doctor: Dr. Santiago Fitzgerald Address: 368 River Rd Quebec U4U 5X1 Fax: (624) 837-1465 Phone: (624) 837-1465

Information Requested:

[ ] Consult Notes (blank) [ ] Operative Notes (blank) [ ] Laboratory Reports (blank) [ ] Pathology (blank) [X] X-Ray/Diagnostic CT scan 2000-02

Dr. Fitzgerald is requesting copies of the above reports to aid in the treatment of out patient.

[image] Dr. Signature

Review

This task has been completed

Patient: Alvarez, Lucia Task Created By: [REDACTED-STAFF-PROVIDER-NAME-OR-USERNAME] Date Due: 12/15/2021 Priority: Normal Assigned To: [REDACTED-STAFF-OR-PROVIDER-NAME] Completed: 2022-Jan-04 by [REDACTED-STAFF-OR-PROVIDER-NAME] Notes: f/u 6-9months referral track to Stonebridge Health Clinic 3 - thx vbbyxtg. Dr. Marchetti-[REDACTED-DATE] 2022-Jan-04(hwqwemu): pt aware of Dr. Marchetti appt :) Office FU booked July 6th, trying robocaller to see how this works

---

Patient: Mrs. Lucia Alvarez Appointment Date: 2021-Dec-15 Title: Chart Notes Provider: Fitzgerald, Santiago Referred By: Fitzgerald, Santiago

Alvarez was seen today to follow up with regards to assessment and management of Crohn's.

As per current public health recommendations the patient was given an option for in person or virtual visit and prefers a virtual visit by phone. The entire visit was standard care as per usual standards with the exception of a physical exam.

Past medical history: Crohn's disease - Dx in 2001 - presented with SBO, but never required surgery. Was on 5-ASA and one course of steroids, no prior biologics. Possible celiac disease - DQ2 positive but not homozygous - celiac antibodies and duodenal biopsies Asthma Hypothyroidism Osteoporosis

Current medications: Atrovent, dessicated thyroid, prolia.

Allergies: None.

Social history: Non-smoker, rare EtoH, no illicit drugs.

Family history: Non-contributory.

History of presenting illness: Feels OK but feels like she is doing less well. She is having 2-3 loose BM/day, no blood or mucous. No abdominal pain. No obstructive symptoms. Appetite, energy, and weight stable. No extraintestinal manifestations of IBD. Eats gluten in her diet. Review of systems otherwise unremarkable.

Labs: Aug 30, 2021 revealed: HgB 136, WBC 6.2, Plt 340, Bilirubin 6, AST 16, ALT 16, ALP 74, B12 222, CRP 4.7.

Endoscopic evaluation: Gastroscopy and colonoscopy on Sep 12, 2021. Unremarkable gastroscopy with gastric and duodenal biopsies taken. Colonoscopy complete to ileocecal valve at which point there was a benign narrowing of the ileocecal valve, but no active inflammation. Biopsies taken from the terminal ileum across the ileocecal valve as well as right and left colon. No active colitis. Duodenal, gastric, right and left colon biopsies normal. Terminal ileum biopsies moderate chronic colitis with small numbers of neutrophils. Rectum polyp, hyperplastic polyp.

Imaging: MRI on Dec 9, 2021. Active inflammatory Crohn's disease affecting distal 12cm of TI with 2 additional skip lesions.

No prior imaging for many years - prior colonoscopy in 2002 showed thickening TI.

Impression and Plan: Alvarez has long-standing CD and in clinical remission although her MRI does show a fairly long segment of active TI disease. I am going to request her original CT which was the last SB imaging she has back in 2002 because since she has had such minimal symptoms and no complications over 20 years I am reluctant to suggest any biologic therapy at this time. Given the extent of her SB disease on imaging, she is wondering about the role of biologics in preventing further complications and I am going to ask for a second opinion from my colleague at Brookfield Medical Centre 3 Dr. Cesar Marchetti to see what he thinks. I will try to request the original CT from 2002 in case that is helpful. I will see her back in 6-9 months.

IBD Plan:

1. Maintain up to date vaccinations with GP.
2. Avoid NSAIDs and anti-inflammatories which can cause flares of IBD, tylenol is safe.
3. Patient counselled on risks and side effects of current medical therapy.
4. Patient knows to contact me if they develop signs of a disease exacerbation including worsening abdominal

---

pain, diarrhea, or blood in the stools.

Thank you for involving me in the care of this patient. Please don't hesitate to contact me if you have any questions or concerns.

Patient: Mrs. Lucia Alvarez **Appointment Date:** 2021-Dec-15 **Title:** Referral Letter **Provider:** Fitzgerald, Santiago **Referred By:** Fitzgerald, Santiago Pls see for second opinion regarding biologics for CD.

MRI shows extensive TI disease but Dx in 2002 and minimal symptoms. No imaging since CT in 2002 so hard to know whether its progressed. I am reluctant to start treatment given her mild disease course but interested your thoughts given the recent MRI.

See attached records.

Glenmore Specialist Centre

760 Sherwood Ave

Fax Cover Sheet

To: Dr. Cesar Marchetti Phone:(769) 569-5105 Fax: (899) 593-3646

Date: 2021-Dec-15

Check out our new website at www.birchwoodcareclinic.ca

From: Dr. Santiago Fitzgerald Phone: (624) 837-1465 Fax: (624) 837-1465

Number of pages including cover: 17

Re: Lucia Alvarez

non urgent second opinion IBD

Confidential: This communication is intended only for the individual or institution to which it is addressed and should not be distributed, copied or disclosed to anyone else. The documents in this communication may contain personal, confidential or privileged information, which may be subject to the Freedom of Information and Protection of Privacy Act, the Health Information Act and other legislation. If you have received this communication in error, please notify us immediately and return original transmission to us. Thank you for your co-operation and assistance.

Dr. Santiago Fitzgerald Glenmore Specialist Centre 760 Sherwood Ave Phone: (624) 837-1465 Fax: (624) 837-1465

2021-Dec-15

Dr. Cesar Marchetti 496 Aldergrove Ave Calgary, ON X3J 9M0

Patient: Mrs. Lucia Alvarez PHN: 9187508760-FM Birthdate: 1957 Phone Number: (624) 837-1465, Work: (791) 442-5889 Cell: (624) 837-1465 Address: 760 Sherwood Ave Boris Halvorsen

Dear Dr. Marchetti,

Pls see for second opinion regarding biologics for CD.

MRI shows extensive TI disease but Dx in 2002 and minimal symptoms. No imaging since CT in 2002 so hard to know whether its progressed. I am reluctant to start treatment given her mild disease course but interested your thoughts given the recent MRI.

See attached records.

Sincerely,

[image]

Santiago Fitzgerald Electronically Reviewed to Expedite Delivery

Enclosures (15)

Patient: Lucia Alvarez PHN: 3062663187SX DOB: 1957

Hospital Report

Patient	Alvarez, Lucia	**Home Phone**	(624) 837-1465	**Work Phone**	
Health #	3062663187SX	**Sex**	F	**Patient ID**	817811
Age	64 years				
DOB	1957				

Facility Report #:	LG32777823-13507		
Sent to:	Fitzgerald, Santiago	**Reported By:**	Westbrook Medical Associates 2
Collection Date:	2021-Dec-09	**Reviewed:**	2021-Dec-12 by [REDACTED-STAFF-PROVIDER-NAME-OR-USERNAME]
Message Unique ID:	LG32777823-13507		
Source Author:	[REDACTED-PROVIDER-UNIQUE-IDENTIFIER]^[REDACTED-PROVIDER-NAME]^[REDACTED-PLAN-MEMBER-GIVEN-NAME]^[REDACTED-PROVIDER-NAME]^MD		
Updated On:	2021-Dec-12 20:42		

Flags Results Ref Range Lakeshore Specialty Clinic 5 (S) MRI See Below

Glenmore Specialist Centre

Maple Health Clinic 4 Alberta Quebec, ON BQT 3T9 930-216-8546

Medical Imaging Report Report Status: Signed

Patient: Alvarez, Lucia DOB/Age/Sex: 05/09/1957 / 64 / F FWS: F529685831 Znwj: VW4047402/93 HCN: 9187508760-FM Report Number: LG32777823-13507

Ordering Provider: Fitzgerald, Santiago Primary Care Provider: Santiago Fitzgerald Copies To: Santiago Fitzgerald; Santiago Fitzgerald

Procedure(s): MRI Abdomen 4 REP wGD 3D Procedure Date/Time (DD/MM/YY): [REDACTED-DATE] 20:42 Accession Number(s): LG32777823-13507

PROCEDURE: MRI Abdomen 4 REP wGD 3D

CLINICAL HISTORY: History of Crohn's disease. Assess disease activity.

TECHNIQUE: Multiplanar and multiparameter pre/post contrast pulse sequences.

COMPARISON: No prior relevant studies.

FINDINGS: Evidence of active inflammatory Crohn's disease, with circumferential wall thickening, mural edema and mucosal hyperenhancement. The longest segment of involvement involves the distal 12 cm of the terminal ileum. 2 skip lesions are identified, the longest of which is situated deep within the pelvis, measuring approximately 13 cm in length, axial postcontrast images 33-39.

Patient: Lucia Alvarez

Additional smaller anteriorly situated skip lesion located just to the right of the midline, axial postcontrast image 16, series 11.

No evidence of a right lower quadrant or pelvic fistula. The peroneal area has not been evaluated for fistula. No lymphadenopathy or abscess. No evidence of an obvious colitis or proctitis. Limited assessment of the abdominal viscera. Cholelithiasis.

IMPRESSION: Active inflammatory Crohn's disease. Cholelithiasis.

Dictated By: Fitzgerald, Santiago Electronically Signed By: Fitzgerald, Santiago Dictated Date/Time (DD/MM/YY): 12/12/2021 20:42 Transcribed Date/Time (DD/MM/YY): 12/12/2021 20:42

This report may have been generated using speech recognition software. If there are any concerns regarding the contents, please notify us immediately. LAB results are captured at the point in time of report dictation, please review Highpark Health Centre 2 for current LAB results.

NOTE: This report is confidential under the Personal Health Information Protection Act, 2004 (PHIPA) and is intended for authorized individuals and the above named recipient(s). If you have received this in error, please notify the sender at (Sunnymede Family Practice 930-216-8546, Sunnymede Family Practice 930-

216-8546, Sunnymede Family Practice 930-216-8546, Glenmore Specialist Centre (624) 837-1465) and destroy any copies you have. Any unauthorized distribution, disclosure or use of this document is strictly prohibited.

MRI Abdomen 4 REP wGD 3D - 2021-Dec-09 20:42 Principal Author: Fitzgerald, Santiago

---

Facility Report #:	LG32777823-13507		
Sent to:	Fitzgerald, Santiago	**Reported By:**	Westbrook Medical Associates 2
Collection Date:	2021-Sep-12	**Reviewed:**	2021-Sep-12 by [REDACTED-STAFF-PROVIDER-NAME-OR-USERNAME]
Message Unique ID:	LG32777823-13507		
Source Author:	817811^[REDACTED-STAFF-PROVIDER-NAME-OR-USERNAME]^[REDACTED-STAFF-OR-PROVIDER-NAME]^[REDACTED-STAFF-OR-PROVIDER-NAME]^		
Updated On:	2021-Dec-12 20:42		

Flags Results Ref Range MEDICAL RECORDS (S) Sunnymede Family Practice OPERATIVE REPORT See Below Glenmore Specialist Centre 368 River Rd Quebec, Ontario U4U 5X1 TELE (624) 837-1465

Patient Name: Alvarez, Lucia Unit #: 817811 DATE SEEN: Zdzq #: XW645399/88 CLINIC DATE: DOB/Sex: 05/09/1957/F DISC DATE: Room #: REG DATE: Report #: LG32777823-13507 REV DATE: 12/09/2021 OR DATE: COPIES: Fitzgerald, Santiago; Fitzgerald, Santiago mnemonic: YOKTO;;FORKY;FORKY;;FORKY;FORKY; YOKTO DATE OF PROCEDURE: Sep 12, 2021

Patient: Lucia Alvarez

SURGEON: Dr. Santiago Fitzgerald

ANAESTHETIST: Dr. Ethan Farrow

PREOPERATIVE DIAGNOSIS: Possible celiac disease and history of potential Crohn's disease.

POSTOPERATIVE DIAGNOSES: Unremarkable gastroscopy with gastric and duodenal biopsies taken. Colonoscopy complete to ileocecal valve at which point there was a benign narrowing of the ileocecal valve, but no active inflammation. Biopsies taken from the terminal ileum across the ileocecal valve as well as right and left colon. No active colitis. Follow up in a few months.

OPERATION: Gastroscopy and colonoscopy.

CLINICAL NOTE: Dear Dr. Fitzgerald, please see recent clinic note for full details. As you know, Lucia was originally diagnosed with Crohn's disease when she presented with a small bowel obstruction, which was managed conservatively. She had 1 course of steroids and never being on any specific medications. There is also a question of celiac disease given that her daughter has celiac disease and she does have one of the genes that are positive, but normal celiac serology.

She is here for a gastroscopy to assess for celiac disease and also colonoscopy to reassess her Crohn's disease.

She has been feeling well in the interim. She continues on the gluten rich diet. She denies any abdominal pain, obstructive symptoms or change in her bowel habit. There have been no rashes or joint pain. Her review of systems otherwise unremarkable.

On examination, she looks well. Head and neck exam unremarkable. Abdominal exam reveals soft, nondistended, nontender abdomen with no appreciable organomegaly or stigmata of chronic liver disease. Examination of her extremities revealed no swelling or erythema bilaterally.

IMPRESSION: Given the possible history of celiac disease as well as Crohn's disease is certainly important to proceed with a gastroscopy and colonoscopy today. I discussed the benefits, risks and alternatives of the procedure including risk of sedation, aspiration, bleeding, infection, perforation and missed lesions. Written informed consent was obtained. All questions were answered. The patient was brought to endoscopy room in stable condition.

Her recent labs were standard care on Aug 30, 2021 which revealed normal CBC, normal liver enzymes and celiac testing including an anti-tTG level as well as IgA level and gliadin level were all normal.

PROCEDURE: The patient was placed in left lateral decubitus position and intravenous sedation was provided. A bite block was inserted and the gastroscope was advanced through the bite block in the oropharynx all the way to the second portion of duodenum. Duodenum was unremarkable. Biopsies were taken from second portion as well as the bulb to rule out celiac disease. Careful examination of the stomach including retroflexed views of the cardia, fundus, and incisura revealed no abnormality. GE junction was noted at 40 cm. There is no esophagitis or Barrett's. The remaining esophagus and oropharynx was unremarkable. Scope was removed after decompressing stomach. The bed was then repositioned for colonoscopy. Digital rectal examination revealed no

---

abnormality. Adult colonoscope was advanced through the anal verge all the way to the ileocecal valve. There was some smooth narrowing at the ileocecal valve, likely scarring from prior inflammation, but there was certainly no ulceration and no evidence of active disease. I could peek just barely across to the terminal ileum which appeared normal and I took some biopsies from the terminal ileum. Total withdrawal time was 10 minutes. I carefully inspected the entire colon including the right colon twice in forward flexion. There was no active colitis. Random biopsies were taken from a normal appearing right and left colon. There is one 4 mm polyp in the rectum likely hyperplastic, removed with a cold snare. Rectal retroflexion was otherwise unremarkable. Scope was removed after decompressing the bowel. The patient tolerated the procedure well without complication. The patient will be monitored in the recovery room and go home later today.

IMPRESSION AND PLAN: Lucia had a normal gastroscopy and I will followup on the duodenal biopsies and assuming they are normal, then we can say definitively that she does not have celiac disease. With regards to her Crohn's disease, I has certainly been a quiescent course and she has had no issues for many years and there is no evidence of any active inflammation. I do not think she needs additional investigations in that regard. I will follow up with her in a couple months and advised ongoing management.

Thank you for involving me in her care. Please do not hesitate to contact me at any time if you have any questions or concerns.

Signed Santiago Fitzgerald, AUTHENTICATED BY ELECTRONIC MEANS FORKY DD: 12/09/2021 DT: 12/09/2021 Report No: LG32777823-13507

This report may have been generated using voice recognition software. If there are any concerns regarding the contents, please notify us immediately. NOTE: This report is confidential under the Personal Health Information Protection Act, 2004 (PHIPA) and is intended for authorized individuals and the above named recipient(s). If you have received this in error, please notify the sender by fax at (624) 837-1465 and destroy any copies you have. Any unauthorized distribution, disclosure or use of this document is strictly prohibited. Principal Author: Fitzgerald, Santiago

Patient: Lucia Alvarez

Santiago Zimmerman Glenmore Specialist Centre Manitoba Quebec, Ontario U4U 5X1 Telephone: (624) 837-1465 Fax: (624) 837-1465 FILE COPY

PROCEDURE NOTE

PATIENT: Alvarez, Lucia DOB: Sep 5, 1957 DATE: May 23, 2012

PRE PROCEDURE DIAGNOSES: Reassessment of Crohn's and screening colonoscopy.

POST PROCEDURE DIAGNOSES: Narrowed TI without inflammatory changes. Biopsies from TI and ileocecal valve taken, extremely mild patchy colitis. Random biopsies taken, small hemorrhoids.

OPERATIVE PROCEDURE: Colonoscopy.

ENDOSCOPIST: Dr. Santiago Zimmerman

ANESTHETIST: Dr. Santiago Fitzgerald

CLINICAL NOTE:

Dear Dr. Wickramasinghe:

This 54-year-old was recently reassessed with regards to her Crohn's disease. She had been hospitalized in 2001 with partial bowel obstruction from terminal ileal Crohn's disease. She has had erythema nodosum in the setting of subsequent flares, but I believe has only used Pentasa sporadically in the past. She does have osteoporosis. Recent blood work was normal. Clinically, she is in remission with Harvey-Bradshaw index of 0 and her symptoms are more suggestive of functional bowel disorder. We undertook colonoscopic exam today.

PROCEDURE:

Sedation was provided by anesthesia. Following normal digital rectal exam, anoscopy revealed small internal hemorrhoids. The pediatric Olympus variable video colonoscope was introduced and maneuvered in the usual fashion over to the cecum. We were able to get into the distal terminal ileum, but could not move further than that suggesting that she has a bit of stricturing process there, but it was not obviously scarred or inflamed, nor ulcerated. I did biopsies from the terminal ileum and at the anastomosis. There are some tiny ulcers in the cecum and I noted scattered loss of vascularity during the gradual withdrawal of the scope, but no significant Crohn's colitis present. Random colon biopsies taken and again the small hemorrhoids noted. She tolerated the procedure well and was returned to recovery in satisfactory condition.

.../2

Alvarez, Lucia

SUMMARY:

Lucia Alvarez's Crohn's is in remission clinically and endoscopically. I will be in touch if there are any concerns from the biopsies. She will stay on a low residue diet. I do not feel strongly about the Pentasa, as there is a very little data suggesting it does a lot in Crohn's disease. There were no polyps identified. I will follow her up in the office in 4 to 6 months' time, sooner if symptoms develop.

Sincerely,

[REDACTED-PROVIDER-NAME] Santiago Zimmerman

Dictated but not read.

vbbyxtg/XG

cc: Dr. Roya Wickramasinghe

Glenmore Specialist Centre 6 Medical Laboratory Services

760 Sherwood Ave

Histopathology

RECEIVED [REDACTED-DATE]

HISTOPATHOLOGY REPORT

PATH NO.: LG32777823-13507	PATIENT: Lucia Alvarez	hwqwemu: 7811 918 750
COLLECTED: 05/23/2012	DOB: 09/05/1957 (54) SEX: F	INTRLAB: LG32777823-13507

RECEIVED: 05/24/2012	PHYSICIAN: Santiago Zimmerman	(899) 593-3646
REPORTED: 06/03/2012	LOCATION: Glenmore Specialist Centre 760 Sherwood Ave	

Copies sent to: Roya Wickramasinghe

CLINICAL DATA: A. TERMINAL ILEUM. BIOPSY. HISTORY CROHN'S. B. ILEOCECAL VALVE. BIOPSY. HISTORY CROHN'S. C. RANDOM COLON. BIOPSY. HISTORY CROHN'S. /vbbyxtg

DIAGNOSIS: A - TERMINAL ILEUM: SMALL BOWEL MUCOSA, TERMINAL ILEAL: MILD ACUTE AND CHRONIC ILEITIS NO EVIDENCE OF GRANULOMA, DYSPLASIA OR MALIGNANCY B - ILEOCECAL VALVE: COLONIC MUCOSA: NO DIAGNOSTIC ABNORMALITY C - RANDOM COLON: INFILTRATION OF LAMINA PROPRIA WITH MILD CHRONIC INFLAMMATORY INFILTRATE NO EVIDENCE OF ACTIVE COLITIS, GRANULOMA, DYSPLASIA OR MALIGNANCY

SPECIMEN: A SPECIMEN SITE: TERMINAL ILEUM

GROSS DESCRIPTION: Specimen container labeled A. In fixative, 2 tissue fragments 0.4 x 0.2 x 0.1 cm. Submitted in toto. Block(s) / fragment(s): A/2. /XG

SPECIMEN: B SPECIMEN SITE: ILEOCECAL VALVE

GROSS DESCRIPTION:

[illegible stamp]

Santiago Zimmerman Glenmore Specialist Centre LL1 760 Sherwood Ave

Electronically Reported By: Keziah Calloway

Glenmore Specialist Centre 6 Medical Laboratory Services

760 Sherwood Ave

Histopathology

HISTOPATHOLOGY REPORT

PATH NO.: LG32777823-13507	PATIENT: Lucia Alvarez	hwqwemu: 7811 918 750
COLLECTED: 05/23/2012	DOB: 09/05/1957 (54) SEX: F	INTRLAB: LG32777823-13507
RECEIVED: 05/24/2012	PHYSICIAN: Santiago Zimmerman	(899) 593-3646
REPORTED: 06/03/2012	LOCATION: Glenmore Specialist Centre 760 Sherwood Ave	

Copies sent to: Roya Wickramasinghe

Specimen container labeled B. In fixative, 3 tissue fragments 0.4 x 0.3 x 0.1 cm. Submitted in toto. Block(s) / fragment(s): B/2+fragment. /XG

SPECIMEN: C SPECIMEN SITE: RANDOM COLON

GROSS DESCRIPTION: Specimen container labeled C. In fixative, multiple fragments, in aggregate 0.5 x 0.5 x 0.1 cm. Submitted in toto. Block(s) / fragment(s): C/3+fragments. /XG

[REDACTED-STAFF-USERNAME-OR-NAME]

Santiago Zimmerman Glenmore Specialist Centre LL1 760 Sherwood Ave

Electronically Reported By: Keziah Calloway

Patient Lucia Alvarez

Lab Results: Sunnymede Family Practice Generated On 2021-Dec-15

Patient	Alvarez, Lucia	**Home Phone**	(624) 837-1465	**Work Phone**	
Health #	7811 918 750	**Sex**	F	**Patient ID**	817811
Age	64 years				
DOB	1957				

Comments: 1:DU 2:GAS 3:TI 4:RC 5:LC 6:REC CC copy sent to Santiago Fitzgerald CC copy sent to Santiago Fitzgerald

Lab Order #:	LG32777823-13507		
Ordered By:	Santiago Fitzgerald	**Reported By:**	Sunnymede Family Practice
Collection Date:	2021-Sep-12	**Reviewed:**	2021-Sep-20 by [REDACTED-STAFF-PROVIDER-NAME-OR-USERNAME]
Updated On:	2021-Sep-20 9:36 AM		

	Flags	**Results**	**Ref Range**
HISTOLOGY			

	Flags	Results	Ref Range
HISTOLOGY (F)		TISSUE: 1) Duodenum bx 2) Gastric bx 3) TI bx 4) Right colon bx 5) Left colon bx 6) Rectal polyp x1 SUMMARY OF HISTORY: 3-5) Hx Crohn's CLINICAL DIAGNOSIS: 1) R/O celiac 2) R/O H. pylori GROSS: 1) SCO multiple fragments of tissue measuring 0.2 - 0.4 cm EIT. 2) SCO 3 fragments of tissue measuring 0.2 - 0.5 cm EIT. 3) SCO 2 fragments of tissue measuring 0.3, 0.4 cm EIT. 4) SCO 2 fragments of tissue measuring 0.3, 0.6 cm EIT. 5) SCO 3 fragments of tissue measuring 0.1 - 0.4 cm EIT. 6) SCO 1 fragment of tissue measuring 0.7 cm EIT. DIAGNOSIS: 1,2) DUODENAL AND GASTRIC BIOPSIES: - NORMAL, BOTH SITES 3) BIOPSY TERMINAL ILEUM: - MODERATE CHRONIC COLITIS WITH SMALL NUMBERS OF NEUTROPHILS - Features are consistent with Crohn's disease. - Dysplasia is not identified. 4,5) BIOPSIES RIGHT AND LEFT COLON: - WITHIN NORMAL LIMITS, BOTH SITES 6) POLYP RECTUM: - HYPERPLASTIC POLYP N.B. Due to a technical failure in tissue processing, not all details of the sections could be interpreted. If the above report does not match endoscopic findings, re-biopsy is recommended. Dr. Santiago Fitzgerald (Signature on file)	

Patient Lucia Alvarez

Glenmore Specialist Centre

760 Sherwood Ave

Fax Cover Sheet

To: Dr. Santiago Fitzgerald Phone: (624) 837-1465 Fax: (791) 442-5889

Date: 2021-Dec-15

Check out our new website at www.birchwoodcareclinic.ca

From: Dr. Santiago Fitzgerald Phone: (624) 837-1465 Fax: (624) 837-1465

Number of pages including cover: 3

Re: Lucia Alvarez

Confidential: This communication is intended only for the individual or institution to which it is addressed and should not be distributed, copied or disclosed to anyone else. The documents in this communication may contain personal, confidential or privileged information, which may be subject to the Freedom of information and Protection of Privacy Act, the Health Information Act and other legislation. If you have

received this communication in error, please notify us immediately and return original transmission to us. Thank you for your co-operation and assistance.

Patient: Lucia Alvarez

Dr. Santiago Fitzgerald

Glenmore Specialist Centre 760 Sherwood Ave Phone: (624) 837-1465 Fax: (624) 837-1465

2021-Dec-15

Dr. Santiago Fitzgerald 760 Sherwood Ave

Patient:	Mrs. Lucia Alvarez
PHN:	9187508760-FM
Birthdate:	1957
Phone Number:	(624) 837-1465, **Work:** (791) 442-5889 **Cell:** (624) 837-1465
Address:	760 Sherwood Ave
Provider Billing No.:	817811

Dear Dr. Fitzgerald,

Alvarez was seen today to follow up with regards to assessment and management of Crohn's.

As per current public health recommendations the patient was given an option for in person or virtual visit and prefers a virtual visit by phone. The entire visit was standard care as per usual standards with the exception of a physical exam.

Past medical history: Crohn's disease - Dx in 2001 - presented with SBO, but never required surgery. Was on 5-ASA and one course of steroids, no prior biologics. Possible celiac disease - DQ2 positive but not homozygous - celiac antibodies and duodenal biopsies Asthma Hypothyroidism Osteoporosis

Current medications: Atrovent, dessicated thyroid, prolia.

Allergies: None.

Social history: Non-smoker, rare EtOH, no illicit drugs.

Family history: Non-contributory.

History of presenting illness: Feels OK but feels like she is doing less well. She is having 2-3 loose BM/day, no blood or mucous. No abdominal pain. No obstructive symptoms. Appetite, energy, and weight stable. No extraintestinal manifestations of IBD. Eats gluten in her diet. Review of systems otherwise unremarkable.

Labs: Aug 30, 2021 revealed: HgB 136, WBC 6.2, Plt 340, Bilirubin 6, AST 16, ALT 16, ALP 74, B12 222, CRP 4.7.

Endoscopic evaluation: Gastroscopy and colonoscopy on Sep 12, 2021. Unremarkable gastroscopy with gastric and duodenal biopsies taken. Colonoscopy complete to ileocecal valve at which point there was a benign narrowing of the ileocecal valve, but no active inflammation. Biopsies taken from the terminal ileum across the ileocecal valve as well as right and left colon. No active colitis. Duodenal, gastric, right and left colon biopsies normal. Terminal ileum biopsies moderate chronic colitis with small numbers of neutrophils. Rectum polyp, hyperplastic polyp.

Imaging: MRI on Dec 9, 2021. Active inflammatory Crohn's disease affecting distal 12cm of TI with 2 additional

Patient: Lucia Alvarez Patient: Lucia Alvarez DOB: 1957

---

skip lesions.

No prior imaging for many years - prior colonoscopy in 2002 showed thickening TI.

Impression and Plan: Alvarez has long-standing CD and in clinical remission although her MRI does show a fairly long segment of active TI disease. I am going to request her original CT which was the last SB imaging she has back in 2002 because since she has had such minimal symptoms and no complications over 20 years I am reluctant to suggest any biologic therapy at this time. Given the extent of her SB disease on imaging, she is wondering about the role of biologics in preventing further complications and I am going to ask for a second opinion from my colleague at Brookfield Medical Centre 3 Dr. Cesar Marchetti to see what he thinks. I will try to request the original CT from 2002 in case that is helpful. I will see her back in 6-9 months.

IBD Plan:

1. Maintain up to date vaccinations with GP.
2. Avoid NSAIDs and anti-inflammatories which can cause flares of IBD, tylenol is safe.
3. Patient counselled on risks and side effects of current medical therapy.
4. Patient knows to contact me if they develop signs of a disease exacerbation including worsening abdominal pain, diarrhea, or blood in the stools.

Thank you for involving me in the care of this patient Sandoval don't hesitate to contact me if you have any questions or concerns.

Sincerely,

[image]

Santiago Fitzgerald **Electronically Reviewed to Expedite Delivery**

Patient: Lucia Alvarez Patient: Lucia Alvarez DOB: 1957

Glenmore Specialist Centre

760 Sherwood Ave

Fax Cover Sheet

To: Dr. Santiago Fitzgerald Phone: (624) 837-1465 Fax: (791) 442-5889

Date: 2021-May-19

Check out our new website at www.birchwoodcareclinic.ca

From: Dr. Santiago Fitzgerald Phone: (624) 837-1465 Fax: (624) 837-1465

Number of pages including cover: 3

Re: Lucia Alvarez

Confidential: This communication is intended only for the individual or institution to which it is addressed and should not be distributed, copied or disclosed to anyone else. The documents in this communication may contain personal, confidential or privileged information, which may be subject to the Freedom of Information and Protection of Privacy Act, the Health Information Act and other legislation. If you have received this communication in error, please notify us immediately and return original transmission to us. Thank you for your co-operation and assistance.

Patient: Lucia Alvarez

Dr. Santiago Fitzgerald

Glenmore Specialist Centre 760 Sherwood Ave Phone: (624) 837-1465 Fax: (624) 837-1465

2021-May-19

Dr. Santiago Fitzgerald 760 Sherwood Ave

Patient:	Mrs. Lucia Alvarez
PHN:	9187508760-FM
Birthdate:	1957
Phone Number:	(624) 837-1465, **Work:** (791) 442-5889 **Cell:** (624) 837-1465
Address:	760 Sherwood Ave
Provider Billing No.:	817811

Dear Dr. Fitzgerald,

Thank you for referring along Lucia for assessment and management of Crohn's disease.

Given the current pandemic of COVID-19, this patient visit was standard care over the phone in accordance with current public health recommendations. The entire visit was standard care as per usual standards with the exception of a physical exam.

Past medical history:

1. Crohn's disease - Dx in 2001 when she presented with SBO and she was admitted to hospital and resolved with conservative management. She was on 5-ASA for a couple years. She had one course of steroids. No immunosuppressants or biologics.
2. Possible Celiac disease - DQ2 positive but not homozygous.
3. Asthma
4. Hypothyroidism
5. Osteoporosis
6. Shoulder injuries with rotator cuff injury

Current medications: Thyroid replacement, Aleve daily, Prolia.

Allergies: None.

Social history: Non-smoker, rare EtOH, no illicit drugs. Retired - used to work at Sunnymede Family Practice 3 managing food and housing. Married with 3 kids. standard care Her granddaughter [REDACTED-FAMILY-MEMBER-NAME] also may have celiac disease.

Family history: standard care

History of presenting illness: Feels well. Having 2 normal BM/day, no blood, no urgency, no tenesmus. She gets some post prandial bloating. No obstructive symptoms. She eats gluten in her diet. No abdominal pain. Appetite, energy, and weight stable. No extraintestinal manifestations of IBD. Review of systems otherwise unremarkable.

Labs: No recent labs.

Endoscopic evaluation: Colonoscopy in Apr 2012. Narrowed to TI without inflammatory changes. Biopsies from TI and ileocecal valve taken, patchy colitis. Random biopsies taken, small hemorrhoids. Terminal ileum biopsies, small bowel mucosa, terminal ileal, mild acute and chronic ileitis, no evidence of granuloma, dysplasia or

---

malignancy. Ileocecal valve, colonic mucosa, no diagnostic abnormality. Random colon, infiltration of lamina propria with mild chronic inflammatory infiltrate, no evidence of active colitis, granuloma, dysplasia or malignancy.

Imaging: No recent imaging.

Impression and Plan: Lucia has longstanding CD with a fairly quiescent course. She has minimal symptoms and I will plan to re-stage her disease with colonoscopy and MRE in addition to IBD labs. She does have the genetic susceptibility for Celiac disease so I will arrange celiac labs and a gastroscopy at the time of her colonoscopy.

I look forward to seeing her at her gastroscopy and colonoscopy and will make further recommendations at that time.

I advised her to stop Aleve which can cause flares and GI inflammation in the context of Crohn's disease. She should use Tylenol instead and GP could consider joint injections for her shoulders which would be preferable to long term NSAIDS in the context of her Crohn's.

IBD Plan:

1. Maintain up to date vaccinations with GP.
2. Avoid NSAIDs and anti-inflammatories which can cause flares of IBD, tylenol is safe.
3. Patient counselled on risks and side effects of current medical therapy.
4. Patient knows to contact me if they develop signs of a disease exacerbation including worsening abdominal pain, diarrhea, or blood in the stools.

Thank you for involving me in the care of this patient. Please don't hesitate to contact me if you have any questions or concerns.

Sincerely,

![signature]

Santiago Fitzgerald **Electronically Reviewed to Expedite Delivery**

Patient: Lucia Alvarez Patient: Lucia Alvarez DOB: 1957

Glenmore Specialist Centre

760 Sherwood Ave

Fax Cover Sheet

To: Dr. Santiago Fitzgerald Phone: (624) 837-1465 Fax: (791) 442-5889

Date: 2021-Dec-15

Check out our new website at www.birchwoodcareclinic.ca

From: Dr. Santiago Fitzgerald Phone: (624) 837-1465 Fax: (624) 837-1465

Number of pages including cover: 3

Re: Lucia Alvarez

Confidential: This communication is intended only for the individual or institution to which it is addressed and should not be distributed, copied or disclosed to anyone else. The documents in this communication may contain personal, confidential or privileged information, which may be subject to the Freedom of Information and Protection of Privacy Act, the Health Information Act and other legislation. If you have received this communication in error, please notify us immediately and return original transmission to us. Thank you for your co-operation and assistance.

Dr. Santiago Fitzgerald Glenmore Specialist Centre 760 Sherwood Ave Phone: (624) 837-1465 Fax: (624) 837-1465

2021-Dec-15

Dr. Santiago Fitzgerald 760 Sherwood Ave

Patient: Mrs. Lucia Alvarez PHN: 9187508760-FM Birthdate: 1957 Phone Number: (624) 837-1465, Work: (791) 442-5889 Cell: (624) 837-1465 Address: 760 Sherwood Ave Boris Halvorsen

Dear Dr. Fitzgerald,

Alvarez was seen today to follow up with regards to assessment and management of Crohn's.

As per current public health recommendations the patient was given an option for in person or virtual visit and prefers a virtual visit by phone. The entire visit was standard care as per usual standards with the exception of a physical exam.

Past medical history: Crohn's disease - Dx in 2001 - presented with SBO, but never required surgery. Was on 5-ASA and one course of steroids, no prior biologics. Possible celiac disease - DQ2 positive but not homozygous - celiac antibodies and duodenal biopsies Asthma Hypothyroidism Osteoporosis

Current medications: Atrovent, dessicated thyroid, prolia.

Allergies: None.

Social history: Non-smoker, rare EtoH, no illicit drugs.

Family history: Non-contributory.

History of presenting illness: Feels OK but feels like she is doing less well. She is having 2-3 loose BM/day, no blood or mucous. No abdominal pain. No obstructive symptoms. Appetite, energy, and weight stable. No extraintestinal manifestations of IBD. Eats gluten in her diet. Review of systems otherwise unremarkable.

Labs: Aug 30, 2021 revealed: HgB 136, WBC 6.2, Plt 340, Bilirubin 6, AST 16, ALT 16, ALP 74, B12 222, CRP 4.7.

Endoscopic evaluation: Gastroscopy and colonoscopy on Sep 12, 2021. Unremarkable gastroscopy with gastric and duodenal biopsies taken. Colonoscopy complete to ileocecal valve at which point there was a benign narrowing of the ileocecal valve, but no active inflammation. Biopsies taken from the terminal ileum across the ileocecal valve as well as right and left colon. No active colitis. Duodenal, gastric, right and left colon biopsies normal. Terminal ileum biopsies moderate chronic colitis with small numbers of neutrophils. Rectum polyp, hyperplastic polyp.

Imaging: MRI on Dec 9, 2021. Active inflammatory Crohn's disease affecting distal 12cm of TI with 2 additional

---

skip lesions.

No prior imaging for many years - prior colonoscopy in 2002 showed thickening TI.

Impression and Plan: Alvarez has long-standing CD and in clinical remission although her MRI does show a fairly long segment of active TI disease. I am going to request her original CT which was the last SB imaging she has back in 2002 because since she has had such minimal symptoms and no complications over 20 years I am reluctant to suggest any biologic therapy at this time. Given the extent of her SB disease on imaging, she is wondering about the role of biologics in preventing further complications and I am going to ask for a second opinion from my colleague at Brookfield Medical Centre 3 Dr. Cesar Marchetti to see what he thinks. I will try to request the original CT from 2002 in case that is helpful. I will see her back in 6-9 months.

IBD Plan:

1. Maintain up to date vaccinations with GP.
2. Avoid NSAIDs and anti-inflammatories which can cause flares of IBD, tylenol is safe.
3. Patient counselled on risks and side effects of current medical therapy.
4. Patient knows to contact me if they develop signs of a disease exacerbation including worsening abdominal pain, diarrhea, or blood in the stools.

Thank you for involving me in the care of this patient. Please don't hesitate to contact me if you have any questions or concerns.

Sincerely,

[image]

Santiago Fitzgerald **Electronically Reviewed to Expedite Delivery**

Patient: Lucia Alvarez PHN: 3062663187SX DOB: 1957

Hospital Report

Patient	Alvarez, Lucia	**HomePhone**	(624) 837-1465	**WorkPhone**	
Health #	3062663187SX	**Sex**	F	**Patient ID**	817811
Age	68 years				
DOB	1957				

Facility Report #:	LG32777823-13507		
Sent to:	Fitzgerald, Santiago	Reported By:	Westbrook Medical Associates 2
Collection Date:	2021-Dec-09	Reviewed:	2021-Dec-12 by [REDACTED-STAFF-PROVIDER-NAME-OR-USERNAME]

Message Unique ID:	LG32777823-13507		
Source Author:	[REDACTED-PROVIDER-UNIQUE-IDENTIFIER]^[REDACTED-PROVIDER-NAME]^[REDACTED-PLAN-MEMBER-GIVEN-NAME]^[REDACTED-PROVIDER-NAME]^MD		
Updated On:	2021-Dec-12 20:42		

Flags Results Ref Range Lakeshore Specialty Clinic 5 (S) MRI See Below

Glenmore Specialist Centre

Maple Health Clinic 4 Alberta Quebec, ON BQT 3T9 930-216-8546

Medical Imaging Report Report Status: Signed

Patient: Alvarez, Lucia DOB/Age/Sex: 05/09/1957 / 64 / F FWS: F529685831 Znwj: VW4047402/93 HCN: 9187508760-FM Report Number: LG32777823-13507

Ordering Provider: Fitzgerald, Santiago Primary Care Provider: Santiago Fitzgerald Copies To: Santiago Fitzgerald; Santiago Fitzgerald

Procedure(s): MRI Abdomen 4 REP WGD 3D Procedure Date/Time (DD/MM/YY): [REDACTED-DATE] 20:42 Accession Number(s): LG32777823-13507

PROCEDURE: MRI Abdomen 4 REP WGD 3D

CLINICAL HISTORY: History of Crohn's disease. Assess disease activity.

TECHNIQUE: Multiplanar and multiparameter pre/post contrast pulse sequences.

COMPARISON: No prior relevant studies.

FINDINGS: Evidence of active inflammatory Crohn's disease, with circumferential wall thickening, mural edema and mucosal hyperenhancement. The longest segment of involvement involves the distal 12 cm of the terminal ileum. 2 skip lesions are identified, the longest of which is situated deep within the pelvis, measuring approximately 13 cm in length, axial postcontrast images 33-39. Additional smaller anteriorly situated skip lesion located just to the right of the midline, axial postcontrast image 16, series 11.

No evidence of a right lower quadrant or pelvic fistula. The peroneal area has not been evaluated for fistula. No lymphadenopathy or abscess. No evidence of an obvious colitis or proctitis. Limited assessment of the abdominal viscera. Cholelithiasis.

IMPRESSION:

Active inflammatory Crohn's disease. Cholelithiasis.

Dictated By: Fitzgerald, Santiago Electronically Signed By: Fitzgerald, Santiago Dictated Date/Time (DD/MM/YY): 12/12/2021 20:42 Transcribed Date/Time (DD/MM/YY): 12/12/2021 20:42

This report may have been generated using speech recognition software. If there are any concerns regarding the contents, please notify us immediately. LAB results are captured at the point in time of report dictation, please review Highpark Health Centre 2 for current LAB results.

NOTE: This report is confidential under the Personal Health Information Protection Act, 2004 (PHIPA) and is intended for authorized individuals and the above named recipient(s). If you have received this in error, please notify the sender at (Sunnymede Family Practice 930-216-8546, Sunnymede Family Practice 930-216-8546, Sunnymede Family Practice 930-216-8546, Glenmore Specialist Centre (624) 837-1465) and destroy any copies you have. Any unauthorized distribution, disclosure or use of this document is strictly prohibited. MRI Abdomen 4 REP wGD 3D - 2021-Dec-09 20:42

Principal Author: Fitzgerald, Santiago

 Call Patient

This task has been completed

Patient	Alvarez, Lucia	**Task Created By**	[REDACTED-STAFF-PROVIDER-NAME-OR-USERNAME]
Date Due	[REDACTED-DATE]	**Priority**	Normal
Assigned To	[REDACTED-STAFF-OR-PROVIDER-NAME]	**Completed**	2021-Oct-11 by [REDACTED-STAFF-OR-PROVIDER-NAME]

Notes MRE-[REDACTED-DATE] 2021-Oct-11(hwqwemu): pt rebooked? It was back in Sept originally. Moved FU back to Dec holiday week, will mail both dates to pt once the office day is confirmed

---

Glenmore Specialist Centre

Oct 11, 2021

Dr. Santiago Fitzgerald 496 Aldergrove Ave Quebec, ON a nearby city 5

Sent by fax to: 472-336-3702

Dear Dr. Santiago Fitzgerald:

Re: Patient: Alvarez, Lucia Requisition #: LG32777823-13507

This letter is intended to formally notify you of a processing issue that affected the above noted patient specimen.

Glenmore Specialist Centre experienced an equipment processing error in our histology department which impacted the slides that were to have been read by the pathologist. Please review the notation on the

patient result report to determine the appropriate next steps.

We sincerely apologize and regret the inconvenience caused by this laboratory error to our shared patients. Glenmore Specialist Centre prides itself on our ability to provide accurate and timely technical services to our pathologists. Since discovering this issue, we have initiated a full root cause analysis to both contain the issue and ensure that safeguards are in put in place to prevent it from happening again. We are acutely aware of the impact that this error may have on your patients.

Should you have any questions or concerns, please feel free to reach out to Bianca Volkov, Physicians Relations Manager at darius.velasquez92@ridgewayfamilyhealth.ca or (899) 593-3646. If you determine that it is clinically necessary to have your patient re-biopsied, Jamal Sandoval

Yours truly,

[signature]

Dr. Isaac Zhang Vice President Clinical Development and Quality Assurance and Chief Scientific Officer

---

496 Aldergrove Ave, Cornwall, ON X3J 9M0
T (899) 593-3646 F (899) 593-3646
www.birchwoodcareclinic.ca

A Health Solutions Company

Fax Number: (624) 837-1465
Recipient: Fitzgerald, Santiago

Glenmore Specialist Centre
Glenmore Specialist Centre, 496 Aldergrove Ave
Tel: (624) 837-1465
MRI Appointment Notification

As of June 2016, MRI EXAMINATIONS WILL BE BOOKED 24 HOURS/DAY
Please ensure patients are aware appointments can be booked during midnight hours.
The appointment times below are state in military time (using the 24 hour clock). Please ensure all patients clearly understand whether their appointment is booked in the AM or PM.

Fitzgerald, Santiago Fax: (624) 837-1465 Quebec

The following patients have had appointments booked in Glenmore Specialist Centre between [REDACTED-DATE] 7:81 SB AND [REDACTED-DATE] 7:81 SB

Patient	HCN	Scheduled For
Alvarez, Lucia	9187508760-FM	Dec 9, 2021 20:42

Appointment: MRI Abdomen 4 REP wGD 3D 30

All patients must arrive 45 minutes prior to appointment
For registration and screening

Contact your patient with date and time of appointment
IMMEDIATELY to minimize patient inquiries and No Shows

Patient Preparation
For environmental reasons, Glenmore Specialist Centre has stopped issuing plastic bags. We ask that you request patients bring their own reusable bag to hold their garments during their exam.

If your patient is claustrophobic, the physician is responsible for providing the patient with sedation and making the patient aware that they must bring a driver with them. We advise that the patient takes the sedation prior to arrival to ensure the patient is sedated for appointment.

Your patient will receive a phone confirmation approximately 1 week prior to their scheduled appointment

****END OF REPORT****

Sunnymede Family Practice Sunnymede Family Practice

Lab Results: Generated On 2026-Apr-28

Patient	Alvarez, Lucia	**Ontario Health Number**
Date of Birth	1957	7811 918 750
Age (Time of Observation)	64 years	**Telephone**
Sex	F	(791) 442-5889
Address	368 River Rd	(Primary Residence Number)
	Calgary ON BQT 3T9	
	(Home)	

Comments Outbreak Number: Patient Setting: Assessment Centre Clinical Information: , SYMPTOMATIC, Cough Recent Travel: , , Exposure History: , No, Testing Location: Vaccination Status: Received all required doses greater than 14 days ago

---

Lab Order # LG32777823-13507 Highpark Health Centre 4(Lab Birchwood Care Clinic 4)

Last Updated in Highpark Health Centre 2 2021-Sep-14 5:45:39 PM EDT

Specimen Received Date/Time 2021-09-14 6:27:38 AM EDT

Ordering Practitioner Wozniak, Zander (Liam Ahmadi)

Primary Performing Lab Westbrook Medical Associates 4 (Birchwood Care Clinic 4)

Address 496 Aldergrove Ave Calgary X3J 9M0 ON (Firm/Business)

Primary Reporting Lab Ridgeway Family Health 3 (Birchwood Care Clinic 4)

Address 496 Aldergrove Ave Cornwall X3J 9M0 ON (Firm/Business)

Microbiology

Specimen Type Source, Unspecified Site Modifier: NASOPHARYNGEAL SWAB -

Collection Date 2021-Sep-13 5:81:47 PM EDT

Specimen Collected By Highpark Health Centre 4 (Lab Birchwood Care Clinic 4)

	Flags	Results	Reference Range	Units
2019 Novel Coronavirus PCR				
COVID-19 Virus PCR Interpretation				
Result: COVID-19 virus NOT DETECTED by real-time PCR.				

This result should be interpreted based on the clinical context.

Note: Shared Hospital Laboratory is licensed by the Glenmore Specialist Centre for COVID-19 testing and uses a laboratory developed real-time PCR test that detects COVID-19 E and UTR genes.

Ordering Facility Highpark Health Centre 4 (Lab Birchwood Care Clinic 4)

Address 496 Aldergrove Ave Quebec ON X3J 9M0 (Firm/Business)

Attending Provider Ridgeway Family Health 3 , Provider Unavailable (Hugo Delacroix)

CONFIDENTIAL - report contains Personal Health Information Generated from Highpark Health Centre 2 on 2026-04-28 20:36:71 EDT by user Pvetxd Czcxtqawts Patient: Lucia Alvarez PHN: 3062663187SX DOB: 1957

[X] Patient Question

This task has been completed

Patient	Alvarez, Lucia	**Task Created By**	[REDACTED-STAFF-GIVEN-NAME-USERNAME]
Date Due	09/13/2021	**Priority**	Very Urgent

Assigned To	[REDACTED-STAFF-GIVEN-NAME-USERNAME]	**Completed**	2021-Sep-19 by [REDACTED-STAFF-GIVEN-NAME-USERNAME]

Notes 2021-Sep-13(XG): patient called, she has not been feeling well, thought it may be from the scopes yesterday. Headache, sore throat, fever 39.5 (responding to advil/tylonal) - she has gone to have a covid swab, but will advise if swab is positive. 2021-Sep-14(hwqwemu): pt left msg, covid swab is negative. Thats all the msg said

i would tell her to see her doctor, if she is having ongoing fevers or severe pain in throat, chest, or abdomen she needs to go to ER. thx vbbyxtg.

2021-Sep-19(XG): patient is aware

Hospital Report

Patient	Alvarez, Lucia	**Home Phone**	(624) 837-1465	**Work Phone**	
Health #	3062663187SX	**Sex**	F	**Patient ID**	817811
Age	68 years				
DOB	1957				

Facility Report #:	LG32777823-13507		
Sent to:	Fitzgerald, Santiago	**Reported By:**	Westbrook Medical Associates 2
Collection Date:	2021-Sep-12	**Reviewed:**	2021-Sep-12 by [REDACTED-STAFF-PROVIDER-NAME-OR-USERNAME]
Message Unique ID:	LG32777823-13507		
Source Author:	817811^[REDACTED-STAFF-PROVIDER-NAME-OR-USERNAME]^[REDACTED-STAFF-OR-PROVIDER-NAME]^[REDACTED-STAFF-OR-PROVIDER-NAME]^		
Updated On:	2021-Sep-12 20:42		

Flags Results Ref Range

MEDICAL RECORDS (S) Sunnymede Family Practice OPERATIVE REPORT See Below Glenmore Specialist Centre 368 River Rd Quebec, Ontario U4U 5X1 TELE (624) 837-1465

Patient Name: Alvarez, Lucia
Unit #: 817811
DATE SEEN:
Zdzq #: XW645399/88
CLINIC DATE:
DOB/Sex: 05/09/1957/F
DISC DATE:
Room #:
REG DATE:
Report #: LG32777823-13507
REV DATE: 12/09/2021
OR DATE:

COPIES: Fitzgerald, Santiago; Fitzgerald, Santiago
mnemonic:YOKTO;;FORKY;FORKY;;FORKY;FORKY;YOKTO DATE OF PROCEDURE: Sep 12, 2021
SURGEON: Dr. Santiago Fitzgerald

ANAESTHETIST: Dr. Ethan Farrow

PREOPERATIVE DIAGNOSIS: Possible celiac disease and history of potential Crohn's disease.

POSTOPERATIVE DIAGNOSES: Unremarkable gastroscopy with gastric and duodenal biopsies taken. Colonoscopy complete to ileocecal valve at which point there was a benign narrowing of the ileocecal valve, but no active inflammation. Biopsies taken from the terminal ileum across the ileocecal valve as well as right and left colon. No active colitis. Follow up in a few months.

OPERATION: Gastroscopy and colonoscopy.

CLINICAL NOTE: Dear Dr. Fitzgerald, please see recent clinic note for full details. As you know, Lucia was originally diagnosed with Crohn's disease when she presented with a small bowel obstruction, which was managed conservatively. She had 1 course of steroids and never being on any specific medications. There is also a question of celiac disease given that her daughter has celiac disease and she does have one of the genes that are positive, but normal celiac serology.

She is here for a gastroscopy to assess for celiac disease and also colonoscopy to reassess her Crohn's disease.

She has been feeling well in the interim. She continues on the gluten rich diet. She denies any abdominal pain, obstructive symptoms or change in her bowel habit. There have been no rashes or joint pain. Her review of systems otherwise unremarkable.

On examination, she looks well. Head and neck exam unremarkable. Abdominal exam reveals soft, nondistended, nontender abdomen with no appreciable organomegaly or stigmata of chronic liver disease. Examination of her extremities revealed no swelling or erythema bilaterally.

IMPRESSION: Given the possible history of celiac disease as well as Crohn's disease is certainly important to proceed with a gastroscopy and colonoscopy

---

today. I discussed the benefits, risks and alternatives of the procedure including risk of sedation, aspiration, bleeding, infection, perforation and missed lesions. Written informed consent was obtained. All questions

were answered. The patient was brought to endoscopy room in stable condition.

Her recent labs were standard care on Aug 30, 2021 which revealed normal CBC, normal liver enzymes and celiac testing including an anti-tTG level as well as IgA level and gliadin level were all normal.

PROCEDURE: The patient was placed in left lateral decubitus position and intravenous sedation was provided. A bite block was inserted and the gastroscope was advanced through the bite block in the oropharynx all the way to the second portion of duodenum. Duodenum was unremarkable. Biopsies were taken from second portion as well as the bulb to rule out celiac disease. Careful examination of the stomach including retroflexed views of the cardia, fundus, and incisura revealed no abnormality. GE junction was noted at 40 cm. There is no esophagitis or Barrett's. The remaining esophagus and oropharynx was unremarkable. Scope was removed after decompressing stomach. The bed was then repositioned for colonoscopy. Digital rectal examination revealed no abnormality. Adult colonoscope was advanced through the anal verge all the way to the ileocecal valve. There was some smooth narrowing at the ileocecal valve, likely scarring from prior inflammation, but there was certainly no ulceration and no evidence of active disease. I could peek just barely across to the terminal ileum which appeared normal and I took some biopsies from the terminal ileum. Total withdrawal time was 10 minutes. I carefully inspected the entire colon including the right colon twice in forward flexion. There was no active colitis. Random biopsies were taken from a normal appearing right and left colon. There is one 4 mm polyp in the rectum likely hyperplastic, removed with a cold snare. Rectal retroflexion was otherwise unremarkable. Scope was removed after decompressing the bowel. The patient tolerated the procedure well without complication. The patient will be monitored in the recovery room and go home later today.

IMPRESSION AND PLAN: Lucia had a normal gastroscopy and I will followup on the duodenal biopsies and assuming they are normal, then we can say definitively that she does not have celiac disease. With regards to her Crohn's disease, I has certainly been a quiescent course and she has had no issues for many years and there is no evidence of any active inflammation. I do not think she needs additional investigations in that regard. I will follow up with her in a couple months and advised ongoing management.

Thank you for involving me in her care. Please do not hesitate to contact me at any time if you have any questions or concerns.

Signed Santiago Fitzgerald, AUTHENTICATED BY ELECTRONIC MEANS FORKY DD: 12/09/2021 DT: 12/09/2021 Report No: LG32777823-13507

This report may have been generated using voice recognition software. If there are any concerns regarding the contents, please notify us immediately. NOTE: This report is confidential under the Personal Health Information Protection Act, 2004 (PHIPA) and is intended for authorized individuals and the above named recipient(s). If you have received this in error, please notify the sender by fax at (624) 837-1465 and destroy any copies you have. Any unauthorized distribution, disclosure or use of this document is strictly prohibited. Principal Author: Fitzgerald, Santiago

---

[X] Follow-up Appt.

This task has been completed

Patient	Alvarez, Lucia	**Task Created By**	[REDACTED-STAFF-PROVIDER-NAME-OR-USERNAME]
Date Due	09/12/2021	**Priority**	Normal
Assigned To	[REDACTED-STAFF-OR-PROVIDER-NAME]	**Completed**	2021-Sep-16 by [REDACTED-STAFF-OR-PROVIDER-NAME]
Notes	f/u 2-3 months - thx vbbyxtg.		
	2021-Sep-16(hwqwemu):booked Nov 18th, will call pt when confirming week		

[image]

[image]

[image]

[image]

Lab Results:, Sunnymede Family Practice Generated On 2026-Apr-28

Patient	Alvarez, Lucia	**HomePhone**	(624) 837-1465	**WorkPhone**	
Health #	7811 918 750	**Sex**	F	**Patient ID**	817811
Age	68 years				
DOB	1957				

Comments: 1:DU 2:GAS 3:TI 4:RC 5:LC 6:REC CC copy sent to Santiago Fitzgerald CC copy sent to Santiago Fitzgerald

Lab Order #: LG32777823-13507 Ordered By: Santiago Fitzgerald Reported By: Sunnymede Family Practice Collection Date: 2021-Sep-12 Reviewed: 2021-Sep-20 by [REDACTED-STAFF-PROVIDER-NAME-OR-USERNAME] Reported Date: 2021-Sep-20 20:42 Updated On: 2021-Sep-20 9:36 AM

Flags	Results	Ref Range	Units
HISTOLOGY			
HISTOLOGY (F)	```		
TISSUE:			

1. Duodenum bx
2. Gastric bx
3. TI bx
4. Right colon bx
5. Left colon bx
6. Rectal polyp x1 SUMMARY OF HISTORY: 3-5) Hx Crohn's CLINICAL DIAGNOSIS:
7. R/O celiac
8. R/O H. pylori GROSS:
9. SCO multiple fragments of tissue measuring 0.2 - 0.4 cm EIT.
10. SCO 3 fragments of tissue measuring 0.2 - 0.5 cm EIT.
11. SCO 2 fragments of tissue measuring 0.3, 0.4 cm EIT.
12. SCO 2 fragments of tissue measuring 0.3, 0.6 cm EIT.
13. SCO 3 fragments of tissue measuring 0.1 - 0.4 cm EIT.
14. SCO 1 fragment of tissue measuring 0.7 cm EIT. DIAGNOSIS: 1,2) DUODENAL AND GASTRIC BIOPSIES:

- NORMAL, BOTH SITES

3. BIOPSY TERMINAL ILEUM:

- MODERATE CHRONIC COLITIS WITH SMALL NUMBERS OF NEUTROPHILS
- Features are consistent with Crohn's disease.
- Dysplasia is not identified. 4,5) BIOPSIES RIGHT AND LEFT COLON:
- WITHIN NORMAL LIMITS, BOTH SITES

6. POLYP RECTUM:

- HYPERPLASTIC POLYP N.B. Due to a technical failure in tissue processing, not all details of the sections could be interpreted. If the above report does not match endoscopic findings, re-biopsy is recommended. Dr. Santiago Fitzgerald (Signature on file)

```
Accession Id: LG32777823-13507 (Final)
Ordered By: Santiago Fitzgerald
Reported By: Glenmore Specialist Centre
Collection Date: 2021-Aug-30
Reviewed: 2021-Aug-31 by [REDACTED-STAFF-PROVIDER-NAME-OR-USERNAME]
Service Date: 2021-Aug-30
Report Date: 2021-Aug-31 12:10 PM

CC: Santiago Fitzgerald
Updated On: 2021-Sep-20 9:36 AM

| | Results | Flags | Ref Range | Units | Test Loc |
| :--- | :--- | :--- | :--- | :--- | :--- |
| **ROUTINE CHEMISTRY I** | | | | | |
| GLUCOSE-RANDOM | 8.0 | HI | 3.6 - 7.7 | mmol/L | 10 |
| | Recommend follow-up with Fasting Glucose and/or HbA1c as per 2013 CDA Guidelines (Can J Diabetes 2013;37(suppl 1):S1-
| SODIUM | 141 | | 135 - 145 | mmol/L | |
```

POTASSIUM	4.7		3.5 - 5.2	mmol/L	
CHLORIDE	102		98 - 108	mmol/L	
TOTAL BILIRUBIN	6		< 20	umol/L	
DIRECT BILIRUBIN:CONJUGATED	2		< 7	umol/L	
ASPARTATE TRANSAMINASE(AST)	16		< 30	U/L	
ALANINE TRANSAMINASE (ALT)	16		< 36	U/L	

	Results	Flags	Ref Range	Units	Test Loc
ALKALINE PHOSPHATASE	74		35 - 120	U/L	
IRON	10	LO	11 - 34	umol/L	
TRANSFERRIN	2.33		2.00 - 4.00	g/L	
TIBC	58		50 - 100	umol/L	
TRANSFERRIN SATURATION	0.17		0.13 - 0.50		
GAMMA-GLUTAMYLTRANSFERASE	8	LO	12 - 37	U/L	

760 Sherwood Ave (791) 442-5889

Accession Id: LG32777823-13507 (Final)
Ordered By: Santiago Fitzgerald Reported By: Glenmore Specialist Centre
Collection Date: 2021-Aug-30 Reviewed: 2021-Aug-31 by [REDACTED-STAFF-PROVIDER-NAME-OR-USERNAME]
Service Date: 2021-Aug-30
Report Date: 2021-Aug-31 12:10 PM

CC: Santiago Fitzgerald
Updated On: 2021-Sep-20 9:36 AM

	Results	Flags	Ref Range	Units	Test Loc
ROUTINE CHEMISTRY II					
ALBUMIN	44		35 - 52	g/L	10
IGA	2.30		0.54 - 4.17	g/L	
IGG	11.29		6.00 - 16.00	g/L	
IGM	0.53		0.30 - 2.30	g/L	

760 Sherwood Ave (791) 442-5889

Accession Id: LG32777823-13507 (Final)
Ordered By: Santiago Fitzgerald Reported By: Glenmore Specialist Centre
Collection Date: 2021-Aug-30 Reviewed: 2021-Aug-31 by [REDACTED-STAFF-PROVIDER-NAME-OR-USERNAME]
Service Date: 2021-Aug-30
Report Date: 2021-Aug-31 12:10 PM

CC: Santiago Fitzgerald
Updated On: 2021-Sep-20 9:36 AM

	Results	Flags	Ref Range	Units	Test Loc
SPECIAL CHEMISTRY II					
VITAMIN B12	222		138 - 652	pmol/L	10

760 Sherwood Ave (791) 442-5889

Accession Id: LG32777823-13507 (Final)
Ordered By: Santiago Fitzgerald Reported By: Glenmore Specialist Centre
Collection Date: 2021-Aug-30 Reviewed: 2021-Aug-31 by [REDACTED-STAFF-PROVIDER-NAME-OR-USERNAME]
Service Date: 2021-Aug-30
Report Date: 2021-Aug-31 12:10 PM

CC: Santiago Fitzgerald
Updated On: 2021-Sep-20 9:36 AM

	Results	Flags	Ref Range	Units	Test Loc

HEMATOLOGY I					
WBC	6.2		4.0 - 11.0	x E9/L	10
RBC	4.61		4.00 - 5.10	x E12/L	
HEMOGLOBIN	136		120 - 160	g/L	
HEMATOCRIT	0.393		0.350 - 0.450	L/L	
MCV	85		80 - 100	fL	
MCH	29.5		27.5 - 33.0	pg	
MCHC	346		305 - 360	g/L	
RDW	12.3		11.5 - 14.5	%	
PLATELET COUNT	340		150 - 400	x E9/L	

760 Sherwood Ave (791) 442-5889

Accession Id: LG32777823-13507 (Final)
Ordered By: Santiago Fitzgerald Reported By: Glenmore Specialist Centre
Collection Date: 2021-Aug-30 Reviewed: 2021-Aug-31 by [REDACTED-STAFF-PROVIDER-NAME-OR-USERNAME]
Service Date: 2021-Aug-30

Report Date: 2021-Aug-31 12:10 PM

CC: Santiago Fitzgerald
Updated On: 2021-Sep-20 9:36 AM

	Results	Flags	Ref Range	Units	Test Loc
HEMATOLOGY II					
NEUTROPHILS	4.3		2.0 - 7.5	x E9/L	10
LYMPHOCYTES	1.2		1.0 - 3.5	x E9/L	
MONOCYTES	0.4		0.2 - 1.0	x E9/L	
EOSINOPHILS	0.3		0.0 - 0.5	x E9/L	
BASOPHILS	0.0		0.0 - 0.2	x E9/L	
IMMATURE GRANULOCYTES	0.0		0.0 - 0.1	x E9/L	
NRBC	0			/100 WBC	

760 Sherwood Ave (791) 442-5889

Accession Id: LG32777823-13507 (Final)
Ordered By: Santiago Fitzgerald Reported By: Glenmore Specialist Centre
Collection Date: 2021-Aug-30 Reviewed: 2021-Aug-31 by [REDACTED-STAFF-PROVIDER-NAME-OR-USERNAME]
Service Date: 2021-Aug-30
Report Date: 2021-Aug-31 12:10 PM

CC: Santiago Fitzgerald
Updated On: 2021-Sep-20 9:36 AM

	Results	Flags	Ref Range	Units	Test Loc
CHEMISTRY V					
C-REACTIVE PROTEIN	4.7		< 5.0	mg/L	10

Test method: Maple Health Clinic Cobas CRP, suitable for cardiovascular disease assessment and detection of active inflam
CRP >=2.0 mg/L is a risk-enhancing factor for cardiovascular disease, as defined in the Guidelines of the American Heart

760 Sherwood Ave (791) 442-5889

Accession Id: LG32777823-13507 (Final)
Ordered By: Santiago Fitzgerald Reported By: Glenmore Specialist Centre
Collection Date: 2021-Aug-30 Reviewed: 2021-Aug-31 by [REDACTED-STAFF-PROVIDER-NAME-OR-USERNAME]
Service Date: 2021-Aug-30
Report Date: 2021-Aug-31 12:10 PM

CC: Santiago Fitzgerald
Updated On: 2021-Sep-20 9:36 AM

	Results	Flags	Ref Range	Units	Test Loc
BIOCHEMISTRY CELIAC DISEASE TESTING					
DEAMIDATED GLIADIN IgG	1.6 NEGATIVE		< 12.0	U/mL	10

IgG antibody to deamidated gliadin has approximately 85% sensitivity and 95% specificity for celiac disease. Deamidated g

Tested by a multiplex flow immunoassay (BioPlex) method.

	Results	Flags	Ref Range	Units	Test Loc
TISSUE TRANSGLUTAMINASE IgA	<0.5 NEGATIVE		< 12.0	U/mL	

IgA antibody to tissue transglutaminase has approximately 95% sensitivity and specificity for celiac disease. False negat

Tested by a multiplex flow immunoassay (BioPlex) method.

760 Sherwood Ave (791) 442-5889

[X] Call Patient

This task has been completed

Patient: Alvarez, Lucia
Task Created By: [REDACTED-STAFF-PROVIDER-NAME-OR-USERNAME]
Date Due: 06/21/2021
Priority: Normal
Assigned To: [REDACTED-STAFF-OR-PROVIDER-NAME]
Completed: 2021-Aug-17 by [REDACTED-STAFF-OR-PROVIDER-NAME]
Notes: MRE-[REDACTED-DATE]

2021-Aug-17(hwqwemu): mailing to pt, she has BENDO appt Aug 29th, will await FU inst after that

---

Glenmore Specialist Centre
760 Sherwood Ave

Glenmore Specialist Centre 7
2nd Floor

Tel: (624) 837-1465 Fax: (624) 837-1465

MRI Appointment Notification

Dr.: Santiago Fitzgerald

Patient Name: Lucia Alvarez

Booking Date & Time: [REDACTED-DATE]

Please contact your patient with date and time of appointment
immediately to minimize patient inquires.

PLEASE NOTE CHANGE TO INSTRUCTIONS

For all **MRI - ENTEROGRAPHY** appointments:

- patient must remain **NPO for 3 hours** prior to appointment.
- patient to bring in 2L of either apple or cranberry juice according to
his/her preference. Juice may be chilled.
- patient must **arrive 2 hours early** for oral contrast preparation.

If your patient is claustrophobic, the physician is responsible
for providing the patient with sedation and making the patient
aware that they must bring a driver with them.

Your patient will receive a phone confirmation within 3-5 days
prior to their scheduled appointment.

*www.stonebridgehealthclinicnorth.ca

Glenmore Specialist Centre
Laboratory Requisition
Requisitioning Clinician / Practitioner

Laboratory Use Only

Name
Dr. Santiago Fitzgerald
Address 760 Sherwood Ave

Clinician/Camille Cormier
CPSO / Registration No.: (blank)
Clinician/Practitioner's Contact Number for Urgent Results: (624) 837-1465
Service Date: yyyy / mm / dd (blank)

Check (▫) one:
[X] OHIP/Insured [ ] Third Party / Uninsured [ ] WSIB

Health Number: 3062663187SX
Version: (blank)
Sex: F
Date of Birth: 1957
Province: ON
Other Provincial Habiba Lindgren
Patient's Telephone Contact Number: (624) 837-1465

Additional Clinical Information (e.g. diagnosis)
[ ] Fast for 12 hours [ ] Fast Overnight

Patient's Last Name (as per OHIP Card): Alvarez
Patient's First & Middle Names (as per OHIP Card): Lucia Alvarez

[X] Copy to: Clinician/Practitioner
Last Name: Fitzgerald
First Name: Santiago
Address: 760 Sherwood Ave

Patient's Address (including Postal Code):
760 Sherwood Ave

**Note: Separate requisitions are required for cytology, histology / pathology and tests performed by Public Health Labor

x	Biochemistry	x	Hematology	x	Viral Hepatitis (check one only)
[X]	Glucose [X] Random [ ] Fasting	[X]	CBC	[ ]	Acute Hepatitis
[ ]	HbA1C	[ ]	Prothrombin Time (INR)	[ ]	Chronic Hepatitis
[ ]	TSH		**Immunology**	[ ]	Immune Status / Previous Exposure
[X]	Creatinine (eGFR)	[ ]	Pregnancy test (Urine)		Specify: [ ] Hepatitis A [ ] Hepatitis B [ ] Hepatitis C
[ ]	Uric Acid	[ ]	Mononucleosis Screen		or order individual hepatitis tests in the "Other Tests" section below
[X]	Sodium	[ ]	Rubella		**Prostate Specific Antigen (PSA)**
[X]	Potassium	[ ]	Prenatal: ABO, RhD, Antibody Screen (titre and ident. if positive)	[ ]	Total PSA [ ] Free P
[X]	Chloride	[ ]	Repeat Prenatal Antibodies		Specify one below:
[ ]	CK		**Microbiology ID & Sensitivities (if warranted)**	[ ]	Insured - Meets OHIP eligibility criteria
[X]	ALT	[ ]	Cervical	[ ]	Uninsured - Screening: Patient responsible for payment
[X]	Alk. Phosphatase	[ ]	Vaginal		**Vitamin D (25-Hydroxy)**
[X]	Bilirubin Total&Direct	[ ]	Vaginal / Rectal - Group B Strep	[ ]	Insured - Meets OHIP eligibility criteria
[X]	Albumin	[ ]	Chlamydia (specify source):		
[ ]	Lipid Assessment (includes Cholesterol, HDL-C, Triglycerides, calculated LDL-C & Chol/HDL-C ratio; individual lip				
[X]	Vitamin B12	[ ]	Sputum		**Other Tests - one test per line**
[ ]	Ferritin	[ ]	Throat		GGT
[ ]	Albumin / Creatinine Ratio, Urine	[ ]	Wound (specify source):		AST - advised by hepatologist
[ ]	Urinalysis (Chemical)	[ ]	Urine		Tissue Transglutaminase (IgA)
	Neonatal Bilirubin:	[ ]	Stool Culture		Deaminated gliadin IgG antibodies
	Child's Age: days hours	[ ]	Stool Ova & Parasites		Serum Immunoglobulins
	Clinician/Practitioner's tel. no.	[ ]	Other Swabs / Pus (specify source):		Serum Iron / TIBC
	Patient's 24 hr telephone no.				CRP
	Therapeutic Drug Monitoring:		**Specimen Collection**		
[ ]	Name of Drug #1		Time:		Date: YYYY-MMM-DD

[ ]	Name of Drug #2			
	Time Collected #1 hr. #2 hr.		**Fecal Occult Blood Test (FOBT) (check one)**		
	Time of Last Dose #1 hr. #2 hr.	[ ]	FOBT (non CCC)	[ ]	ColonCancerCheck FOBT (CCC) no other test can be order
	Time of Next Dose #1 hr. #2 hr.		**Laboratory Use Only**		

I hereby certify the tests ordered are not for registered in or out patients of a hospital.

X Santiago Fitzgerald
Clinician/Practitioner Signature

Date: 2021-May-24

817811 (2010/09) @Glenmore Specialist Centre, 2010 817811

Maple Health Clinic
760 Sherwood Ave
Ph: 472-336-3702
Fx: 472-336-3702

Referral Form

Referring Physician Information (Please Print) Fax: (624) 837-1465

Referring Physician Name: Dr. Santiago Fitzgerald
Phone Number: (624) 837-1465
Physician Isolde Krishnan
Referral Date: (dd/mm/yyyy) 2022-Nov-30

Patient Information (height and weight must be included in referral)

Surname: Alvarez
Given Name: Lucia Alvarez
Date of Birth (dd/mm/yyyy): 1957
Street Address (include apt #): 368 River Rd
City: Calgary
Postal Code: BQT 3T9
Home Telephone #: H: (624) 837-1465
Business Telephone #: C: (624) 837-1465 W: (791) 442-5889
Health Care (version code): 3062663187SX
Height (cm): 165
Weight (kg): 64
BMI: 23.5

Type of Referral (note: patient must be < 75 yr. of age and meet one of the following criteria)

[X] Colonoscopy	[ ] Gastroscopy
Reason for Request:	**Reason for Request:**
[ ] Screening –Fit Positive	[ ] Uninvestigated Dyspepsia
[ ] Screening –Positive Family Hx: (describe)_____	[ ] Reflux: (describe signs and symptoms along with attempte
[ ] Screening- Previous Polyps/CRC (provide reports if available)	
[ ] Symptomatic: describe_____	
Other: Recall Letter	[ ] Other:_____
Provide Dates of Previous Colonoscopy/Sigmoidoscopy:	**Provide Dates of Previous Gastroscopy:**
DD/MM/YYYY	DD/MM/YYYY	DD/MM/YYYY	DD/MM/YYYY	DD/MM/YYYY	DD/MM/YYYY

Patient Medical History

	Yes	No	List All Medications:
Angina/MI/Valvular Dx	[ ]	[X]	
Arrhythmia/Pacemaker/ICD	[ ]	[X]	
TIA/CVA	[ ]	[X]	
Sleep Apnea	[ ]	[X]	[ ] Coumadin [ ] Plavix [ ] Pradaxa [ ] Xarelto
Asthma/COPD	[ ]	[X]	**Allergies:**
Bleeding Disorder	[ ]	[X]	
Seizures/Epilepsy	[ ]	[X]	
Insulin Dependent Diabetes	[ ]	[X]	**Other Medical Conditions (Describe):**
Renal Impairment (Cr>150)	[ ]	[X]	
Chronic Pain Requiring Opioids	[ ]	[X]	

| Morbid Obesity (BMI >35) | [ ] | [X] | (Note: Pts must be ambulatory and able to walk 1 flight of stairs unassisted) |

Physician Signature: [signature: Santiago Fitzgerald]

Glenmore Specialist Centre
Glenmore Specialist Centre

Appointment
Date:
Time:
Scanner: 1.5T 3T

Request for MRI Consultation
Glenmore Specialist Centre 7
Tel. (823) 961-8915
Fax. (872) 561-3788

[ ] INPATIENT *must be faxed to: (840) 887-6168 [X] OUTPATIENT
Name: Lucia Alvarez
Gender: [ ] M [X] F
Address: 368 River Rd
City: Calgary Postal Code: BQT 3T9
Health Card #: 3062663187SX
Date of Birth (DD/MM/YYYY): 1957
Home #: (624) 837-1465 Cell #: (624) 837-1465
E-mail: fatima.pham29@fairlightmedicalcentre.ca
Please allow 2 weeks to receive notification of appointment

Area to be examined (be specific): MRE
Diagnostic Question/Clinical History:
Hx Crohn's disease, assess SB
PLEASE BOOK October 2025

Are you requesting a timed follow-up procedure (e.g., 6 month follow-up)? If yes, date requested (DD/MM/YYYY): 01/10/2025

Medical History Assessment for out-patient:
Dialysis [ ] YES [X] NO

Medical History Assessment for in-patient:
Dialysis [ ] YES [X] NO DD/MM/YYYY
Serum Creatinine: Date DD/MM/YY:

Patient Weight: 64 kg Patient Height: 165 cm

Ambulation:
[X] Walk [ ] Wheelchair [ ] Stretcher [ ] MEDICAL LIFT

Referring Physician (please print): Dr. Santiago Fitzgerald Quebec
Address: 368 River Rd Quebec U4U 5X1
Tel #: (624) 837-1465 Fax #: (624) 837-1465

Physician Signature: [signature: Santiago Fitzgerald]

Please list previous pertinent Imaging (MANDATORY)
External reports MUST be provided.
	What	Where
MRI		
CT		
Xray/Mammo		
Ultrasound		
Other		

If the following information changes between now and the appointment notify the Glenmore Specialist Centre.
Inaccurate information can result in appointment cancellation the day of exam.

Indicate if the patient has the following:	Yes	No		Yes	No
1. Previous reaction to contrast used for MRI? If yes, state the reaction type: -	[ ]	[X]	10. Coils, Filters, or
2. Claustrophobia? If yes, physician to prescribe sedation	[ ]	[X]	11. Neurostimulation System/Other Stimulation

| 3. Have you ever had metal go into your eye that was not removed by a doctor? If yes, attach orbit x-ray report | [ ] |
| | | | 13. IUD Type: | [ ] | [X] |
| 4. Any metallic fragment or foreign body? (shrapnel, bullets) | [ ] | [X] | 14. Spinal surgery? Level of sx: Date: | [
| 5. Currently pregnant? | [ ] | [X] | 15. Breast Tissue expander? Type: .. | [ ] | [X] |
| 6. Pacemaker/Defibrillator/ICD? | [ ] | [X] | 16. Drug infusion pump or glucose monitor? | [ ] | [X] |
| 7. Prosthetic Heart Valve, Cardiac Closure or Occluder Device? Type: | [ ] | [X] | 17. Any type of prosthesis? (eye, pe
| 8. Cerebral Aneurysm Clips? | [ ] | [X] | 18. Any other metallic, magnetic or electronic implant? If yes, explain: .. |
| 9. Cochlear (ear) implant? | [ ] | [X] | | | |

List all previous surgeries and implants.
[ ] No previous surgery
Dentures
C-section

For any implant, provide surgery date/hospital so we may confirm MRI compatibility. Provide OR record to expedite booking

Verification of screening will be standard care at appointment
Patient/SDM Signature: _____ Technologist Signature: _____ Date: _____

For Radiologist Use ONLY:
[ ] P1 [ ] P2 [ ] P3 [ ] P4 [ ] T _____
Protocol

[ ] Cancer Stage/Diagnosis [ ] Breast Cancer Screen [ ] Other

For Booking Use Only:
[ ] 20 [ ] 30 [ ] 45 [ ] 60 [ ] 75
[ ] GAD [ ] 1.5T
[ ] BUSCOPAN [ ] 3T
[ ] WEEKEND [ ] GA
[ ] WEEKDAY
[ ] BOOKING TIME

[X] Testing/Future

This task has been completed

Patient	Alvarez, Lucia	**Task Created By**	[REDACTED-STAFF-PROVIDER-NAME-OR-USERNAME]
Date Due	05/19/2021	**Priority**	Urgent
Assigned To	[REDACTED-STAFF-OR-PROVIDER-NAME]	**Completed**	2021-May-24 by [REDACTED-STAFF-OR-PROVIDER-NAME]
Notes	IBD labs pls also send off celiac testing (anti TTG and IgA level) pls book for gas/colon bendo 4-6 m

---

Patient: Mrs. Lucia Alvarez Appointment Date: 2021-May-19
Title: Chart Notes
Provider: Fitzgerald, Santiago Referred By: Fitzgerald, Santiago

Lucia Alvarez was seen today to follow up with regards to assessment and management of Crohn's.

Given the current pandemic of COVID-19, this patient visit was standard care over the phone in accordance with current pu

Past medical history:
Asthma
Hypothyroidism
Osteoporosis

Current medications: Atrovent, dessicated thyroid, prolia.

Allergies: None.

Social history: Non-smoker, rare EtoH, no illicit drugs.

Family history: Non-contributory.

History of presenting illness:

Labs: No recent labs.

Endoscopic evaluation: Colonoscopy in Apr 2012. Narrowed to TI without inflammatory changes. Biopsies from TI and ileocec

Imaging: No recent imaging.

Impression and Plan:

Thank you for involving me in the care of this patient. Please don't hesitate to contact me if you have any questions or

Patient: Mrs. Lucia Alvarez Appointment Date: 2021-May-19
Title: Chart Notes
Provider: Fitzgerald, Santiago Referred By: Fitzgerald, Santiago

Thank you for referring along Lucia for assessment and management of Crohn's disease.

Given the current pandemic of COVID-19, this patient visit was standard care over the phone in accordance with current pu

Past medical history:
1. Crohn's disease - Dx in 2001 when she presented with SBO and she was admitted to hospital and resolved with conservati
2. Possible Celiac disease - DQ2 positive but not homozygous.
3. Asthma

---

4. Hypothyroidism
5. Osteoporosis
6. Shoulder injuries with rotator cuff injury

Current medications: Thyroid replacement, Aleve daily, Prolia.

Allergies: None.

Social history: Non-smoker, rare EtoH, no illicit drugs. Retired - used to work at Sunnymede Family Practice 3 managing f

Family history: standard care

History of presenting illness: Feels well. Having 2 normal BM/day, no blood, no urgency, no tenesmus. She gets some post

Labs: No recent labs.

Endoscopic evaluation: Colonoscopy in Apr 2012. Narrowed to TI without inflammatory changes. Biopsies from TI and ileocec

Imaging: No recent imaging.

Impression and Plan: Lucia has longstanding CD with a fairly quiescent course. She has minimal symptoms and I will plan t

I look forward to seeing her at her gastroscopy and colonoscopy and will make further recommendations at that time.

I advised her to stop Aleve which can cause flares and GI inflammation in the context of Crohn's disease. She should use

IBD Plan:
1. Maintain up to date vaccinations with GP.
2. Avoid NSAIDs and anti-inflammatories which can cause flares of IBD, tylenol is safe.
3. Patient counselled on risks and side effects of current medical therapy.
4. Patient knows to contact me if they develop signs of a disease exacerbatlon including worsening abdominal pain, diarrh

Thank you for involving me in the care of this patient. Please don't hesitate to contact me if you have any questions or

---

Glenmore Specialist Centre

Please note address change:
760 Sherwood Ave

Telephone: (624) 837-1465
Fax: (624) 837-1465

[ ] Karim Holloway
[ ] Karim Holloway

[ ] Karim Holloway
[X] Karim Holloway

Dr. Santiago Fitzgerald Fax: (791) 442-5889

You have been scheduled for an Office Consultation.
Please ensure all instructions on this page are followed or your appointment may be cancelled.

1957
SM5806898

Patient: Lucia Alvarez
Date: 2021-Jan-20
Time: 4:25kr

THIS WILL BE A PHONE CONSULT

PLEASE COMPLETE THE ATTACHED LABWORK A FEW WEEKS PRIOR TO CONSULT.

THANK YOU!

Patient **must** bring:
* Current Health Card
* List of medications with dosages

Please call to confirm this appointment at Birchwood Care Clinic 5 regardless of the date, as soon as possible. A message

A $50 fee will be applied to any no-shows. This fee must be paid prior to a re-scheduled appointment.

Glenmore Specialist Centre

760 Sherwood Ave

Fax Cover Sheet

To: Dr. Santiago Fitzgerald
Phone: (624) 837-1465
Fax: (791) 442-5889

Date: 2021-May-19

Check out our new website at www.birchwoodcareclinic.ca

From: Dr. Santiago Fitzgerald
Phone: (624) 837-1465
Fax: (624) 837-1465

Number of pages including cover: 3

Re: Lucia Alvarez

Confidential: This communication is intended only for the individual or institution to which it is addressed and shou

---

Dr. Santiago Fitzgerald
Glenmore Specialist Centre
760 Sherwood Ave
Phone: (624) 837-1465 Fax: (624) 837-1465

2021-May-19

Dr. Santiago Fitzgerald
760 Sherwood Ave

Patient: Mrs. Lucia Alvarez
PHN: 9187508760-FM
Birthdate: 1957
Phone Number: (624) 837-1465, **Work:** (791) 442-5889 **Cell:** (624) 837-1465
Address: 760 Sherwood Ave

Provider Billing No.: 817811

Dear Dr. Fitzgerald,

Thank you for referring along Lucia for assessment and management of Crohn's disease.

Given the current pandemic of COVID-19, this patient visit was standard care over the phone in accordance with current pu

Past medical history:
1. Crohn's disease - Dx in 2001 when she presented with SBO and she was admitted to hospital and resolved with conservati
2. Possible Celiac disease - DQ2 positive but not homozygous.
3. Asthma
4. Hypothyroidism
5. Osteoporosis
6. Shoulder injuries with rotator cuff injury

Current medications: Thyroid replacement, Aleve daily, Prolia.

Allergies: None.

Social history: Non-smoker, rare EtoH, no illicit drugs. Retired - used to work at Sunnymede Family Practice 3 managi

Family history: standard care

History of presenting illness: Feels well. Having 2 normal BM/day, no blood, no urgency, no tenesmus. She gets some p

Labs: No recent labs.

Endoscopic evaluation: Colonoscopy in Apr 2012. Narrowed to TI without inflammatory changes. Biopsies from TI and ile

Patient: Lucia Alvarez PHN: 3062663187SX DOB: 1957

---

malignancy. Ileocecal valve, colonic mucosa, no diagnostic abnormality. Random colon, infiltration of lamina propria with mild chronic inflammatory infiltrate, no evidence of active colitis, granuloma, dysplasia or malignancy.

Imaging: No recent imaging.

Impression and Plan: Lucia has longstanding CD with a fairly quiescent course. She has minimal symptoms and I will plan to re-stage her disease with colonoscopy and MRE in addition to IBD labs. She does have the genetic susceptibility for Celiac disease so I will arrange celiac labs and a gastroscopy at the time of her colonoscopy.

I look forward to seeing her at her gastroscopy and colonoscopy and will make further recommendations at that time.

I advised her to stop Aleve which can cause flares and GI inflammation in the context of Crohn's disease. She should use Tylenol instead and GP could consider joint injections for her shoulders which would be preferable to long term NSAIDS in the context of her Crohn's.

IBD Plan:
1. Maintain up to date vaccinations with GP.
2. Avoid NSAIDs and anti-inflammatories which can cause flares of IBD, tylenol is safe.
3. Patient counselled on risks and side effects of current medical therapy.
4. Patient knows to contact me if they develop signs of a disease exacerbation including worsening abdominal pain, diarrhea, or blood in the stools.

Thank you for involving me in the care of this patient. Please don't hesitate to contact me if you have any questions or concerns.

Sincerely,

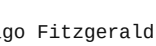

Santiago Fitzgerald
Electronically Reviewed to Expedite Delivery

Patient: Lucia Alvarez PHN: 3062663187SX DOB: 1957

Lab Results:
Generated On 2026-Apr-28

Patient	Alvarez, Lucia	HomePhone	496-380-7749	WorkPhone	
Health #	7811 918 750	Sex	F	Patient ID	817811
Age	68 years				
DOB	1957			Client Ref. #	-NP

Accession Id: SM5806898 (Final)
Ordered By: Santiago Fitzgerald
Collection Date: 2021-Mar-30
Service Date: 2021-Mar-30
Report Date: 2021-Apr-08 3:29 PM

Reported By: Glenmore Specialist Centre
Reviewed: 2021-Apr-08 by [REDACTED-STAFF-PROVIDER-NAME-OR-USERNAME]

Updated On: 2021-Apr-08 9:07 PM

	Results	Flags	RefRange	Test Loc
BIOCHEMISTRY				
HISTOCOMPATIBILITY TESTING	Reported under separate cover. This test was referred to the Laboratory Medicine<br

I61 - 760 Sherwood Ave

Glenmore Specialist Centre 7
Glenmore Specialist Centre 7
760 Sherwood Ave
Phone: (840) 887-6168
Fax: (840) 887-6168
ASHI #: SM5806898
Directors: Zander Wozniak
Alden Oliveira Santiago Fitzgerald
Valentina Paquette

Name: Alvarez, Lucia
MRN:
DOB: 1957
ABO Code:
Category: Celiac disease association
Physician: ,
Hospital: Glenmore Specialist Centre

Histocompatibility Laboratory Report

HLA Typing Results

Name/ID	Relation ABO	Haplo	A*	B*	Bw	C*	DRB1*	DRB345*	DQA1*	DQB1*	DPA1*	DPB1*	Test Date Sample
Alvarez, Lucia	Self							02 02	02 03(9)			[REDACTED-DATE] [REDACTED-DATE]

Local typing standard care by PCR-rSSO and/or PCR-SSP and/or NGS.
HLA typed elsewhere when indicated by: ‡
ABO testing not performed in the Glenmore Specialist Centre 7. All ABO results should be verified by ordering physician.

Comments
CELIAC DISEASE HLA ASSOCIATION SCREENING

BACKGROUND:
HLA DQ2 (as DQA1*05-DQB1*02) is present in approximately 95% of patients with biopsy proven celiac disease.
HLA DQ8 (as DQA1*03-DQB1*03:02(8)) is present in approximately 5% of patients with biopsy proven celiac disease.
Rarely patients with DQA1*02-DQB1*02 may present with celiac disease but in such situations, the haplotype is usually hom

INTERPRETATION OF TESTING:
The presence of one of these haplotypes is considered necessary but not sufficient for a diagnosis of celiac disease.
ABSENCE of all of these haplotypes RULES OUT celiac disease.
Additional diagnostic testing is necessary TO CONFIRM celiac disease if one of the above haplotypes is present.

PATIENT RESULT:
The DQA1*02-DQB1*02 celiac associated haplotype IS PRESENT in this patient. However, it is not homozygous.

Ordering Physician: Dr. Fitzgerald
Lab Accounting #: SM5806898

Printed Date: [REDACTED-DATE]

Glenmore Specialist Centre 7
Glenmore Specialist Centre 7
760 Sherwood Ave
Phone: (840) 887-6168
Fax: (840) 887-6168
ASHI #: SM5806898
Directors: Zander Wozniak
Alden Oliveira Santiago Fitzgerald
Valentina Paquette

Name: Alvarez, Lucia
MRN:
DOB: 1957
ABO Code:
Category: Celiac disease association
Physician: ,
Hospital: Glenmore Specialist Centre

Histocompatibility Laboratory Report

Created by: Rowan Whitfield
Date: [REDACTED-DATE]
Reviewed by: Karim Holloway, Co-Director
Date: [REDACTED-DATE]
Electronically Verified By: Karim Holloway, Co-Director
Date: [REDACTED-DATE]

Printed Date: [REDACTED-DATE]

Glenmore Specialist Centre
Laboratory Requisition
Requisitioning Clinician / Practitioner

Name
Dr. Santiago Fitzgerald
Address 760 Sherwood Ave

Clinician/Camille Cormier
CPSO / Registration No.

Check (▫) one:
[X] OHIP/Insured [ ] Third Party / Uninsured [ ] WSIB

Additional Clinical Information (e.g. diagnosis)
[ ] Fast for 12 hours [ ] Fast Overnight

[X] Copy to: Clinician/Practitioner
Last Name First Name
Santiago Fitzgerald
Address
760 Sherwood Ave

Laboratory Use Only

Clinician/Practitioner's Contact Number for Urgent Results: (624) 837-1465
Service Date: yyyy (blank) mm (blank) dd (blank)
Health Number: SM5806898
Version: (blank)
Sex: F
Date of Birth: 1957

Province: ON
Other Provincial Kian Poirier
Patient's Telephone Contact Number: (624) 837-1465
Patient's Last Name (as per OHIP Card): Alvarez
Patient's First & Middle Names (as per OHIP Card): Lucia Alvarez
Patient's Address (including Postal Code): 368 River Rd Calgary ON
BQT 3T9

Note: Separate requisitions are required for cytology, histology / pathology and tests performed by Public Health Laborat

x	Biochemistry	x	Hematology	x	Viral Hepatitis (check one only)
[ ]	Glucose [ ] Random [ ] Fasting	[ ]	CBC	[ ]	Acute Hepatitis
[ ]	HbA1C	[ ]	Prothrombin Time (INR)	[ ]	Chronic Hepatitis
[ ]	TSH		**Immunology**	[ ]	Immune Status / Previous Exposure
[ ]	Creatinine (eGFR)	[ ]	Pregnancy test (Urine)		Specify: [ ] Hepatitis A
[ ]	Uric Acid	[ ]	Mononucleosis Screen		[ ] Hepatitis B
[ ]	Sodium	[ ]	Rubella		[ ] Hepatitis C
[ ]	Potassium	[ ]	Prenatal: ABO, RhD, Antibody Screen (titre and ident. if positive)		or order individual hepa
[ ]	Chloride				**Prostate Specific Antigen (PSA)**
[ ]	CK	[ ]	Repeat Prenatal Antibodies	[ ]	Total PSA [ ] Free PSA
[ ]	ALT		**Microbiology ID & Sensitivities (if warranted)**		Specify one below:
[ ]	Alk. Phosphatase			[ ]	Insured - Meets OHIP eligibility criteria
[ ]	Bilirubin	[ ]	Cervical	[ ]	Uninsured - Screening: Patient responsible for payment
[ ]	Albumin	[ ]	Vaginal		**Vitamin D (25-Hydroxy)**
[ ]	Lipid Assessment (includes Cholesterol, HDL-C, Triglycerides, calculated LDL-C & Chol/HDL-C ratio; individual lip				
[ ]	Vitamin B12	[ ]	Chlamydia (specify source):		
[ ]	Ferritin	[ ]	GC (specify source):	[ ]	Uninsured – Patient responsible for payment
[ ]	Albumin / Creatinine Ratio, Urine	[ ]	Sputum		**Other Tests – one test per line**
[ ]	Urinalysis (Chemical)	[ ]	Throat	[ ]	HLA DQ2
[ ]	Neonatal Bilirubin:	[ ]	Wound (specify source):	[ ]	HLA DQ8
	Child's Age: days hours	[ ]	Urine		
	Clinician/Practitioner's tel. no.	[ ]	Stool Culture		
	Patient's 24 hr telephone no.	[ ]	Stool Ova & Parasites		
	Therapeutic Drug Monitoring:	[ ]	Other Swabs / Pus (specify source):		
	Name of Drug #1				
	Name of Drug #2		**Specimen Collection**		
[ ]	Time Collected #1 hr. #2 hr.		Time (blank) Date YYYY-MMM-DD		
[ ]	Time of Last Dose #1 hr. #2 hr.		**Fecal Occult Blood Test (FOBT) (check one)**		
[ ]	Time of Next Dose #1 hr. #2 hr.	[ ]	FOBT (non CCC) [ ] ColonCancerCheck		

I hereby certify the tests ordered are not for registered in or out patients of a hospital.

Laboratory Use Only

[signature]
Clinician/Practitioner Signature

2021-Feb-17
Date

817811 (2010/09) ©Glenmore Specialist Centre, 2010 817811

Glenmore Specialist Centre 7

Glenmore Specialist Centre 7
External Testing Request for Glenmore Specialist Centre
760 Sherwood Ave
(via Shipping Receiving Entrance on 760 Sherwood Ave)
(840) 887-6168 Fax (840) 887-6168

Patient Name: Lucia Alvarez
OHIP Number: SM5806898
DOB: 1957

Patient Information		
Draw Date:	Draw Time:	Draw ID:

Please check all that apply:

[ ] HLA A,B,Cw (Class I) Low Resolution[1] Typing
[ ] HLA DR,DQ (Class II) Low Resolution[1] Typing
[ ] Cytotoxic antibody screening (serum required)

[ ] HLA B27
[ ] HLA - A_____ Low Resolution[1] Typing
[ ] HLA - B_____ Low Resolution[1] Typing
[ ] HLA - Cw____ Low Resolution[1] Typing
[ ] HLA - DR_____ Low Resolution[1] Typing
[X] HLA - DQ 2 & 8 Low Resolution[1] Typing

Please indicate if this sample is for :
[ ] Transplant [ ] Kidney [ ] Bone Marrow
[X] Disease association
[ ] Pharmacogenetics

Transplant Hospital : _____
Tel #: (624) 837-1465
Lab Acc. # _____
Ordering Physician: Dr. Santiago Fitzgerald [signature]
Send Report to: Glenmore Specialist Centre Fax # (624) 837-1465

Additional Comments:_

HLA Typing Sample requirement: 10 ml ACD blood (ship same day between 4c and Room temp.)
Cytotoxic antibody screening requirement: 2ml serum or 7 ml clotted blood
*Serum can be frozen and shipped any time. Clotted blood: ship same day between 4c and Room temp.

* Samples are accepted Monday to Friday 9 am-5pm

[X] Patient Question

This task has been completed

Patient	Alvarez, Lucia	**Task Created By**	[REDACTED-STAFF-OR-PROVIDER-NAME]
Date Due	02/16/2021	**Priority**	Normal
Assigned To	[REDACTED-STAFF-OR-PROVIDER-NAME]	**Completed**	2021-Feb-17 by [REDACTED-STAFF-OR-PROVIDER-NAME]

Notes
Hello, this patient is Teodora Hansen' standard care and Lucia is wondering if she could have this standard care too befc
Please advise if okay to order this for her?

sure send her for celiac genetic testing - thx, vbbyxtg.
2021-Feb-17(hwqwemu): perfect, req mailed today

Glenmore Specialist Centre
Laboratory Requisition
Requisitioning Clinician / Practitioner

Name
Dr. Santiago Fitzgerald

Address 760 Sherwood Ave

Clinician/Camille Cormier
CPSO / Registration No.

Clinician/Practitioner's Contact Number for Urgent Results
(624) 837-1465

Service Date
yyyy: (blank) mm: (blank) dd: (blank)

Check (▫) one:
[X] OHIP/Insured [ ] Third Party / Uninsured [ ] WSIB

Health Number: SM5806898
Version: (blank)
Sex: F
Date of Birth: 1957

Province: ON
Other Provincial Kian Poirier
Patient's Telephone Contact Number: (624) 837-1465

Additional Clinical Information (e.g. diagnosis)
[ ] Fast for 12 hours [ ] Fast Overnight

Patient's Last Name (as per OHIP Card): Alvarez
Patient's First & Middle Names (as per OHIP Card): Lucia Alvarez

[X] Copy to: Clinician/Practitioner
Last Name: Fitzgerald
First Name: Santiago
Address: 760 Sherwood Ave

Patient's Address (including Postal Code):
368 River Rd Calgary ON
BQT 3T9

Note: Separate requisitions are required for cytology, histology / pathology and tests performed by Public Health Laborat

x	Biochemistry	x	Hematology	x	Viral Hepatitis (check one only)
[X]	Glucose [X] Random [ ] Fasting	[X]	CBC	[ ]	Acute Hepatitis
[ ]	HbA1C	[ ]	Prothrombin Time (INR)	[ ]	Chronic Hepatitis
[ ]	TSH		**Immunology**	[ ]	Immune Status / Previous Exposure
[X]	Creatinine (eGFR)	[ ]	Pregnancy test (Urine)		Specify: [ ] Hepatitis A [ ] Hepatitis B [ ] Hepatitis C
[ ]	Uric Acid	[ ]	Mononucleosis Screen		or order individual hepatitis tests in the "Other Tests" section belov
[X]	Sodium	[ ]	Rubella		**Prostate Specific Antigen (PSA)**
[X]	Potassium	[ ]	Prenatal: ABO, RhD, Antibody Screen (titre and ident. if positive)	[ ]	Total PSA [ ] Free F
[X]	Chloride	[ ]	Repeat Prenatal Antibodies		Specify one below:
[ ]	CK		**Microbiology ID & Sensitivities (if warranted)**	[ ]	Insured – Meets OHIP eligibility criteria
[X]	ALT	[ ]	Cervical	[ ]	Uninsured – Screening: Patient responsible for payment
[X]	Alk. Phosphatase	[ ]	Vaginal		**Vitamin D (25-Hydroxy)**
[X]	Bilirubin total and direct	[ ]	Vaginal / Rectal – Group B Strep	[ ]	Insured – Meets OHIP eligibility crit
[X]	Albumin	[ ]	Chlamydia (specify source):	[ ]	Uninsured – Patient responsible for payment
[ ]	Lipid Assessment (includes Cholesterol, HDL-C, Triglycerides, calculated LDL-C & Chol/HDL-C ratio; individual lip				
[ ]	Vitamin B12	[ ]	Sputum		AST - advised by hepatologist
[ ]	Ferritin	[ ]	Throat		CRP
[ ]	Albumin / Creatinine Ratio, Urine	[ ]	Wound (specify source):		Serum iron
[ ]	Urinalysis (Chemical)	[ ]	Urine		Iron saturation
[ ]	Neonatal Bilirubin:	[ ]	Stool Culture		
	Child's Age: days hours	[ ]	Stool Ova & Parasites		
	Clinician/Practitioner's tel. no.	[ ]	Other Swabs / Pus (specify source):		
	Patient's 24 hr telephone no.				
	Therapeutic Drug Monitoring:		**Specimen Collection**		
[ ]	Name of Drug #1		Time: (blank) Date: YYYY-MMM-DD		
[ ]	Name of Drug #2				
	Time Collected #1 hr. #2 hr.		**Fecal Occult Blood Test (FOBT) (check one)**		
	Time of Last Dose #1 hr. #2 hr.	[ ]	FOBT (non CCC)	[ ]	ColonCancerCheck FOBT (CCC) no other test can be order
	Time of Next Dose #1 hr. #2 hr.		**Laboratory Use Only**		

I hereby certify the tests ordered are not for registered in or out patients of a hospital.

X: [signature: Santiago Fitzgerald]
Clinician/Practitioner Signature

Date: 2021-Feb-16

817811 (2010/09) © Glenmore Specialist Centre, 2010
817811

Glenmore Specialist Centre
760 Sherwood Ave
Telephone: (624) 837-1465 Fax: (624) 837-1465

Karim Holloway Karim Holloway
Karim Holloway Karim Holloway
1957
SM5806898
Dear Dr. Santiago Fitzgerald,

Thank you for referring Lucia Alvarez to Glenmore Specialist Centre. All referrals are triaged upon receipt and booked accordingly.

Due to the volume of referrals received, we are currently scheduling based on the approximate times below. If there is a change in your patient’s medical condition while awaiting their appointment, please fax our office with an updated referral and pertinent document/tests.
Note: Due to Covid-19 concerns, appointment bookings may be delayed
Endoscopy Bookings:
Urgent Gastroscopy – within 8 weeks
Non-urgent Gastroscopy – 18-25 months
Positive FOBT/FIT – within 8 weeks
Urgent Symptomatic – within 3-7 months
Non-urgent Symptomatic – 18-25 months
Surveillance Colonoscopy, Pos. Fam. History – 25-30 months
Urgent Endoscopic Ultrasound (EUS) – 2-3 wks
Non-urgent EUS – 8-12 wks

Please note: Appropriate referrals can be redirected to Maple Health Clinic for earlier bookings, please use their referral form found at: www.westbrookmedicalassociatessouth.ca

Office Bookings:
Urgent GI Symptoms within – 3-6 months
Non-urgent GI Symptoms – 16-22 months
Transfers of Care/2nd Opinion – 20-26 months
Unstable Liver disease – within 3 months
Stable Liver disease – within 12 months
Note: The doctors also work out of the Glenmore Specialist Centre 7. Liver disease referrals are redirected from this office to that clinic; please contact their office at (840) 887-6168 for further inquiries.

We will contact your office, via fax, with an appointment time once it has been booked. At that time, we ask that you please contact your patient directly with the details of their appointment, and ensure your patient calls to confirm the appointment ASAP, as well as complete any required testing.

If you have any further questions, please do not hesitate to contact our office.

Thank you,

Glenmore Specialist Centre

[X] Office B+

This task has been completed

Patient: Alvarez, Lucia
Task Created By: [REDACTED-STAFF-PROVIDER-NAME-OR-USERNAME]
Date Due: 09/20/2020
Priority: Normal
Assigned To: [REDACTED-STAFF-OR-PROVIDER-NAME]
Completed: 2020-Oct-29 by [REDACTED-STAFF-OR-PROVIDER-NAME]
Notes: office 3-4 months with IBD bw before visit - thx, vbbyxtg.

2020-Oct-29(hwqwemu): booked Jan 20th, mailing to pt with req

---

Glenmore Specialist Centre
Check us out @ www.birchwoodcareclinic.ca

NEW PATIENT REFERRAL FORM
760 Sherwood Ave
Tel: 496-380-7749 Fax: 930-216-8546

[ ] Dr. Santiago Fitzgerald
[X] Dr. Santiago Fitzgerald
[ ] Any GI
[ ] Dr. Santiago Fitzgerald
[ ] Dr. Santiago Fitzgerald

Date: 09/15/2020

Patient's Name	Email	Referring Physician
Lucia Alvarez	fatima.pham29@fairlightmedicalcentre.ca	Santiago Fitzgerald

Patient's Address or Label	Gender	Physician Address or Stamp
368 River Rd Calgary BQT 3T9	F	#128 - Valentina Novak Quebec U4U 5X1

Health Card No. (Version Code)	DOB (mm/dd/yyyy)	Physician Billing No.
SM5806898	08/06/1957	SM5806898

Home Phone	Cell Phone	Work Phone	Physician Phone No.	Physician Fax No.
(624) 837-1465	(624) 837-1465	(705) ___ - ____	(624) 837-1465	(791) 442-5889

Reason for consult
Previous pt of Dr. Bianchi with hx of Crohn's. She would like to have ongoing follow up. Please see for further managemer
Patient consents to emails: [ ] Yes [ ] No

[X] Office
[ ] Gastroscopy
[ ] Colonoscopy
    [ ] Symptoms
    [ ] Family History of Colon Cancer
    [ ] FIT+
    [ ] Polyp Surveillance

****PLEASE attach reports of previous endoscopies (and attach all relevant work up including imaging, blood work, stool

****REFERRAL MUST INCLUDE:** Height 165 cm Weight 65.5 kg BMI 24.1

Medical history
[ ] Hx of adverse reaction to sedation/anesthesia
[ ] Diabetes Mellitus: Type I [ ] Type II [ ]
[ ] Sleep Apnea [ ] CPAP
[ ] Stroke / TIA
[ ] Angina / MI / Unstable angina last 6 months
[ ] Arrhythmia/Pacemaker/ICD
[ ] Prosthetic heart valve
[ ] Chronic Kidney Disease (Cr >150)
[ ] COPD / Emphysema
[ ] Bleeding Disorder
[ ] Chronic pain requiring opioids
[ ] Neurologic disease
[ ] Seizures / Epilepsy
[ ] Regular Cannabis Use
[ ] Alcohol Abuse
[ ] Other

List all medications (or attach complete list)	Other medical conditions (or attach complete list)
atrovenm dessicated thyroid prolia	asthma hypothyroidism osteoporosis

[ ] Plavix [ ] Brilinta [ ] Coumadin [ ] Xarelto [ ] Eliquis [ ] Pradaxa

Referring physician signature [signature]

Lab Results:
Generated On 2026-Apr-28

Patient	Alvarez, Lucia	**HomePhone**	496-380-7749	**WorkPhone**	
Health #	7811 918 750	**Sex**	F	**Patient ID**	817811
Age	68 years				
DOB	1957			**Client Ref. #**	-NP

***

Accession Id: SM5806898 (Partial)
Ordered By: Mateo Perron -0
Reported By: Glenmore Specialist Centre
Collection Date: 2015-Jul-23
Reviewed: 2015-Jul-26 by [REDACTED-PROVIDER-STAFF-NAME]
Service Date: 2015-Jul-23
Report Date: 2015-Jul-23 5:48 PM

CC: Roya Wickramasinghe
Updated On: 2015-Jul-23 8:28 PM

	Results	Flags	RefRange	Test Loc
MORPHOLOGY				
RBC (I)				
WBC (I)				
PLATELETS (I)				

***

Accession Id: SM5806898 (Final)
Ordered By: Mateo Perron -0
Reported By: Glenmore Specialist Centre
Collection Date: 2015-Jul-23
Reviewed: 2015-Jul-26 by [REDACTED-PROVIDER-STAFF-NAME]
Service Date: 2015-Jul-23
Report Date: 2015-Jul-23 6:49 PM

CC: Roya Wickramasinghe
Updated On: 2015-Jul-23 8:28 PM

	Results	Flags	RefRange	Test Loc
ROUTINE CHEMISTRY I				
GLUCOSE-RANDOM	7.0		3.6 - 7.7	mmol/L 10
CREATININE	69		45 - 97	umol/L
eGFR	85			
	An eGFR from 60-89 ml/min/1.73 m2 is consistent with mildly decreased kidney function. However, in the absence of oth			
SODIUM	140		135 - 147	mmol/L
POTASSIUM	4.9		3.5 - 5.5	mmol/L
CHLORIDE	105		100 - 110	mmol/L
TOTAL BILIRUBIN	8		< 22	umol/L
ASPARTATE TRANSAMINASE(AST)	21		7 - 31	U/L
ALANINE TRANSAMINASE (ALT)	22		10 - 44	U/L
ALKALINE PHOSPHATASE	74		45 - 129	U/L
GAMMA-GLUTAMYLTRANSFERASE	11	LO	12 - 43	U/L

760 Sherwood Ave (840) 887-6168

***

Accession Id: SM5806898 (Final)
Ordered By: Mateo Perron -0
Reported By: Glenmore Specialist Centre
Collection Date: 2015-Jul-23
Reviewed: 2015-Jul-26 by [REDACTED-PROVIDER-STAFF-NAME]
Service Date: 2015-Jul-23
Report Date: 2015-Jul-23 6:49 PM

CC: Roya Wickramasinghe

Updated On: 2015-Jul-23 8:28 PM

	Results	Flags	Ref Range		Test Loc
HEMATOLOGY IV					
VITAMIN B12	286		198 - 615	pmol/L	10

760 Sherwood Ave (840) 887-6168

***

Accession Id: SM5806898 (Final)
Ordered By: Mateo Perron -0
Reported By: Glenmore Specialist Centre
Collection Date: 2015-Jul-23
Reviewed: 2015-Jul-26 by [REDACTED-PROVIDER-STAFF-NAME]
Service Date: 2015-Jul-23
Report Date: 2015-Jul-23 6:49 PM

CC: Roya Wickramasinghe
Updated On: 2015-Jul-23 8:28 PM

	Results	Flags	Ref Range		Test Loc
CHEMISTRY					
FERRITIN	110		10 - 291	ug/L	10

760 Sherwood Ave (840) 887-6168

***

Accession Id: SM5806898 (Final)
Ordered By: Mateo Perron -0
Reported By: Glenmore Specialist Centre
Collection Date: 2015-Jul-23
Reviewed: 2015-Jul-26 by [REDACTED-PROVIDER-STAFF-NAME]
Service Date: 2015-Jul-23
Report Date: 2015-Jul-23 6:49 PM

CC: Roya Wickramasinghe
Updated On: 2015-Jul-23 8:28 PM

	Results	Flags	Ref Range		Test Loc
HEMATOLOGY I					
HEMOGLOBIN	129		120 - 160	g/L	10
HEMATOCRIT	0.378		0.350 - 0.450	L/L	
WHITE BLOOD CELL COUNT	6.1		4.0 - 11.0	x E9/L	
RED BLOOD CELL COUNT	4.41		4.00 - 5.10	x E12/L	
MCV	86		80 - 100	fL	
MCH	29.3		27.5 - 33.0	pg	
MCHC	341		305 - 360	g/L	
RDW	13.2		11.5 - 14.5	%	
PLATELET COUNT	331		150 - 400	x E9/L	

760 Sherwood Ave (840) 887-6168

***

Accession Id: SM5806898 (Final)
Ordered By: Mateo Perron -0
Reported By: Glenmore Specialist Centre
Collection Date: 2015-Jul-23
Reviewed: 2015-Jul-26 by [REDACTED-PROVIDER-STAFF-NAME]
Service Date: 2015-Jul-23
Report Date: 2015-Jul-23 6:49 PM

CC: Roya Wickramasinghe
Updated On: 2015-Jul-23 8:28 PM

	Results	Flags	Ref Range		Test Loc

HEMATOLOGY II					
ABSOLUTE: NEUTS	3.7		2.0 - 7.5	x E9/L	10
(A) LYMPH	1.5		1.0 - 3.5	x E9/L	
(A) MONO	0.6		0.2 - 1.0	x E9/L	
(A) EOS	0.2		0.0 - 0.5	x E9/L	
(A) BASO	0.0		0.0 - 0.2	x E9/L	
	Please note changes to PEDIATRIC CBC reference ranges as of Jun 14, 2015.				

760 Sherwood Ave (840) 887-6168

***

Accession Id: SM5806898 (Final)
Ordered By: Mateo Perron -0
Reported By: Glenmore Specialist Centre

Collection Date: 2015-Jul-23
Service Date: 2015-Jul-23
Report Date: 2015-Jul-23 6:49 PM
Reviewed: 2015-Jul-26 by [REDACTED-PROVIDER-STAFF-NAME]

CC: Roya Wickramasinghe
Updated On: 2015-Jul-23 8:28 PM

	Results	Flags	Ref Range		Test Loc
CHEMISTRY V					
C-REACTIVE PROTEIN	2		< 8	mg/L	10

760 Sherwood Ave (840) 887-6168

***

Accession Id: SM5806898 (Final)
Ordered By: Mateo Perron -0
Collection Date: 2015-Jul-23
Service Date: 2015-Jul-23
Report Date: 2015-Jul-23 6:49 PM
Reported By: Glenmore Specialist Centre
Reviewed: 2015-Jul-26 by [REDACTED-PROVIDER-STAFF-NAME]

CC: Roya Wickramasinghe
Updated On: 2015-Jul-23 8:28 PM

	Results	Flags	Ref Range		Test Loc
ROUTINE CHEMISTRY II					
ALBUMIN	41		35 - 50	g/L	10

760 Sherwood Ave (840) 887-6168

Patient: Mrs. Lucia Alvarez Appointment Date: 2015-Jun-16
Title: Note
Provider: Zimmerman, Santiago Referred By: Wickramasinghe, Roya
Thanks for asking me to see Lucia Alvarez with regards to her mild Crohn's disease symptoms.

This 57-year-old has a 15 year history of mild ileocolonic Crohn's disease. She was hospitalized in 2001with a partial sm

She looks healthy and well. Abdominal exam is benign and soft. Her examination otherwise was unremarkable.

Lucia Alvarez does have a mild case of Crohn's. I don't believe she is significantly symptomatic to warrant the risk of i

---

Glenmore Specialist Centre
Laboratory Requisition
Requisitioning Clinician / Practitioner

Laboratory Use Only

Name
Dr. Santiago Zimmerman
Address
760 Sherwood Ave

Clinician/Neha Desai
CPSO / Registration No.: (blank)

Clinician/Practitioner's Contact Number for Urgent Results
(624) 837-1465

Service Date: yyyy / mm / dd
(blank)

Health Number: 7811 918 750
Version: (blank)
Sex: F
Date of Birth: 1957

Check (▫) one:
[X] OHIP/Insured
[ ] Third Party / Uninsured
[ ] WSIB

Province: ON
Other Provincial Abel Moreau
Patient's Telephone Contact Number: (624) 837-1465

Additional Clinical Information (e.g. diagnosis)
[ ] Fast for 12 hours
[ ] Fast Overnight

Patient's Last Name (as per OHIP Card)
Alvarez
Patient's First & Middle Names (as per OHIP Card)
Lucia Alvarez(Lucia)

[X] Copy to: Clinician/Practitioner
Last Name: Wickramasinghe
First Name: Karim Holloway
Address: 760 Sherwood Ave

Patient's Address (including Postal Code)
760 Sherwood Ave

Note: Separate requisitions are required for cytology, histology / pathology and tests performed by Public Health Laborat

x	Biochemistry	x	Hematology	x	Viral Hepatitis (check one only)
[X]	Glucose [X] Random [ ] Fasting	[X]	CBC	[ ]	Acute Hepatitis
[ ]	HbA1C	[ ]	Prothrombin Time (INR)	[ ]	Chronic Hepatitis
[ ]	TSH		**Immunology**	[ ]	Immune Status / Previous Exposure
[X]	Creatinine (eGFR)	[ ]	Pregnancy test (Urine)		Specify: [ ] Hepatitis A
[ ]	Uric Acid	[ ]	Mononucleosis Screen		[ ] Hepatitis B
[X]	Sodium	[ ]	Rubella		[ ] Hepatitis C
[X]	Potassium	[ ]	Prenatal: ABO, RhD, Antibody Screen (titre and ident. if positive)		or order individual hepa
[X]	Chloride	[ ]	Repeat Prenatal Antibodies		**Prostate Specific Antigen (PSA)**
[ ]	CK		**Microbiology ID & Sensitivities (if warranted)**	[ ]	Total PSA [ ] Free PSA
[X]	ALT	[ ]	Cervical		Specify one below:
[ ]	Alk. Phosphatase	[ ]	Vaginal	[ ]	Insured - Meets OHIP eligibility criteria
[X]	Bilirubin	[ ]	Vaginal / Rectal - Group B Strep	[ ]	Uninsured - Screening: Patient responsible for payment
[X]	Albumin	[ ]	Chlamydia (specify source):		**Vitamin D (25-Hydroxy)**
[ ]	Lipid Assessment (includes Cholesterol, HDL-C, Triglycerides, calculated LDL-C & Chol/HDL-C ratio; individual lip				
[X]	Vitamin B12	[ ]	Sputum	[ ]	Uninsured - Patient responsible for payment
[X]	Ferritin	[ ]	Throat		**Other Tests - one test per line**
[ ]	Albumin / Creatinine Ratio, Urine	[ ]	Wound (specify source):		AST
[ ]	Urinalysis (Chemical)	[ ]	Urine		GGT
[ ]	Neonatal Bilirubin:	[ ]	Stool Culture		CRP
[ ]	Child's Age: days hours	[ ]	Stool Ova & Parasites		
[ ]	Clinician/Practitioner's tel. no.	[ ]	Other Swabs / Pus (specify source):		

[ ]	Patient's 24 hr telephone no.				
	Therapeutic Drug Monitoring:		**Specimen Collection**		
[ ]	Name of Drug #1		Time: (blank) Date: YYYY-MMM-DD		
[ ]	Name of Drug #2				
[ ]	Time Collected #1 hr. #2 hr.		**Fecal Occult Blood Test (FOBT) (check one)**		
[ ]	Time of Last Dose #1 hr. #2 hr.	[ ]	FOBT (non CCC)		
[ ]	Time of Next Dose #1 hr. #2 hr.	[ ]	ColonCancerCheck FOBT (CCC) no other test can be ordered on this form	

I hereby certify the tests ordered are not for registered in or out patients of a hospital.

X [signature]
Clinician/Practitioner Signature

2015-Jun-16
Date

Laboratory Use Only

817811 (2010/09) ©Glenmore Specialist Centre, 2010
817811

Dr. Santiago Zimmerman
Glenmore Specialist Centre
760 Sherwood Ave
Phone: (624) 837-1465 Fax: (624) 837-1465

2015-Jun-16

Dr. Wickramasinghe
760 Sherwood Ave

Patient: Mrs. Lucia Alvarez
PHN: 7811 918 750
Birthdate: 1957

Dear Dr. Wickramasinghe,

Known Allergies: None
Diagnosis: mild ileocolonic Crohn's disease
External Medications (Free Text): calcium, vitamin D
Medical/Surgical History: C-section x3, osteoporosis, tonsillectomy, migraines, laser treatment for partly detached r
Scheduled Appointments: None

Thanks for asking me to see Lucia Alvarez with regards to her mild Crohn's disease symptoms.

This 57-year-old has a 15 year history of mild ileocolonic Crohn's disease. She was hospitalized in 2001with a partial sm

She looks healthy and well. Abdominal exam is benign and soft. Her examination otherwise was unremarkable.

Lucia Alvarez does have a mild case of Crohn's. I don't believe she is significantly symptomatic to warrant the risk of i

Sincerely,

[signature]

Karim Holloway
Electronically Reviewed to Expedite Delivery

Patient: Lucia Alvarez PHN: 7811 918 750 DOB: 1957

[ ] Karim Holloway
[X] Karim Holloway
[ ] Karim Holloway
[ ] Santiago Fitzgerald, M.D., FRCP (C)

Gastroenterology

760 Sherwood Ave

Ph: 496-380-7749 Fax 930-216-8546

Dr. Karim Holloway Fax: (840) 887-6168

Office Appointment - Please notify your patient

Patient: Lucia Alvarez
1957 7811 918 750
760 Sherwood Ave
(624) 837-1465

Date: [REDACTED-DATE]

Time: 4:25kr

*   Inform patient to bring Health Card
*   List of Medications along with the dosage.

* 24 HOUR CANCELLATION NOTICE IS REQUIRED

OR $50.00 CHARGE APPLIES

[X] Office B+

This task has been completed

Patient: Alvarez, Lucia
Task Created By: [REDACTED-PROVIDER-STAFF-NAME]
Date Due: 02/18/2015
Priority: Urgent
Assigned To: vbbyxtg
Completed: 2015-Feb-23 by vbbyxtg
Notes: prev pt 2012

[REDACTED-DATE]- Booked [REDACTED-DATE] 4:25kr, faxed AS

Dr. Roya Wickramasinghe
760 Sherwood Ave
Phone: (840) 887-6168 Fax: (840) 887-6168

Feb 16, 2015

Dr. Bianchi
760 Sherwood Ave
Ph: (624) 837-1465 Fax: (624) 837-1465

Re: Lucia Alvarez
1957, 57, F, 7811 918 750
760 Sherwood Ave
Hm:(624) 837-1465, vbbyxtg:(840) 887-6168

Dear Dr. Bianchi,

Dear [REDACTED-PROVIDER-STAFF-GIVEN-NAME],

You met Lucia Alvarez on May 23, 2015 for a colonoscopy to reassess her Crohn's disease. You noted that she had a narrowe

She remains well but complains of having a completely unformed liquid stool at least once daily. More often if she eats c

She would like the opportunity to discuss with you whether this is significant and how this should best be managed.

Active Medications: ATIVAN 1 MG TABLET prn
Known Allergies: Drug - Allergy - None Known

Sincerely,

[REDACTED-PROVIDER-STAFF-NAME]

Roya Wickramasinghe, SM5806898
Electronically Reviewed to Expedite Delivery

Patient: Lucia Alvarez PHN: 7811 918 750 DOB: 1957

Enclosures
Feb 8, 2015 -
Feb 8, 2015 -
CARDIOVASCULAR RISK ASSESSMENT

Feb 8, 2015 - URINALYSIS: CHEMICAL
Feb 8, 2015 -
Feb 8, 2015 -
Feb 8, 2015 -
Feb 8, 2015 -
Feb 8, 2015 -

Patient: Lucia Alvarez PHN: 7811 918 750 DOB: 1957

Lab Results:
Generated On 2015-Feb-17

Patient	Alvarez, Lucia	**Home Phone**	496-380-7749	**Work Phone**	
Health #	7811 918 750	**Sex**	F	**Patient ID**	SM5806898
Age	57 years				
DOB	1957		**Client Ref. #**	-NP	

Accession Id: SM5806898 (Final)
Ordered By: Roya Wickramasinghe Reported By: Glenmore Specialist Centre
Collection Date: Feb 8, 2015 Reviewed: Feb 10, 2015 by [REDACTED-PROVIDER-STAFF-NAME]
Service Date: 08-Feb-2015 9:11 AM
Updated On: 08-Feb-2015 9:02 PM

Results	Flags	Ref Range		Test Loc
GLUCOSE-FASTING	5.1		3.6 - 6.0	mmol/L 08-Feb-2015 9:04 AM	10
CREATININE	71		45 - 97	umol/L 08-Feb-2015 9:04 AM	
eGFR	74			08-Feb-2015 9:04 AM	
	`eGFR 60-89 mL/min/1.73 m2 is seen in up to 45% of adults. Screening for Chronic Kidney Disease is recommended only f
	`For patients of African descent, the reported eGFR must be multiplied by a correction factor of 1.21.`				
SODIUM	141		135 - 147	mmol/L 08-Feb-2015 9:04 AM	
POTASSIUM	4.9		3.5 - 5.5	mmol/L 08-Feb-2015 9:04 AM	
ALANINE TRANSAMINASE (ALT)	17		10 - 44	U/L 08-Feb-2015 9:04 AM	

760 Sherwood Ave
(840) 887-6168

CARDIOVASCULAR RISK ASSESSMENT ------------------------------
HOURS FASTING | 13 | | Hours 08-Feb-2015 9:04 AM | 10
TRIGLYCERIDES | 1.73 | | mmol/L 08-Feb-2015 9:04 AM |
CHOLESTEROL | 6.04 | | mmol/L 08-Feb-2015 9:04 AM |
HDL CHOLESTEROL | 1.60 | | mmol/L 08-Feb-2015 9:04 AM |
CHOLESTEROL/HDL RATIO | 3.8 | | 08-Feb-2015 9:04 AM |
| | `Cholesterol/HDL-C is not included in the 2012 CCS guideline as a lipid initiation or treatment target but is recogni
LDL CHOLESTEROL(CALCULATED) | 3.65 | | mmol/L 08-Feb-2015 9:04 AM |
| | `Consider the non HDL-C value as an alternate lipid target if monitoring treatment in intermediate or high risk patie
NON HDL CHOLESTEROL | 4.44 | | mmol/L 08-Feb-2015 9:04 AM |
| | `Non HDL-Cholesterol is calculated from Total Cholesterol and HDL-c and is not affected by the fasting status of the
LIPID TARGET VALUES | | | 08-Feb-2015 9:04 AM |
| | `Lipid Target Values should be based on patient 10 year CVD risk assessment. 2012 revised` | | | |

Patient: Lucia Alvarez

---

treatment goals include:

High or Intermediate CVD risk

Primary LDL-C < or = 2.0 mmol/L OR
Tx target > or = 50% decrease in LDL-C

Alternate Non HDL-C < or = 2.6 mmol/L OR
Tx target ApoB < or = 0.8 g/L

Low CVD risk

Primary > or = 50% decrease in LDL-C
Tx target

760 Sherwood Ave
(840) 887-6168

URINALYSIS: CHEMICAL

COLLECTION DATE	Feb 8, 2015			08-Feb-2015 9:04 AM	10
COLLECTION TIME	4:25kr			08-Feb-2015 9:04 AM	
COLOUR	DARK YELLOW		NONE/YELLOW	08-Feb-2015 9:04 AM	
APPEARANCE	CLOUDY		CLEAR	08-Feb-2015 9:04 AM	
SPECIFIC GRAVITY	1.021		1.001 - 1.030	08-Feb-2015 9:04 AM	
pH	6.0		5.0 - 8.0	08-Feb-2015 9:04 AM	
PROTEIN	NEGATIVE		NEGATIVE (<0.3)	g/L 08-Feb-2015 9:04 AM	
GLUCOSE	NEGATIVE		NEGATIVE	mmol/L 08-Feb-2015 9:04 AM	
KETONE	NEGATIVE		NEGATIVE	mmol/L 08-Feb-2015 9:04 AM	
BLOOD	NEGATIVE		NEGATIVE	08-Feb-2015 9:04 AM	
NITRITE	NEGATIVE		NEGATIVE	08-Feb-2015 9:04 AM	
LEUCOYTE ESTERASE	SMALL	HI	NEGATIVE	08-Feb-2015 9:04 AM	

760 Sherwood Ave
(840) 887-6168

HEMOGLOBIN	136		120 - 160	g/L 08-Feb-2015 9:04 AM	10
HEMATOCRIT	0.39		0.35 - 0.45	L/L 08-Feb-2015 9:04 AM	
WHITE BLOOD CELL COUNT	6.5		4.0 - 11.0	x E9/L 08-Feb-2015 9:04 AM	
RED BLOOD CELL COUNT	4.57		4.00 - 5.10	x E12/L 08-Feb-2015 9:04 AM	
MCV	85.1		80.0 - 100.0	fL 08-Feb-2015 9:04 AM	
MCH	29.8		27.5 - 33.0	pg 08-Feb-2015 9:04 AM	
MCHC	350		305 - 360	g/L 08-Feb-2015 9:04 AM	
RDW	13.9		11.5 - 14.5	% 08-Feb-2015 9:04 AM	
PLATELET COUNT	310		150 - 400	x E9/L 08-Feb-2015 9:04 AM	

760 Sherwood Ave
(840) 887-6168

ABSOLUTE: NEUTS	4.1		2.0 - 7.5	x E9/L 08-Feb-2015 9:04 AM	10
(A) LYMPH	1.5		1.0 - 3.5	x E9/L 08-Feb-2015 9:04 AM	
(A) MONO	0.7		0.2 - 1.0	x E9/L 08-Feb-2015 9:04 AM	

Patient: Lucia Alvarez

(A) EOS	0.2		0.0 - 0.5	x E9/L 08-Feb-2015 9:04 AM	
(A) BASO	0.0		0.0 - 0.2	x E9/L 08-Feb-2015 9:04 AM	

760 Sherwood Ave
(840) 887-6168

| FERRITIN | 90 | | 10 - 291 | ug/L 08-Feb-2015 9:04 AM | 10 |

760 Sherwood Ave
(840) 887-6168

VITAMIN B12	224		198 - 615	pmol/L 08-Feb-2015 9:04 AM	10

760 Sherwood Ave
(840) 887-6168

THYROTROPIN (SENSITIVE TSH)	4.01	HI	0.30 - 4.00	mIU/L 08-Feb-2015 9:04 AM	10

760 Sherwood Ave
(840) 887-6168

***

Patient: Lucia Alvarez

[X] --

This task has been completed

Patient	Alvarez, Lucia	**Task Created By**	[REDACTED-PROVIDER-STAFF-NAME]
Date Due	11/22/2012	**Priority**	Normal
Assigned To	[REDACTED-PROVIDER-STAFF-NAME]	**Completed**	2012-Nov-27 by [REDACTED-PROVIDER-STAFF-NAME]
Notes	need the Bendo note from the [REDACTED-DATE] into EMR		
	Bendo note now in EMR		

Patient: Mrs. Lucia Alvarez Appointment Date: 2012-Nov-22
Title: Note
Provider: Zimmerman, Santiago Referred By: Wickramasinghe, Roya
I reviewed Lucia Alvarez in followup in the office today.

This 55-year-old has a mild case of ileocolonic Crohn's that dates back over 10 years. At one time she was on Pentasa. Sh

Given her age over 50 we recently did a screening colonoscopy. She had no polyps. She had only very mild changes suggesti

Lucia Alvarez has a very mild case of Crohn's disease. I've sent her for blood work with a copy to you. If there are any

---

Glenmore Specialist Centre

496 Aldergrove Ave Suite # 301
Quebec ON, Canada
U4U 5X1

Fax Cover Sheet

To: Dr. Karim Holloway
Phone: (840) 887-6168
Fax: (840) 887-6168

Date: 2012-Nov-22

From: Dr. Santiago Zimmerman
Phone: (624) 837-1465
Fax: (624) 837-1465

Number of pages including cover: 3

Re: Lucia Alvarez (Lucia) Alvarez

***

Confidential: This communication is intended only for the individual or institution to which it is addressed and shou

---

Dr. Santiago Zimmerman
Glenmore Specialist Centre
760 Sherwood Ave
Phone: (624) 837-1465 Fax: (624) 837-1465

2012-Nov-22

Dr. Wickramasinghe
760 Sherwood Ave

Patient: Mrs. Lucia Alvarez
PHN: 7811 918 750
Birthdate: 1957

Dear Dr. Wickramasinghe,

Known Allergies: None
Diagnosis: mild ileocolonic Crohn's disease
External Medications (Free Text): calcium, vitamin D
Medical/Surgical History: C-section x3, osteoporosis
Scheduled Appointments: None

I reviewed Lucia Alvarez in followup in the office today.

This 55-year-old has a mild case of ileocolonic Crohn's that dates back over 10 years. At one time she was on Pentasa. She been on no medications now for many years and is not having any symptoms suggesting active Crohn's disease. Her Harvey Bradshaw index is zero. She feels well, no abdominal pains or diarrhea, no extracolonic manifestations of inflammatory bowel disease and I don't feel a mass on examination.

Given her age over 50 we recently did a screening colonoscopy. She had no polyps. She had only very mild changes suggesting Crohn's disease and biopsies showed only mild disease activity. She is otherwise well. Her only medications are her osteoporosis meds. She will be speaking to you about getting a referral to a new endocrinologist.

Lucia Alvarez has a very mild case of Crohn's disease. I've sent her for blood work with a copy to you. If there are any concerns I'hwqwemu be in touch. I don't suspect her Crohn's will become a problem. If so then I will be happy to reassess her.

Sincerely,

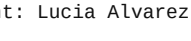

Patient: Lucia Alvarez PHN: 7811 918 750 DOB: 1957

Karim Holloway
Electronically Reviewed to Expedite Delivery

Patient: Lucia Alvarez PHN: 7811 918 750 DOB: 1957

Santiago Zimmerman
Glenmore Specialist Centre
301–496 Aldergrove Ave
Quebec, Ontario
U4U 5X1

FILE COPY

Telephone: (624) 837-1465
Fax: (624) 837-1465

PROCEDURE NOTE

PATIENT: Alvarez, Lucia
DATE: May 23, 2012
DOB: Sep 5, 1957

PRE PROCEDURE DIAGNOSES: Reassessment of Crohn's and screening colonoscopy.

POST PROCEDURE DIAGNOSES: Narrowed TI without inflammatory changes.
Biopsies from TI and ileocecal valve taken, extremely
mild patchy colitis. Random biopsies taken, small
hemorrhoids.

OPERATIVE PROCEDURE: Colonoscopy.

ENDOSCOPIST: Dr. Santiago Zimmerman

ANESTHETIST: Dr. Santiago Fitzgerald

CLINICAL NOTE:

Dear Dr. Wickramasinghe:

This 54-year-old was recently reassessed with regards to her Crohn's disease. She had been hospitalized in 2001 with partial bowel obstruction from terminal ileal Crohn's disease. She has had erythema nodosum in the setting of subsequent flares, but I believe has only used Pentasa sporadically in the past. She does have osteoporosis. Recent blood work was normal. Clinically, she is in remission with Harvey-Bradshaw index of 0 and her symptoms are more suggestive of functional bowel disorder. We undertook colonoscopic exam today.

PROCEDURE:

Sedation was provided by anesthesia. Following normal digital rectal exam, anoscopy revealed small internal hemorrhoids. The pediatric Olympus variable video colonoscope was introduced and maneuvered in the usual fashion over to the cecum. We were able to get into the distal terminal ileum, but could not move further than that suggesting that she has a bit of stricturing process there, but it was not obviously scarred or inflamed, nor ulcerated. I did biopsies from the terminal ileum and at the anastomosis. There are some tiny ulcers in the cecum and I noted scattered loss of vascularity during the gradual withdrawal of the scope, but no significant Crohn's colitis present. Random colon biopsies taken and again the small hemorrhoids noted. She tolerated the procedure well and was returned to recovery in satisfactory condition.

.../2

Alvarez, Lucia

SUMMARY:

Lucia Alvarez's Crohn's is in remission clinically and endoscopically. I will be in touch if there are any concerns from

Sincerely,

[REDACTED-PROVIDER-NAME] Santiago Zimmerman

Dictated but not read.

vbbyxtg/XG

cc: Dr. Roya Wickramasinghe

Glenmore Specialist Centre 6
Medical Laboratory Services
760 Sherwood Ave

Histopathology

RECEIVED [REDACTED-DATE]

HISTOPATHOLOGY REPORT

PATH NO.: LG32777823-13507	PATIENT: Lucia Alvarez	hwqwemu: 7811 918 750
COLLECTED: 05/23/2012	DOB: 09/05/1957 (54) SEX: F	INTRLAB: LG32777823-13507
RECEIVED: 05/24/2012	PHYSICIAN: Santiago Zimmerman	(899) 593-3646
REPORTED: 06/03/2012	LOCATION: Glenmore Specialist Centre 760 Sherwood Ave	

Copies sent to: Roya Wickramasinghe

CLINICAL DATA: A. TERMINAL ILEUM. BIOPSY. HISTORY CROHN'S.
B. ILEOCECAL VALVE. BIOPSY. HISTORY CROHN'S.
C. RANDOM COLON. BIOPSY. HISTORY CROHN'S.
/vbbyxtg

DIAGNOSIS: A - TERMINAL ILEUM:
SMALL BOWEL MUCOSA, TERMINAL ILEAL: MILD ACUTE AND CHRONIC ILEITIS
NO EVIDENCE OF GRANULOMA, DYSPLASIA OR MALIGNANCY
B - ILEOCECAL VALVE:
COLONIC MUCOSA: NO DIAGNOSTIC ABNORMALITY
C - RANDOM COLON:
INFILTRATION OF LAMINA PROPRIA WITH MILD CHRONIC INFLAMMATORY INFILTRATE
NO EVIDENCE OF ACTIVE COLITIS, GRANULOMA, DYSPLASIA OR MALIGNANCY

SPECIMEN: A
SPECIMEN SITE: TERMINAL ILEUM

GROSS DESCRIPTION:
Specimen container labeled A. In fixative, 2 tissue fragments 0.4 x 0.2 x 0.1 cm. Submitted in toto. Block(s) / fragment(
/XG

SPECIMEN: B
SPECIMEN SITE: ILEOCECAL VALVE
GROSS DESCRIPTION:

[image]

RECEIVED [illegible]

Santiago Zimmerman
Glenmore Specialist Centre LL1
760 Sherwood Ave

Electronically Reported By:
Keziah Calloway

Glenmore Specialist Centre 6
Medical Laboratory Services
760 Sherwood Ave

Histopathology

HISTOPATHOLOGY REPORT

PATH NO.: LG32777823-13507	PATIENT: Lucia Alvarez	hwqwemu: 7811 918 750
COLLECTED: 05/23/2012	DOB: 09/05/1957 (54) SEX: F	INTRLAB: LG32777823-13507
RECEIVED: 05/24/2012	PHYSICIAN: Santiago Zimmerman	(899) 593-3646
REPORTED: 06/03/2012	LOCATION: Glenmore Specialist Centre 760 Sherwood Ave	

Copies sent to: Roya Wickramasinghe

Specimen container labeled B. In fixative, 3 tissue fragments 0.4 x 0.3 x 0.1 cm. Submitted in toto. Block(s) /
fragment(s): B/2+fragment.
/XG

SPECIMEN: C

SPECIMEN SITE: RANDOM COLON

GROSS DESCRIPTION:
Specimen container labeled C. In fixative, multiple fragments, in aggregate 0.5 x 0.5 x 0.1 cm. Submitted in toto. Block(s) / fragment(s): C/3+fragments.
/XG

[REDACTED-STAFF-USERNAME-OR-NAME]

Santiago Zimmerman
Glenmore Specialist Centre LL1
760 Sherwood Ave

Electronically Reported By:
Keziah Calloway

FILE COPY

[REDACTED-PROVIDER-NAME] Santiago Zimmerman
Glenmore Specialist Centre
Manitoba
Quebec, Ontario
U4U 5X1
Telephone: (624) 837-1465 Fax: (624) 837-1465

Jan 8, 2012

Dr. Karim Holloway
Birchwood Care Clinic 6
760 Sherwood Ave
Fax: 812-420-9479

[image: FAXED JAN 19, 2012]

RE: Alvarez, Lucia
DOB: Sep 5, 1957

Dear Dr. Wickramasinghe:

Thanks for asking me to reassess this 54-year-old with regards to her Crohn's disease and the possible need for followup

I met her back in August 2002. As you know she had been hospitalized a year earlier with a partial bowel obstruction. CT

She has had no new medical issues since I saw her other than she has been recently diagnosed with osteoporosis and starte

Lucia hasn't been on her Pentasa for many years and clinically is doing well. She's had no obstructive symptoms. Her Harv

---

In summary Lucia Alvarez's terminal ileal Crohn's remains in remission clinically on no medications. There is no need for

Sincerely,

[REDACTED-PROVIDER-NAME] Santiago Zimmerman

vbbyxtg/adw

Voice recognition technology utilized, which may result in errors not recognized by proof reading.

Karim Holloway
Gastroenterology
Manitoba
Quebec, Ontario
Nova Scotia

FILE COPY

Telephone: (624) 837-1465
Fax: (624) 837-1465

Sep 17, 2002

Dr. Roya Wickramasinghe
Birchwood Care Clinic 6
760 Sherwood Ave

RE: Alvarez, Lucia
DOB: Sep 5, 1957

Dear Dr. Wickramasinghe:

Thank you for asking me to see this 44-year-old lady with regards to her Crohn's Disease.

Past history includes three C-sections, a history of migraines, tonsillectomy, and laser treatment for partly detached re

She was hospitalized last [REDACTED-DATE] with a partial bowel obstruction and was treated conservatively. The CT Scan sh

On examination, she looks quite well. Her vitals are fine. Head, neck and CNS are grossly normal. Chest is clear. Heart s

---

Lucia Alvarez

In summary, Lucia Alvarez has terminal ileal Crohn's Disease, which is quite quiescent on her Pentasa. She will continue

Sincerely,

Karim Holloway

vbbyxtg/pw

Fairlight Medical Centre 2
Sunnymede Family Practice 4

Ord: Wickramasinghe, Roya ;
Fam: Wickramasinghe, Roya
Att: Wickramasinghe, Roya
Oth:

Alvarez, Lucia
Ontario
Quebec, ON
Quebec
496-380-7749

REQ#: 98-9144732
CGEB#: EY502522/33
UNIT#: 817811
DOB: 05/09/1957
AGE: 44
LOCN: V.GCAU

Date of OR:

DATE OF EXAM: 22/11/2001;
JDSR
CT ABDOMEN WITH CONTRAST; CT PELVIS WITH CONTRAST; Fairlight Medical Centre 2;

Axial sections have been obtained through the abdomen and pelvis following oral and intravenous contrast enhancement.

This is compared to a study of [REDACTED-DATE].

There continues to be considerable thickening of the terminal ileum. The amount of free fluid has decreased and there is

The study is otherwise normal.

OPINION

The findings continue to be consistent with inflammatory bowel disease affecting the distal 20 cm of small bowel.

Santiago Fitzgerald M.D.
AUTHENTICATED BY ELECTRONIC MEANS
/MRL
25/11/2001
Rep. # 3143-1643

cc: Wickramasinghe, Roya;

NOTE: This document contains confidential information belonging to the sender which is legally privileged. The informatic

*

760 Sherwood Ave TELEPHONE (624) 837-1465

Patient: Mrs. Lucia Alvarez

To:
From: CjrkL
Written On: 2022-Dec-01
Subject: Cover Sheet
Note: COLON

To:
From: CjrkL
Written On: 2022-Dec-01
Subject: Cover Sheet
Note: COLON

To:
From: CjrkL
Written On: 2022-Dec-01
Subject: Cover Sheet
Note: colon

To:
From: [REDACTED-STAFF-OR-PROVIDER-NAME]
Written On: 2022-Apr-13
Subject: Cover Sheet
Note: Hello, please amend this booking to list Dr. Fitzgerald as the ordering - it was ordered
under Dr. Fitzgerald in error. Want to make sure he gets the report.. :)
Thankyou!

To:
From: [REDACTED-STAFF-PROVIDER-NAME-OR-USERNAME]
Written On: 2021-Dec-17
Subject: Cover Sheet
Note: old CT report from 2001 - thx, vbbyxtg.

To:
From: [REDACTED-STAFF-PROVIDER-NAME-OR-USERNAME]
Written On: 2021-Dec-16
Subject: Cover Sheet
Note: URGENT

To:
From: [REDACTED-STAFF-PROVIDER-NAME-OR-USERNAME]
Written On: 2021-Dec-15
Subject: Cover Sheet
Note: non urgent second opinion IBD

Patient: Lucia Alvarez PHN: 3062663187SX DOB: 1957